

Pleural effusion with pleural thickening in a patient exposed to zinc chromate paints: A rare case report

Abstract

A 35-year-old male painter presented with left sided pleuritic chest pain and exertional dyspnea. A chest radiograph revealed left pleural effusion with pleural thickening. This condition is suspected to be caused by chronic exposure to zinc dichromate and history of exposure was > 13 years. Pleural effusion with pleural thickening can be both benign and malignant. Biopsy remains gold standard investigation for exclusion. Pleural fluid cytology and pleural biopsy revealed lymphocytic pleural effusion with few macrophages in proteinaceous fluid background and negative for malignant cells, which was suggestive of benign chronic inflammatory reaction and exclude any malignant changes. Pleural fluid drained and symptomatic treatment provided and patient counseled. Further follow-up needed to diagnosis early malignant changes.

Key words: Occupational lung disease, pleural effusion, pleural thickening, zinc dichromate chronic exposure

**Saibal Moitra,
Sukanta Sen¹,
Ankur Datta¹,
Nandita Basu²**

Department of Respiratory
Medicine, Charnock Hospital
and Research Centre Pvt. Ltd.,
Kolkata, Departments of ¹Clinical
and Experimental Pharmacology
and ²Pathology, Calcutta School of
Tropical Medicine, Kolkata,
West Bengal, India

Address for the Correspondence:

Dr. Sukanta Sen,
Department of Clinical and
Experimental Pharmacology,
School of Tropical Medicine, 108
C.R. Avenue, Kolkata - 700 073,
West Bengal, India.
E-mail: drsukant@gmail.com

Access this article online

Website: www.ijmedph.org

DOI: 10.4103/2230-8598.153838

Quick response code:



INTRODUCTION

Occupational lung diseases are a group of illnesses that are caused by either repeated, extended exposure or a single, severe exposure to irritating or toxic substances that leads to acute or chronic respiratory ailments.^[1]

Pleural thickening is a lung disease that describes a scarring, calcification, and/or thickening of the pleura (the lining surrounding the lungs) often as a consequence of the inhalation of asbestos, other organic and inorganic dusts into the lungs. It may be focal or diffuse. Diffuse pleural thickening is defined as thickening of pleura (>5 mm) with combined area of involvement >25% of the chest wall if bilateral and 50% involvement if unilateral.^[2] Apical pleural thickening is a normal aging process, but if the thickening is >2 cm, it requires further work-up and follow-up. On imaging, benign pleural thickening appears as a diffuse involvement of pleura. Pleural thickening >5 cm in width, 8 cm in cranio-caudal extent, and 3 mm in thickness usually suggests a benign etiology.^[3] Causes of diffuse pleural thickening are empyema, asbestosis, hemothorax, pulmonary fibrosis, irradiation, previous surgery, trauma, and drugs. In developing countries, tuberculosis (TB) is an important cause of pleural thickening.^[4]

The asbestos fibers or dichromate particles inhaled on a regular basis during occupational exposure, which lodged in the pleura and may cause chronic inflammatory changes. These chronic inflammatory reactions may lead to fibrosis, scarring, calcification and thickening of the pleura.^[5] When the pleura thicken, it reduces the elasticity of the lungs and contributes to a reduced lung function causing symptoms in sufferers such as shortness of breath, and chest pains. Pleural thickening is a benign condition but it should be diagnosed, treated, and monitored regularly, and chronic exposure of the offending agent(s) must be avoided; otherwise there is potential for malignant changes and further complications.^[6]

Zinc chromate ($ZnCrO_4$), is a chemical compound containing the chromate anion, appearing as odorless yellow solid powder. It is used widely, for example, in the metal and printing industries and paints. Occupational exposure to $ZnCrO_4$ can cause tissue ulceration and cancer. Experience of spray

painters exposed to chromium compounds, ZnCrO₄ primer paints, revealed a significant excess of cancer, primarily of the respiratory tract.^[7] Herein, we report the case of a 33-year-old man with pleural thickening with pleural effusion, clinically mimicking benign lesion.

CASE REPORT

A 33-year-old, smoker, male painter by occupation presented with long standing dull aching left sided chest pain, rhinitis, and exertional dyspnea for past 3 months. Other associated symptoms were generalized weakness and dry cough off and on. There was no history of fever, weight loss, hemoptysis or contact with TB patient. Our patient occupation was painting mainly interior painting, spray painting and primer paintings of wooden blocks and metals for >13 years. There was no past history of pulmonary TB and chronic drug exposure. There was no evidence of digital clubbing or lymphadenopathy. Examination was unremarkable except loss of volume, dull note and decreased auscultatory sounds over entire left hemithorax. Chest radiograph [Figure 1] shows normal hilar and the cardiac and homogeneous opacification of left middle and lower zones suggestive of left sided pleural thickening. Left costophrenic angle and left dome of the diaphragm are obliterated while right one is clear suggestive of left sided pleural effusion. Ultrasonography (USG) of whole abdomen shows no obvious space occupying lesion in the abdomen and pelvis, no lymphadenopathy, but considerable of fluid noted in left pleural space. To exclude pulmonary TB or malignancy, sputum for acid fast bacilli and pleural aspiration was done. Ziehl-Neelsen stain revealed many pus cells, few epithelial cells, necrotic debris and cocci in clusters and in long chains, but no acid fast bacilli detected. Pleural fluid analysis revealed an exudates with increased total cell count 2650/cmm (normal <1000); mostly lymphocytes (98%), normal glucose, raised protein 5.5 g/dl (normal up to 3 g/dl), raised lactate dehydrogenase 330 U/L (normal <200), normal adenosine deaminase (ADA) level; negative for malignant cells and red blood cell (RBC). All special stains for acid fast bacilli, Grocott-Gomori methenamine-silver, periodic acid-Schiff, and mucicarmine failed to demonstrate any organism. Mantoux test was negative. Complete hemogram was within normal limits except decreased hemoglobin 10.0 g% (normal 13-18 g%). Erythrocyte sedimentation rate was 30 mm/1st h. H and E and Papanicolaou (PAP) stained smears showed only plenty lymphocytes and no malignant cell. Pleural fluid for cytology showed presence of numerous lymphocytes and few macrophages in proteinaceous fluid background and negative for malignant cells suggestive of benign chronic inflammatory reaction. PAP stain and cell block preparation [Figure 2] showed inflammatory cells with a predominance of lymphocytes, RBCs, a few mesothelial cells, histiocytes and negative for malignant cells. Suspecting a primitive pleural tumor (a differential diagnosis of a solitary fibrous tumor and localized mesothelioma) or primary lung cancer lesion invading the pleura, even considering the anatomical localization of the pleural lesion [Figure 1], we attempted to perform USG guided pleural biopsy in order to obtain a tissue specimen to diagnose the disease. After obtaining the patient's consent USG, guided pleural biopsy

was performed. Biopsy [Figure 3] showed chronic inflammatory cells and negative for malignancy or granulomatous inflammation.

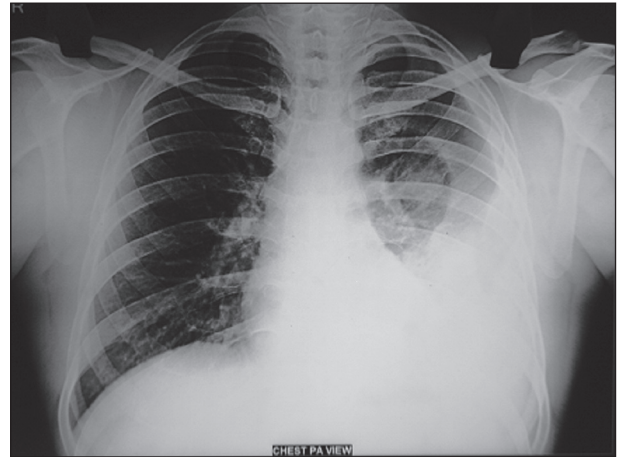


Figure 1: Chest radiograph shows inhomogeneous opacification of left lower and middle zone and obliterated left costophrenic angle and left dome of the diaphragm is suggestive of left sided pleural thickening with pleural effusion

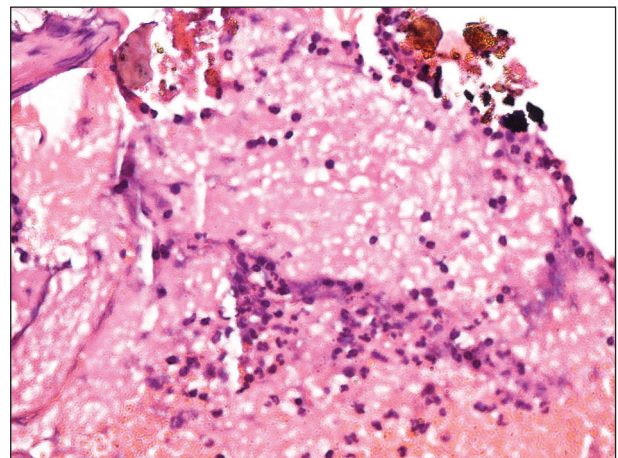


Figure 2: Papanicolaou stain and cell block preparation shows inflammatory cells with a predominance of lymphocytes, red blood cells, a few mesothelial cells, histiocytes and negative for malignant cells

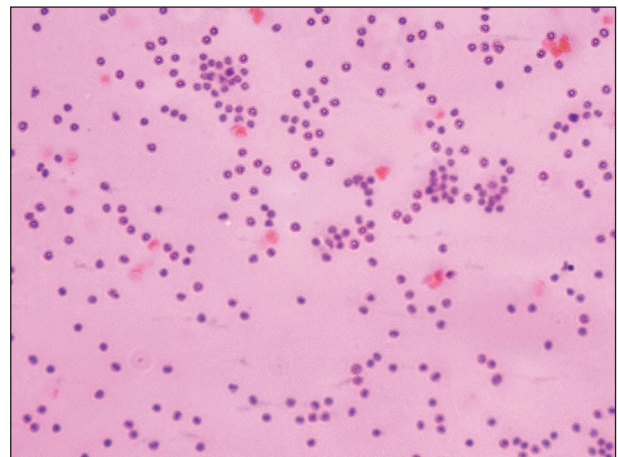


Figure 3: Biopsy shows chronic inflammatory cells and negative for malignancy or granulomatous inflammation

Further, immunohistochemical markers were not done to establish the diagnosis. Computerized tomography of the thorax reveals a left sided diffuse pleural thickening. No hilar or mediastinal lymphadenopathy was seen. Blood sugar and kidney function test was within normal limits. Patient had restrictive abnormalities on lung function testing with mean total lung capacity 74% and mean residual volume 73% of predicted. Radiographic appearances correlated with lung function impairment or symptom progression.

Pleural tap was done for symptomatic relief. Patient was put on antibiotic (tablet moxifloxacin 400 mg orally every 24 h for 7 days, tablet doxycycline 200 mg of doxycycline on day 1, then 100 mg/day for 2 weeks, mometasone nasal spray and montelukast 10 mg once at night. Inhaled bronchodilator was given for a short period. Patient was asked to regular follow-up. Repeat X-ray chest (anteroposterior view) was done after 1-month and found to be no pleural effusion though there was pleural thickening.

DISCUSSION

Zinc dichromate chronic exposure related pleural thickening is a rare disease.^[7] Diagnosis of the present case was based on a history of zinc dichromate chronic exposure, chest radiographic pleural thickening with blunting of costophrenic angle, and exclusion of other likely causes of pleural disease. Common microscopic findings of the present case are characterized as chronic inflammatory cells and negative for malignancy or granulomatous inflammation. Tumor markers and autoimmune screen were negative, and there were no clinical features of trauma or infection, with normal inflammatory markers.

Animal studies and *in vitro* experiments showed that nanoparticles could result in lung damage and other toxicity. Papageorgiou *et al.*^[8] showed that cobalt-chromium alloy nanoparticles release free radicals and induced DNA damage, aneuploidy and cytotoxicity in human fibroblasts in tissue culture.

Pleural fluid analysis revealed no tubercular and other bacterial infections. Several studies have explored that a pleural fluid ADA level >70 IU/L is highly suggestive of TB while a level <40 IU/L virtually excludes the diagnosis.^[9] Other inorganics nanoparticles like silicon nanoparticles, titanium dioxide, nanoscale silver cluster, and polyacrylate, widely used as an adhesive in the building, print and decoration fields, has often been regarded as low toxicity.^[10]

An abdomen/pelvis USG showed no evidence of malignancy or thromboemboli. On clinical and radiologic evaluations, dichromate chronic exposure related pleural thickening also can be masqued as interstitial or bronchopneumonia as well as malignancies of lung or pleura. Therefore, it is necessary to have histological confirmation and to recognize each microscopic subclass for the exclusions of neoplasms or the other inflammatory disorders because it can be a critical point for the treatment plan.

Clinico-radiological differential diagnoses of pleural thickening with pleural effusion include some nonmalignant and malignant

diseases, such as pulmonary TB, malignant mesothelioma, pseudomesotheliomatous adenocarcinoma and epithelioid hemangioendothelioma with pleural involvement. Malignant mesothelioma has a typical radiologic pattern showing diffuse infiltrative pleural thickening and frequent pleural effusion. Histopathological examination of the biopsy specimen shows [Figure 3] chronic inflammatory cells, but no tumor cells characteristically arranged in papillary fronds, sheets and glandular structures with hyperchromatic nuclei, which exclude adenocarcinoma or epithelioid variety of mesothelioma.^[11]

Understanding its natural history should help clinicians diagnose and manage ZnCrO₄-induced benign pleural thickening. Therefore, it is important for pathologists to consider the possibility and to rule out the other benign or malignant diseases for the appropriate treatments. We used several noninvasive and invasive methods for diagnosis. Noninvasive methods included chest X-ray, abdominal ultrasound, sputum analysis and invasive methods included puncture of pleural effusions, and ultrasound-guided needle biopsy of the pleura were done to exclude any early malignant changes.^[12] An appropriate clinical history, imaging findings and image-guided biopsy is required to clinch the diagnosis of pleural thickening with pleural effusion. Pleural plaques or thickening alone need further follow-up.

There is no specific cure for pleural thickening because once the damage has been caused it is irreversible, but it is extremely important to have the disease diagnosed because pleural thickening could go on to cause additional complications. More case series studies and case reports may aid in this regard.

REFERENCES

- Occupational Lung Diseases. American Lung Association. State of Lung Disease in Diverse Communities; 2010. p. 63-8. Available from: <http://www.lung.org/assets/documents/publications/solddc-chapters/occupational.pdf>. [Last accessed on 2014 Feb 02].
- Downer NJ, Ali NJ, Au-Yong IT. Investigating pleural thickening. *BMJ* 2013;346:e8376.
- Hussein-Jelen T, Bankier AA, Eisenberg RL. Solid pleural lesions. *AJR Am J Roentgenol* 2012;198:W512-20.
- Sureka B, Thukral BB, Mittal MK, Mittal A, Sinha M. Radiological review of pleural tumors. *Indian J Radiol Imaging* 2013;23:313-20.
- Aberle DR, Gamsu G, Ray CS, Feuerstein IM. Asbestos-related pleural and parenchymal fibrosis: Detection with high-resolution CT. *Radiology* 1988;166:729-34.
- Hillerdal G, Malmberg P, Hemmingsson A. Asbestos-related lesions of the pleura: Parietal plaques compared to diffuse thickening studied with chest roentgenography, computed tomography, lung function, and gas exchange. *Am J Ind Med* 1990;18:627-39.
- Dalager NA, Mason TJ, Fraumeni JF Jr, Hoover R, Payne WW. Cancer mortality among workers exposed to zinc chromate paints. *J Occup Med* 1980;22:25-9.
- Papageorgiou I, Brown C, Schins R, Singh S, Newson R, Davis S, *et al.* The effect of nano- and micron-sized particles of cobalt-chromium alloy on human fibroblasts *in vitro*. *Biomaterials* 2007;28:2946-58.
- Aggarwal AN, Gupta D, Jindal SK. Diagnosis of tuberculous pleural effusion. *Indian J Chest Dis Allied Sci* 1999;41:89-100.
- Mizutani T, Arai K, Miyamoto M, Kimura Y. Application of silica-containing nano-composite emulsion to wall paint: A new environmentally safe paint of high performance. *Prog Org Coat* 2006;55:276-83.

11. Koss M, Travis W, Moran C, Hochholzer L. Pseudomesotheliomatous adenocarcinoma: A reappraisal. *Semin Diagn Pathol* 1992;9:117-23.
12. Choi IH, Jang SH, Lee S, Han J, Kim TS, Chung MP. A case report of IgG4-related disease clinically mimicking pleural mesothelioma. *Tuberc Respir Dis (Seoul)* 2014;76:42-5.

How to cite this article: Moitra S, Sen S, Datta A, Basu N. Pleural effusion with pleural thickening in a patient exposed to zinc chromate paints: A rare case report. *Int J Med Public Health* 2015;5:200-3.
Source of Support: Nil, **Conflict of Interest:** None declared.