

# Cryptogenic brain abscess due to community-associated methicillin-resistant *Staphylococcus aureus*

## Abstract

We report a case of cryptogenic brain abscess caused by infection due to community-associated methicillin-resistant *Staphylococcus aureus* (CA-MRSA) in a previously healthy, 2-year-old, girl child with a history of persistent headache and fever for several weeks. Headache acutely worsened the day before hospital admission with vomiting, right hemiparesis, and altered sensorium. Community-onset pyogenic brain abscess should be added to the growing list of life-threatening invasive infections caused by community-acquired *S. aureus*. Early diagnosis, prompt neurosurgical drainage, and appropriate medical therapy are important for management of such infections. In light of expanding community-acquired *S. aureus* epidemic and the life-threatening nature of the disease we recommend empirical use of vancomycin in all cases of community onset brain abscess.

**Key words:** MRSA, pyogenic brain abscess, *Staphylococcus aureus*, vancomycin

**Deepak Juyal,  
Shekhar Pal,  
Mahesh Ramola<sup>1</sup>,  
Vyas Kumar Rathaur<sup>2</sup>,  
Neelam Sharma,  
Anurag Ayachit<sup>3</sup>**

Departments of Microbiology and Immunology, <sup>1</sup>Neurosurgery, <sup>2</sup>Pediatrics, Veer Chandra Singh Garhwali Government Medical Sciences and Research Institute, Srinagar Garhwal, Uttarakhand, <sup>3</sup>Department of Radiodiagnosis and Imaging, Kasturba Medical College, Manipal, Karnataka, India

### Address for the Correspondence:

Mr. Deepak Juyal,  
Department of Microbiology and Immunology, Veer Chandra Singh Garhwali Govt Medical Sciences and Research Institute, Srinagar Garhwal - 246 174, Uttarakhand, India.  
E-mail: deepakk787@gmail.com

### Access this article online

Website: [www.ijmedph.org](http://www.ijmedph.org)

DOI: 10.4103/2230-8598.127176

Quick response code:



## INTRODUCTION

*Staphylococcus aureus* is among the most important pathogen because of both the diversity and the severity of infections it causes. Methicillin resistant *S. aureus* (MRSA) was first described in 1961<sup>[1]</sup> and since then has become a significant pathogen in nosocomial infections. Although historically considered as typical nosocomial pathogen, MRSA has rapidly emerged as a causative agent for community infections.<sup>[2]</sup> Risk factors for community acquisition are recent or frequent hospital admissions, frequent antibiotic exposure, chronic illness, prior surgery or a carrier in the family.<sup>[3]</sup> Recently, patients with no risk factors are presenting with community-associated MRSA (CA-MRSA) infections.<sup>[4]</sup> For clinicians, the spread of such methicillin resistant strains is a matter of concern as the therapeutic outcome of infections caused by MRSA is worse than that of caused by methicillin sensitive *S. aureus*.<sup>[5]</sup> In India the prevalence of infections due to CA-MRSA appears to be lower than the western countries, although recent reports highlight that these infections are on rise.

CA-MRSA harbors a Staphylococcal cassette chromosome *mec* (SCC*mec*) element that is distinct from those found in healthcare associated MRSA (HA-MRSA) strains and typically carries the Panton-Valentine leukocidin (PVL) toxin genes<sup>[6]</sup> encoding a toxin endowed with the ability to kill leukocytes.

Here we present a case of cryptogenic brain abscess caused by CA-MRSA in a previously healthy child.

## CASE REPORT

A 2-year-old girl child was brought to the emergency department of our hospital with a history of persistent headache and fever for several weeks. Headache acutely worsened the day before hospital admission associated with vomiting, right sided weakness, and altered sensorium (as noted by the parents). Initial examination showed temperature 39°C, heart rate 95 beats/min, respiratory rate 35 breaths/min, and blood pressure 120/85 mm Hg. The patient was too irritable to the central nervous system (CNS) examination to be done. Neurological examination confirmed right sided hemiparesis with anisocoria and mild disorientation (Glasgow coma scale 12/15). General physical examination was normal and pertinent negative findings included no adventitial lung sounds; no heart murmurs; abdomen was soft without

any organomegaly; extremities were normal; and no cutaneous rash, sore, or abscess was noted. A full sepsis profile and a brain computed tomography (CT) scan was requested.

Brain CT scan revealed multiple small to large, coalescing, hypodense parenchymal lesions [Figure 1a]; largest measuring about 5 × 5 cm in size [Figure 1b] in the left temporal, frontal, and parietal regions. The lesions had peripherally enhancing thin-walled collections with extensive perilesional vasogenic edema, resultant mass effect, and diffuse cerebral edema. Significant midline shift to the right was noted with subfalcine herniation [Figure 1c], compression of left lateral and third ventricle. Dilatation of right lateral ventricle was seen and significant mid brain rotation was also noted. The findings were suggestive of multiple ring enhancing lesions and cerebral abscess.

Blood work up showed a white blood cell (WBC) count of 19,500 cells/ml with 89% polymorphonuclear leukocytes (PMN's) and hemoglobin 12.6 gm/dl. Serum C-reactive protein (24 mg/dl) and procalcitonin (8 U/l) levels were elevated. Arterial blood gases and chest X-ray were normal. Lumbar puncture was not done to avoid any possible herniation. Empirical treatment with intravenous (IV) ceftazidime and metronidazole was started and patient was transferred to the neurosurgical intensive care unit (ICU). The patient was taken emergently to the operating room for surgical decompression and abscess evacuation through a left temporal burr hole under general anesthesia and about 120 ml of thick yellow pus was evacuated which was immediately sent for microbiological investigations. Gram stain of the aspirated pus showed plenty of PMN's and many gram positive cocci in clusters. IV vancomycin was added to the regime.

Two days following admission, the aspirated specimen yielded a pure growth of MRSA, susceptible to tetracycline, clindamycin, gentamicin, cotrimoxazole, and vancomycin; and resistant to methicillin, erythromycin, ciprofloxacin, penicillin, and ampicillin-sulbactam. Same treatment was continued. Anaerobic culture of the

aspirated pus and blood samples collected before the administration of antibiotics yielded no bacterial growth.

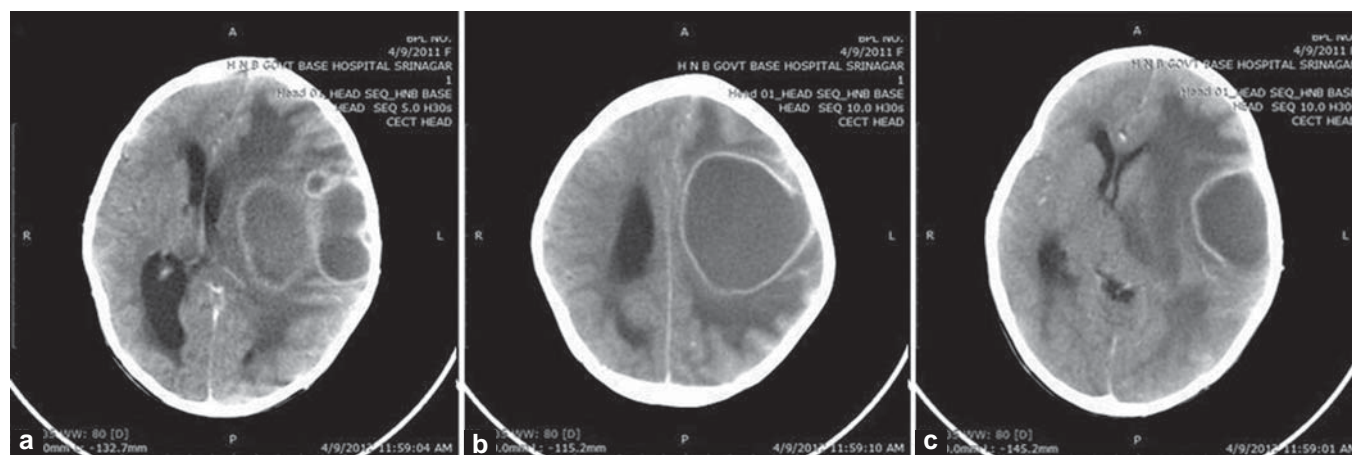
The postoperative course was uneventful without any clinical or laboratory evidence of infection. Aspiration of the abscess was repeated on 9<sup>th</sup> and 17<sup>th</sup> day of the therapy and culture of these specimens were negative. Nasal swabs taken for infection control measure were negative for *S. aureus*. Parenteral antibiotic therapy was continued for 3 weeks and was followed by 8 weeks course of teicoplanin (800 mg thrice/week). During this treatment, the patient remained afebrile and there were no signs of infection at a 6 month follow-up examination. CT scan taken at this point revealed no obvious abscess [Figure 2].

### Characterization of MRSA

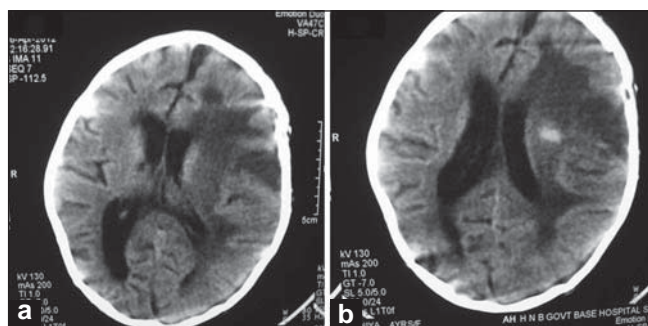
*S. aureus* was identified by standard microbiological methods. Antibiotic susceptibility testing was performed by Kirby-Bauer disk diffusion method on Muller-Hinton agar (HiMedia Laboratories Pvt. Ltd, India) supplemented with 2% NaCl. Methicillin resistance was confirmed using PBP2a latex agglutination test (Oxoid Ltd, Hampshire, UK) and then by polymerase chain reaction (PCR) assay targeting *mecA* gene. Further characterization of the organism was obtained by PCR assay for SCC*mec* type and presence of PVL genes *lukS*-PV and *lukF*-PV. The isolate carried SCC*mec* type IV and genes coding PVL confirming it to be a CA-MRSA strain. The results of the D-test were negative for inducible clindamycin resistance.

### DISCUSSION

*S. aureus* is estimated to cause 10-21% of all pyogenic brain abscesses<sup>[7]</sup> and the pathogenesis of brain abscess is largely comprehended in terms of the route of pathogen dissemination to brain. Infection most commonly occurs after direct inoculation during neurosurgical procedures, cranial trauma, from contagious foci such as sinusitis, mastoiditis, and facial or scalp infections.<sup>[7]</sup> Hematogenous dissemination of *S. aureus* from a peripheral source (pneumonia or endocarditis) is



**Figure 1:** Preop computed tomography (CT) scan pictures. (a) Shows multiple, lobulated, hypodense, coalescing lesions in the left cerebral hemisphere with extensive perilesional vasogenic edema. (b) At level of corona radiata. Shows lobulated, hypodense, parenchymal lesion in the left frontal-parietal region with marked vasogenic edema surrounding it. (c) At level of foramen of Monro. Shows a similar well defined left temporal lesion with isodense thin wall, significant midline shift to the right with subfalcine herniation and midbrain rotation



**Figure 2:** Postop CT scan pictures. (a, b) Follow-up CT scan shows no obvious abscess, mild residual midline shift, prominence of ventricular system, and residual calcification.

an infrequent manifestation because of the high intrinsic resistance of the blood brain barrier to infection.<sup>[7]</sup> In a subset of cases there is an underlying medical condition such as congenital heart disease, human immunodeficiency virus (HIV), IV drug use, diabetes, or alcoholism.<sup>[8]</sup> In 20-30% of cases no source of infection can be identified and these are considered as cryptogenic.<sup>[7]</sup> The development of a serious infections in children without predisposing conditions is a typical feature of CA-MRSA. The most common infections resulting from CA-MRSA involve skin and soft tissue, though cases of fatal, invasive infections have occurred in children <sup>[9]</sup> and only recently, CA-MRSA was found to cause CNS infections. Further, CA-MRSA are often PVL positive<sup>[6]</sup> and infections with such strains are associated with higher mortality.<sup>[9]</sup>

Diagnosis in our case was based on clinical investigation, neuroimaging, and positive abscess aspirate culture. Laboratory results were supported by neurological findings and brain CT. On neurological examination the classic triad of fever, headache, and focal neurological deficits were present. Signs and/or symptoms of raised intracranial pressure including nausea, vomiting, and papilledema were present.

Outcomes for patients with CA-MRSA brain abscesses have not been thoroughly studied. The overall mortality rate for brain abscesses is decreasing; however, rupture of the brain abscess into the ventricular system remains a devastating complication often resulting in death.<sup>[8]</sup> The prompt diagnosis, timely surgical abscess evacuation, and appropriate therapy lead to the successful treatment of our patient. The patient showed progressive improvement and at follow-up 6 months later was doing well. However, authors were not able to determine how the patient acquired MRSA. In previous studies, the patent foramen ovale (PFO) has been suggested to be a potential source of embolism leading to cryptogenic stroke. There have been four reported cases describing an association between cryptogenic brain abscess and PFO.<sup>[10]</sup> Proposed explanations for this association include poor dental hygiene resulting in systemic oral flora to gain access into the arterial system via a PFO. Alternatively, PFO may be a predisposing factor to hematogenous spread from a primary silent focus.

## CONCLUSION

*S. aureus* is a common cause of pyogenic brain abscess. The pathogenesis and clinical features of the Staphylococcal brain

abscess do not differ from pyogenic brain abscess caused by other microorganisms. This observation highlights the importance of obtaining abscess aspirate and/or biopsy specimens for specific microbiological diagnosis. Optimal management of pyogenic brain abscess includes a combination of prompt neuroimaging, neurosurgical drainage, and appropriate medical therapy. A combination of third generation cephalosporin and metronidazole has traditionally been recommended for empirical treatment of community-onset brain abscess. In light of the expanding CA-MRSA epidemic and life-threatening nature of the disease we recommend empirical use of vancomycin in all cases of community onset brain abscess potentially caused by *S. aureus* infection pending culture and *in vitro* susceptibility test results, even in patients without clear risk factors for CA-MRSA infection. Similar recommendations have been made by other authors.<sup>[7,11]</sup>

## Consent

A written informed consent was obtained from the patient's parents for publication of this case report and of the accompanying image.

## REFERENCES

1. Jevons MP. 'Celbenin'-resistant staphylococci. *Br Med J* 1961;1:124-5.
2. Naesens R, Druwé P, Denis O, Ieven M, Jeurissen A. Central nervous system invasion by community-acquired methicillin-resistant *Staphylococcus aureus*. *J Med Microbiol* 2009;58:1247-51.
3. Salgado CD, Farr BM, Calfee DP. Community-acquired methicillin resistant *Staphylococcus aureus*: A meta-analysis of prevalence and risk factors. *Clin Infect Dis* 2003;36:131-9.
4. Sattler CA, Mason EO Jr, Kaplan SL. Prospective comparison of risk factors and demographic and clinical characteristics of community-acquired, methicillin-resistant versus methicillin-susceptible *Staphylococcus aureus* infection in children. *Pediatr Infect Dis J* 2002;21:910-7.
5. Cosgrove SE, Sakoulas G, Perencevich EN, Schwaber MJ, Karchmer AW, Carmeli Y. Comparison of mortality associated with methicillin-resistant and methicillin-susceptible *Staphylococcus aureus* bacteremia: A meta-analysis. *Clin Infect Dis* 2003;36:53-9.
6. Boyle-Vavra S, Daum RS. Community-acquired methicillin-resistant *Staphylococcus aureus*: The role of Pantone-Valentine leukocidin. *Lab Invest* 2007;87:3-9.
7. Tunkel AR. Brain abscess. In: Mandell GL, Bennett JE, Dolin R, editors. *Mandell, Douglas, and Bennett's Principles and Practice of Infectious Diseases*. 6<sup>th</sup> ed. Philadelphia: Elsevier/Churchill Livingstone; 2005. p. 1150-63.
8. Carpenter J, Stapleton S, Holliman R. Retrospective analysis of 49 cases of brain abscess and review of the literature. *Eur J Clin Microbiol Infect Dis* 2007;26:1-11.
9. Nourse C, Starr M, Munckhof W. Community-acquired methicillin-resistant *Staphylococcus aureus* causes severe disseminated infection and deep venous thrombosis in children: Literature review and recommendations for management. *J Paediatric Child Health* 2007; 43:656-61.
10. Khouzam RN, El-Dokla AM, Menkes DL. Undiagnosed PFO presenting as a cryptogenic brain abscess: Case report and review of literature. *Heart Lung* 2006;35:108-11.
11. Sifri CD, Park J, Helm GA, Stemper ME, Shukla SK. Fatal brain abscess due to community-associated methicillin-resistant *Staphylococcus aureus* strain USA300. *Clin Infect Dis* 2007;45:e113-7.

**How to cite this article:** Juyal D, Pal S, Ramola M, Rathaur VK, Sharma N, Ayachit A. Cryptogenic brain abscess due to community-associated methicillin-resistant *Staphylococcus aureus*. *Int J Med Public Health* 2014;4:134-6.

**Source of Support:** Nil, **Conflict of Interest:** None declared.