Section: Nephrology

Original Research Article

AN ADOLESCENT GIRL WITH HEAVY MENSTRUAL BLEEDING AND A MISSING KIDNEY: A RARE CASE OF OHVIRA SYNDROME

Prabin Kumar Majhi[1], Surai Murmu[2], Pramod Kumar Senapati[3], Prity Ering[4]

[1]*Consultant Nephrologist, Department of Nephrology, Kalinga Hospital, Bhubaneswar, India.*
[2]*HOD and Consultant Radiologist, Department of Radiology, Kalinga Hospital, Bhubaneswar, India.*
[3]*Consultant O&G, Department of Obstetrics and Gynaecology, Kalinga Hospital, Bhubaneswar, India.*
[4]*Consultant Neurologist, Department of Neurology, Kalinga Institute of Medical sciences, Bhubaneswar, India.*

Received *: 05/09/2026*
Received in revised form *: 04/10/2026*
Accepted *: 16/10/2026*

Corresponding Author:
Dr. Prabin Kumar Majhi,
Consultant Nephrologist, Department of Nephrology, Kalinga Hospital, Bhubaneswar, India.

DOI: 10.70034/ijmedph.2026.4.376

Source of Support: Nil,
Conflict of Interest: None declared

Int J Med Pub Health
2026; 16 (4); 2505-2509

ABSTRACT

Background: OHVIRA Syndrome, also known as Herlyn–Werner–Wunderlich syndrome, is a rare congenital Müllerian duct anomaly characterized by uterus didelphys, obstructed hemivagina and ipsilateral renal anomaly. Delayed diagnosis is common because patients may initially present with nonspecific gynaecological symptoms after menarche.

Case Presentation: We report the case of a 17-year-old female student, born out of a non-consanguineous marriage through normal vaginal delivery, with normal developmental milestones and regular menstrual cycles since menarche at 14 years of age. She presented with intermittent low grade headache, heavy menstrual bleeding for four months along with intermittent lower abdominal pain for two to three months. Ultrasonography revealed non visualization of the left kidney along with a uterine structural abnormality. Clinical examination was unremarkable except for mild pallor. Laboratory investigations showed mild anemia with normal renal and liver function tests. In view of a suspected Müllerian duct fusion anomaly, magnetic resonance imaging of the pelvis was performed, which demonstrated uterus didelphys with obstructed right hemivagina, confirming the diagnosis of OHVIRA syndrome.

Conclusion: OHVIRA syndrome is a rare but clinically significant congenital anomaly requiring a high index of suspicion in adolescent females presenting with menstrual abnormalities and renal agenesis. Early recognition and appropriate radiological evaluation are essential to prevent long term gynaecological and reproductive complications.

Keywords: OHVIRA syndrome; Herlyn–Werner–Wunderlich syndrome; uterus didelphys; obstructed hemivagina; renal agenesis; Müllerian duct anomaly.

INTRODUCTION

OHVIRA Syndrome is a rare congenital Müllerian duct anomaly characterized by the triad of uterus didelphys, obstructed hemivagina and ipsilateral renal agenesis. The syndrome arises due to abnormal development and defective fusion of the Müllerian and mesonephric ducts during embryogenesis. Müllerian duct anomalies have an estimated incidence ranging from 0.1% to 3.8% in the general population,[1,2] while OHVIRA syndrome represents a small subset of these anomalies.[3] The estimated population incidence of OHVIRA syndrome is approximately,[1] in 20,000 females.[4] Data regarding the prevalence of OHVIRA syndrome in India remain limited because of the absence of national registries and the rarity of the condition. Most Indian literature consists of isolated case reports and small case series, suggesting that the syndrome is likely underdiagnosed, particularly in patients with nonspecific symptoms and initially normal menstrual cycles.[5]

Patients usually remain asymptomatic until after menarche, when retained menstrual blood within the obstructed hemivagina results in progressive pelvic pain, dysmenorrhea, abnormal menstrual bleeding,

hematocolpos or pelvic mass formation.[6,7] Because menstruation from the unobstructed hemivagina may remain normal initially, diagnosis is frequently delayed.[5,6] Imaging modalities such as ultrasonography and magnetic resonance imaging (MRI) play a pivotal role in identifying uterovaginal anomalies and associated renal abnormalities.[2,3]

We report a rare case of OHVIRA syndrome in a 17-year-old adolescent female who presented with heavy menstrual bleeding and intermittent lower abdominal pain and was subsequently diagnosed following evaluation for unilateral renal agenesis.[1,7]

CASE PRESENTATION

A 17-year-old female student studying in class 12 presented with complaints of intermittent low grade headache for four months, progressively increasing heavy menstrual bleeding for four months and intermittent lower abdominal pain for the preceding two to three months. She was born out of a non-consanguineous marriage through normal vaginal delivery and had achieved normal developmental milestones. Menarche occurred at 14 years of age, following which her menstrual cycles remained regular with normal interval, flow and duration for approximately two years prior to the onset of symptoms.

The heavy menstrual bleeding was characterized by prolonged menstrual flow, passage of clots and increased pad usage compared to her previous cycles. The abdominal pain was dull aching, non radiating, intermittent in nature and progressively increasing in frequency and severity. There was no history of fever, urinary complaints, weight loss, bowel disturbances or prior abdominal surgery.

She had no known co-morbidities and no family history of kidney disease or congenital anomalies. She initially consulted a nearby obstetrics and gynaecology practitioner and was advised symptomatic treatment along with radiological evaluation. Ultrasonography of the abdomen and pelvis revealed non visualization of the left kidney along with an anatomical abnormality of the uterus. In view of the unilateral renal anomaly, she was referred to the Nephrology department for further evaluation.

On examination, the patient was hemodynamically stable. Blood pressure, pulse rate, respiratory rate and temperature were within normal limits. General physical examination revealed mild pallor, while systemic examination was otherwise unremarkable.

Laboratory investigations demonstrated mild anemia, whereas renal and liver function tests were within normal limits. Urinalysis was unremarkable. Considering the coexistence of unilateral renal agenesis and a suspected Müllerian duct anomaly, magnetic resonance imaging (MRI) of the pelvis was advised. MRI pelvis demonstrated uterus didelphys with obstructed right hemivagina, consistent with OHVIRA Syndrome [Figure 1(a),1(b),2,3]. The radiological findings confirmed the diagnosis of obstructed hemivagina and ipsilateral renal anomaly syndrome.

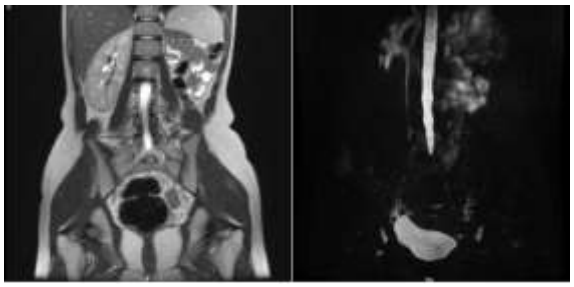

Figure 1(a): Coronal T2 weighted MRI showing ipsilateral renal agenesis, one of the classical triads of OHVIRA syndrome

Figure 1(b): Coronal MR urography demonstrating non visualization of the kidney on the left side, with preservation of the right sided renal collecting system, consistent with unilateral renal agenesis.

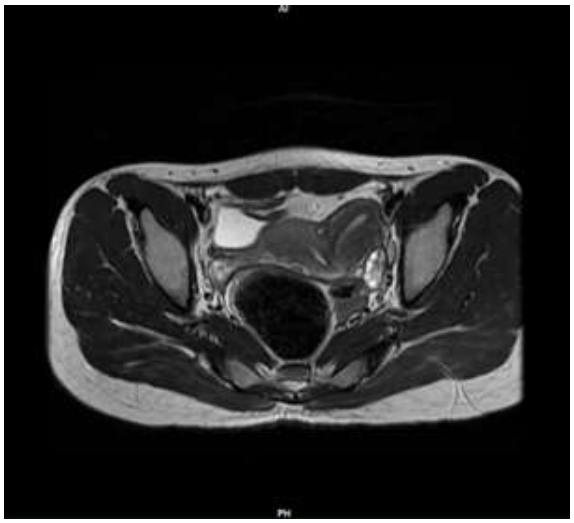

Figure 2: Axial T2 weighted MRI of the pelvis demonstrating uterine duplication with a distended, fluid filled hemivagina (hematocolpos) due to vaginal obstruction, consistent with the Müllerian anomaly component of OHVIRA syndrome

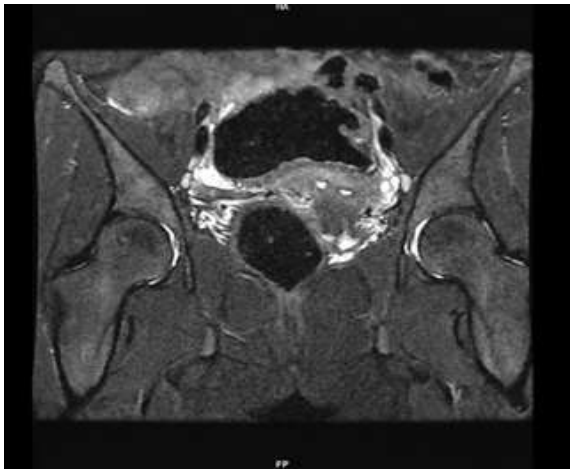

Figure 4: Coronal T2 weighted MRI of the pelvis demonstrating an obstructed, distended hemivagina (hematocolpos), consistent with the Müllerian anomaly component of OHVIRA syndrome

The patient and her family were counseled regarding the congenital nature of the condition and referred for definitive gynaecological management to relieve the obstruction and prevent long term gynaecological and reproductive complications.

DISCUSSION

Obstructed Hemivagina and Ipsilateral Renal Anomaly (OHVIRA) Syndrome, also known as Herlyn–Werner–Wunderlich syndrome, is a rare developmental anomaly resulting from defective lateral fusion of the Müllerian ducts along with abnormal mesonephric duct development. The syndrome classically consists of the triad of uterus didelphys, obstructed hemivagina, and ipsilateral renal agenesis.[2,3] The embryological basis of this association lies in the close developmental relationship between the Müllerian and Wolffian ducts. Failure of normal ductal fusion and canalization results in duplication anomalies of the uterus and vagina, while associated mesonephric duct maldevelopment contributes to renal agenesis.[3]

Most patients become symptomatic shortly after menarche due to progressive accumulation of menstrual blood within the obstructed hemivagina. Common clinical manifestations include dysmenorrhea, chronic pelvic pain, lower abdominal pain, abnormal menstrual bleeding, hematocolpos and occasionally urinary symptoms.[4] However, menstruation through the unobstructed hemivagina may remain normal initially, often leading to delayed diagnosis.[5]

Indian literature regarding OHVIRA syndrome remains limited and primarily consists of isolated case reports and small institutional series.[5,6] In 2017, Rudra and Dahiya from Haryana, India, reported a case of a 15-year-old girl presenting with cyclic lower abdominal pain in whom ultrasonography and MRI established the diagnosis of OHVIRA syndrome.[8] In 2021, Shah et al. from Mumbai described a 26-year-old female with regular menstrual cycles and intermittent abdominal pain who was diagnosed with uterus didelphys, obstructed hemivagina, and ipsilateral renal agenesis on MRI and hysteron-laparoscopy.[9] More recently, in 2025, Annapurna et al. from Andhra Pradesh reported delayed diagnosis of Herlyn–Werner–Wunderlich syndrome in a 38-year-old woman presenting with primary infertility, emphasizing that incomplete obstruction may delay clinical recognition until adulthood.[10]

In our case, the patient presented with heavy menstrual bleeding and intermittent lower abdominal pain despite having normal menstrual cycles for nearly two years after menarche. The incidental identification of unilateral renal agenesis on ultrasonography raised suspicion for an associated Müllerian duct anomaly, which was subsequently confirmed on MRI pelvis.

Ultrasonography is usually the initial imaging modality because of its accessibility and non-invasive nature; however, MRI remains the gold standard because of its superior delineation of uterine morphology, vaginal anatomy, hematocolpos and associated renal abnormalities.[1,2] Early diagnosis is essential because delayed treatment may lead to complications such as hematocolpos, hematometra, endometriosis, pelvic adhesions, recurrent pelvic infections, infertility and adverse obstetric outcomes.[3,7]

Definitive management generally involves surgical excision or septal resection of the obstructed hemivagina to establish adequate menstrual drainage and preserve future reproductive potential.[1,3] Prognosis is generally favorable following timely diagnosis and intervention.

This case highlights the importance of considering Obstructed Hemivagina and Ipsilateral Renal Anomaly syndrome in adolescent females presenting with menstrual abnormalities and unilateral renal agenesis. Early multidisciplinary collaboration among Gynaecology, Rradiology, Neurology and Nnephrology departments play a crucial role in prompt diagnosis and appropriate management.

CONCLUSION

OHVIRA syndrome is a rare congenital Müllerian duct anomaly that should be suspected in adolescent females presenting with pelvic pain, abnormal menstrual bleeding and unilateral renal agenesis. MRI pelvis plays a pivotal role in confirming the diagnosis. Early identification and timely surgical management are crucial to prevent long term Gynaecological and reproductive complications.

REFERENCES

1. Madhumitha, J., Charumathi, R., Sundaram, M., & Parthasarathy, A. (2024). Herlyn Werner Wunderlich Syndrome/OHVIRA: A Rare Case Report with Successful Laparoscopy Assisted Vaginoplasty. The Journal of Obstetrics and Gynecology of India. https://doi.org/10.1007/s13224-024-02039-8
2. Kozłowski, M., Nowak, K., Boboryko, D., Kwiatkowski, S., & Cymbaluk-Płoska, A. (2020). Herlyn-Werner-Wunderlich Syndrome: Comparison of Two Cases. International Journal of Environmental Research and Public Health, 17(19), 7173. https://doi.org/10.3390/ijerph17197173
3. Moufawad, G., Giannini, A., D'Oria, O., Laganà, A. S., Chiantera, V., Khazzaka, A., Maziad, G., Nasr, E., Geagea, V., Jardali, M. A., & Sleiman, Z. (2023). Obstructed Hemivagina and Ipsilateral Renal Anomaly Syndrome: A Systematic Review about Diagnosis and Surgical Management. Gynecology and Minimally Invasive Therapy, 12(3), 123-129. https://doi.org/10.4103/gmit.gmit_103_22
4. AlBaik, T. M., Ibrahim, A. T., AbuKaresh, N. A., Anini, E. M., Hattab, L. M., & Albandak, M. (2024). A rare case of obstructed hemivagina with uterus didelphys and ipsilateral renal anomaly syndrome. SAGE Open Medical Case Reports, 12, 2050313X241256517. https://doi.org/10.1177/2050313x241256517
5. Seth, S., Agarwal, N., Sharma, R., & Mishra, P. (2020). OHVIRA Syndrome—Diagnostic Dilemmas and Review of Literature. Journal of South Asian Federation of Obstetrics

and Gynaecology, 12(6), 421-426. https://doi.org/10.5005/jp-journals-10006-1847
6. Mittal, R. (2015). Herlyn-Werner-Wunderlich Syndrome. The Journal of Obstetrics and Gynecology of India, 66(2), 128–130. https://doi.org/10.1007/s13224-015-0707-8
7. Jaybhaye, S. B. (2019). Herlyn-Werner-Wunderlich Syndrome: A Rare Müllerian Anomaly. Journal of SAFOMS, 7(1), 34-36. https://doi.org/10.5005/jp-journals-10032-1167
8. Rudra, S., & Dahiya, N. (2017). OHVIRA syndrome: a rare variant of mullerian duct anomaly. International Journal of Reproduction, Contraception, Obstetrics and Gynecology, 6(1), 326–328. https://doi.org/10.18203/2320-1770.ijrcog20164688
9. Shah, N., Changede, P., & Bandgar, V. (2021). OHVIRA Syndrome (Obstructed Hemivagina with Ipsilateral Renal Agenesis). The Journal of Obstetrics and Gynecology of India, 71(Suppl), 1-4. https://doi.org/10.1007/s13224-021-01445-w
10. Annapurna, D. R., Bhargavi, D. K., & Hasamnis, D. V. A. (2025). Case Report – A Rare Case of Ohvira, Herlyn-Werner-Wunderlich Syndrome – A Diagnostic Conundrum. European Journal of Cardiovascular Medicine, 15(3), 216-218.