Section: Pathology

Original Research Article

COMPARATIVE IMMUNOHISTOCHEMICAL EXPRESSION OF CYCLIN D1 IN ENDOMETRIAL LESIONS

B. Syam Sundara Rao[1], E. Kavya[2], K. Durga[3], N. Mohan Rao[4], M. Vijayalakshmi[5], J. Pratima[6]

[1]*Professor, Department of Pathology, Narayana Medical College, Nellore, Andhra Pradesh, India.*
[2]*Senior Resident, Department of Pathology Sri Balaji Medical College, Renigunta. Tirupati (D), Andhra Pradesh, India.*
[3]*Professor & HOD, Department of Pathology, Narayana Medical College, Nellore, Andhra Pradesh, India.*
[4]*Professor, Department of Pathology, Narayana Medical College, Nellore, Andhra Pradesh, India.*
[5]*Professor, Department of Pathology, Narayana Medical College, Nellore, Andhra Pradesh, India.*
[6]*Assistant Professor, Department of Pathology, Narayana Medical College, Nellore, Andhra Pradesh, India.*

Received *: 08/08/2026*
Received in revised form *: 04/09/2026*
Accepted *: 18/09/2026*

Corresponding Author:
Dr B. Syam Sundara Rao
Professor, Department of Pathology, Narayana Medical College, Nellore, Andhra Pradesh, India.
Email: syam.byna@gmail.com

DOI: 10.70034/ijmedph.2026.4.365

Source of Support: Nil,
Conflict of Interest: None declared

Int J Med Pub Health
2026; 16 (4); 2420-2426

ABSTRACT

Background: Endometrial carcinoma is one of the most common gynecological malignancies affecting women, particularly during the perimenopausal and postmenopausal periods. The progression from normal proliferative endometrium to hyperplasia and carcinoma involves multiple molecular alterations, among which Cyclin D1 plays an important role in cell cycle regulation and tumorigenesis. Cyclin D1 is a nuclear regulatory protein that promotes transition from G1 phase to S phase of the cell cycle, and its overexpression has been implicated in uncontrolled cellular proliferation and malignant transformation. The present study was undertaken to evaluate the immunohistochemical expression of Cyclin D1 in proliferative endometrium, endometrial hyperplasia, and endometrial carcinoma and to assess its significance in endometrial carcinogenesis.

Materials and Methods: The present observational study included 120 endometrial tissue specimens obtained from hysterectomy and endometrial biopsy samples. Histopathological evaluation was performed using Hematoxylin and Eosin staining, and cases were categorized into proliferative endometrium, hyperplasia without atypia, hyperplasia with atypia, and endometrial carcinoma. Immunohistochemical staining for Cyclin D1 was carried out in all cases. Cyclin D1 expression was graded as weak positivity (+1), moderate positivity (+2), and strong positivity (+3) based on the intensity of nuclear staining. Statistical analysis was performed to evaluate the distribution and expression pattern among different endometrial lesions.

Results and Discussion: The majority of patients belonged to the 41–50 years age group, accounting for 41.7% of cases, indicating increased prevalence of endometrial lesions during the perimenopausal period. Proliferative endometrium was the most common histological pattern observed (33.3%), followed by hyperplasia without atypia (29.2%), hyperplasia with atypia (16.7%), and endometrial carcinoma (20.8%). Cyclin D1 expression demonstrated a progressive increase from benign to malignant lesions. In proliferative endometrium, most cases showed weak positivity (+1), whereas hyperplasia without atypia predominantly exhibited moderate positivity (+2). Hyperplasia with atypia showed increased strong positivity (+3), suggesting higher proliferative activity and malignant potential. Notably, all cases of endometrial carcinoma demonstrated intense Cyclin D1 expression (+3), highlighting the significant role of Cyclin D1 in endometrial carcinogenesis. The findings of the present study are consistent with previous studies that reported increased Cyclin D1 expression with progression of endometrial lesions.

Conclusion: Cyclin D1 expression progressively increases from proliferative endometrium to hyperplasia and endometrial carcinoma, indicating its important role in the pathogenesis and progression of endometrial malignancy. Strong Cyclin D1 positivity in carcinoma cases suggests that it may serve as a useful immunohistochemical biomarker for identifying premalignant and malignant endometrial lesions and may aid in early diagnosis and prognostic evaluation.
Keywords: Immunohistochemical biomarker, Cyclin D1, hyperplasia, Hematoxylin.

INTRODUCTION

Endometrial carcinoma is one of the most common malignancies affecting the female genital tract and represents a major health burden worldwide. The incidence of endometrial carcinoma has shown a steady increase over the past few decades due to changing lifestyle factors, obesity, diabetes mellitus, hypertension, nulliparity, and prolonged exposure to unopposed estrogen.[1] The disease predominantly affects peri-menopausal and post-menopausal women, although an increasing number of younger women are also being diagnosed in recent years.[2] Abnormal uterine bleeding remains the most common presenting symptom and often serves as an early indicator of underlying endometrial pathology.[3]

The endometrium is a hormonally responsive tissue that undergoes cyclical proliferative, secretory, and menstrual changes under the influence of estrogen and progesterone. Estrogen stimulates endometrial proliferation, while progesterone counteracts this effect by inducing secretory differentiation. Persistent estrogenic stimulation without adequateprogesterone opposition results in excessive endometrial proliferation and subsequently predisposes to hyperplasia and malignant transformation.[4] Endometrial hyperplasia, especially atypical hyperplasia or endometrial intraepithelial neoplasia (EIN), is considered a precursor lesion for endometrioid endometrial carcinoma.[5]

The development of endometrial carcinoma is a multistep process involving morphological, hormonal, genetic, and molecular alterations. Several molecular pathways have been implicated in endometrial carcinogenesis, including mutations in PTEN, PIK3CA, KRAS, β-catenin, microsatellite instability, and alterations in cell cycle regulatory proteins.[6] Among these molecular abnormalities, dysregulation of cell cycle proteins plays a crucial role in uncontrolled cellular proliferation and neoplastic transformation.[7]

Cell cycle progression is tightly controlled by cyclins, cyclin-dependent kinases (CDKs), and tumor suppressor genes. Cyclin D1 is an important proto-oncogenic protein encoded by the CCND1 gene located on chromosome 11q13. Cyclin D1 regulates the transition of cells from the G1 phase to the S phase through activation of CDK4 and CDK6, resulting in phosphorylation of the retinoblastoma protein and initiation of DNA synthesis.[8]Overexpression of Cyclin D1 leads to uncontrolled cell proliferation, genomic instability, and tumor development. Increased Cyclin D1 expression has been demonstrated in several malignancies including breast carcinoma, colorectal carcinoma, esophageal carcinoma, ovarian carcinoma, and endometrial carcinoma.[9]

Recent studies have highlighted the significant role of Cyclin D1 in the pathogenesis and progression of endometrial lesions. Progressive increase in Cyclin D1 expression hasbeen reported from proliferative endometrium to endometrial hyperplasia and finally to carcinoma, suggesting its involvement in sequential malignant transformation.[10] Increased Cyclin D1 expression has also been associated with higher proliferative activity, cytological atypia, aggressive tumor behavior, and poor prognostic factors such as deeper myometrial invasion and advanced stage disease.[11]

Immunohistochemistry (IHC) has emerged as an important ancillary diagnostic tool in evaluating endometrial lesions. Assessment of Cyclin D1 expression by IHC helps in identifying proliferative activity and provides insight into molecular alterations occurring during endometrial carcinogenesis.[12]Several authors have demonstrated significantly increased Cyclin D1 immunoreactivity in atypical hyperplasia and endometrial carcinoma compared to normal proliferative endometrium.[13] These findings suggest that Cyclin D1 may serve as a useful biomarker in differentiating benign, premalignant, and malignant endometrial lesions.

In the present study, the majority of patients belonged to the 41–50 years age group, indicating that endometrial lesions are more common during the perimenopausal period. Histopathological examination revealed proliferative endometrium as the most common pattern, followed by hyperplasia without atypia, atypical hyperplasia, and endometrial carcinoma. Immunohistochemical analysis demonstrated progressive increase in Cyclin D1 expression from proliferative endometrium to carcinoma, thereby supporting the role of Cyclin D1 in endometrial carcinogenesis and tumor progression.

Therefore, the present study was undertaken to evaluate the immunohistochemical expression of Cyclin D1 in proliferative endometrium, endometrial hyperplasia, andendometrial carcinoma

and to assess its significance in the progression of endometrial pathology.[14,15]

MATERIALSANDMETHODS

This prospective and retrospective observational study was conducted in the Department of Pathology from July 2022 to December 2025. A total of 120 endometrial biopsy and hysterectomy specimens were included. Cases were categorized into proliferative endometrium, hyperplasia without atypia, hyperplasia with atypia and endometrial carcinoma. Tissue sections were processed routinely and stained with hematoxylin and eosin. Immunohistochemistry for Cyclin D1 was performed using polymer-HRP method. Nuclear staining intensity was graded as +1 (weak), +2 (moderate) and +3 (strong). Statistical analysis was performed using SPSS version 25.0.

RESULTS

The present study included patients distributed across different age groups ranging from 21 years to above 60 years. The highest number of cases was observed in the 41–50 years age group, accounting for 41.7% of the total study population. This finding indicates that endometrial lesions are more commonly encountered during the perimenopausal period. Hormonal imbalance, prolonged estrogen exposure, and irregular ovulatory cycles occurring during this age may contribute significantly to the development of endometrial abnormalities.

Table 1: Age Distribution of Study Subjects

AgeGroup	NumberofCases	Percentage
21-30	12	10.0
31-40	28	23.3
41-50	50	41.7
51-60	22	18.3
>60	8	6.7

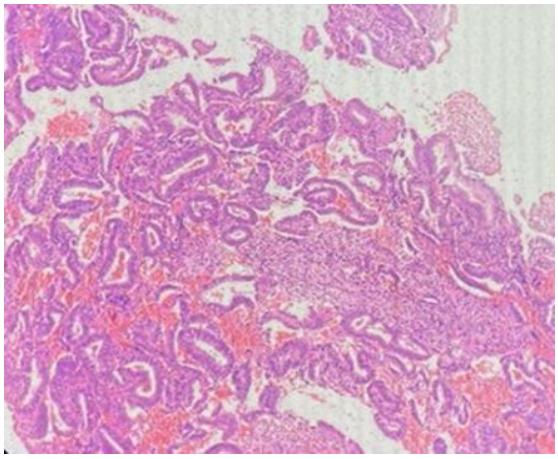

Figure 1: H and E (10x) of endometrial hyperplasia without atypia showing closely packed glands with increased glandular to stroma ratio and with stromal breakdown

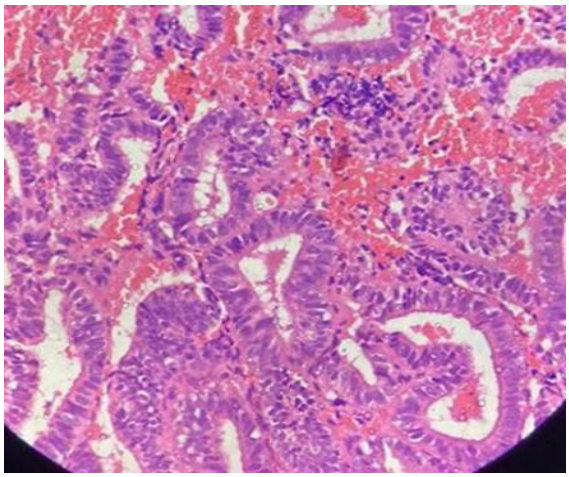

Figure 2: H and E of endometrial hyperplasia without atypia (40x) showing hyperchromasia of nuclei

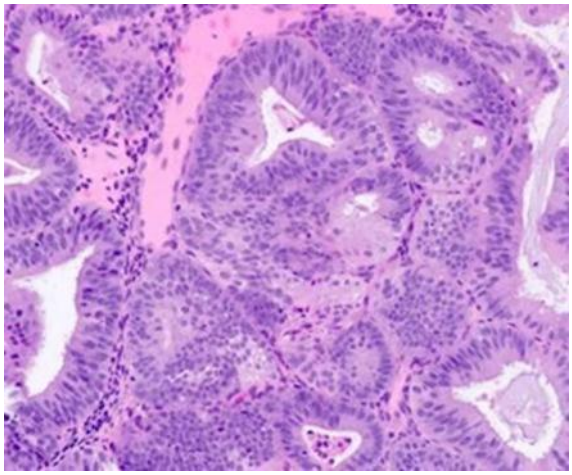

Figure 3: H and E of endometrial hyperplasia with atypia(40x) showing loss of polarity, round to oval hyperchromatic nuclei, open chromatin and prominent nucleoli

The second most commonly affected age group was 31–40 years, constituting 23.3% of cases, followed by the 51–60 years age group with 18.3% of cases. Younger women aged 21–30 years represented only 10% of the study population, while patients older than 60 years constituted the least affected group with 6.7% of cases. The lower incidence in younger women may be attributed to relatively stable hormonal cycles and lesser exposure to risk factors associated with endometrial proliferation.

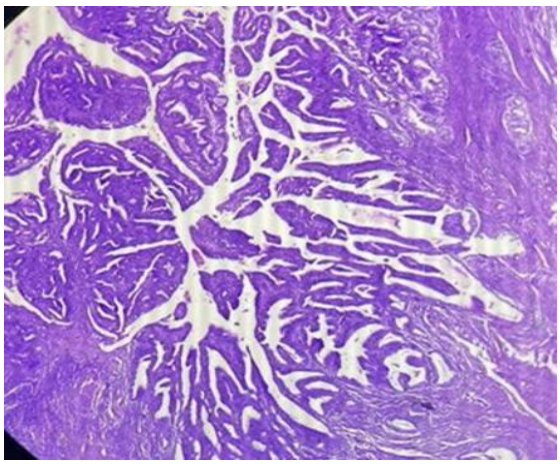

Figure 4: H and E (10x) of endometrial carcinoma showing papillary arrangement

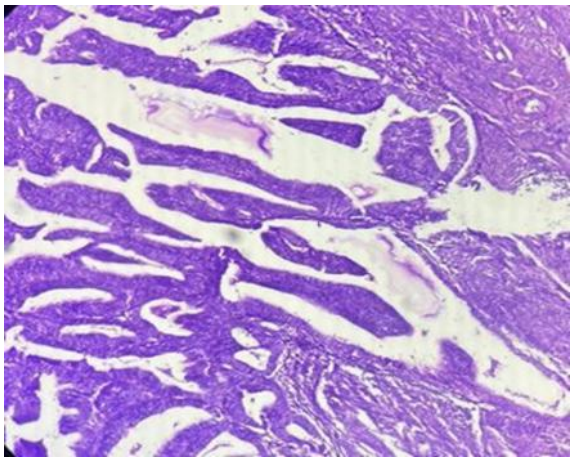

Figure 5: H and E (40x) of endometrial carcinoma showing hyperchromatic nuclei with prominent nucleoli and eosinophilic cytoplasm

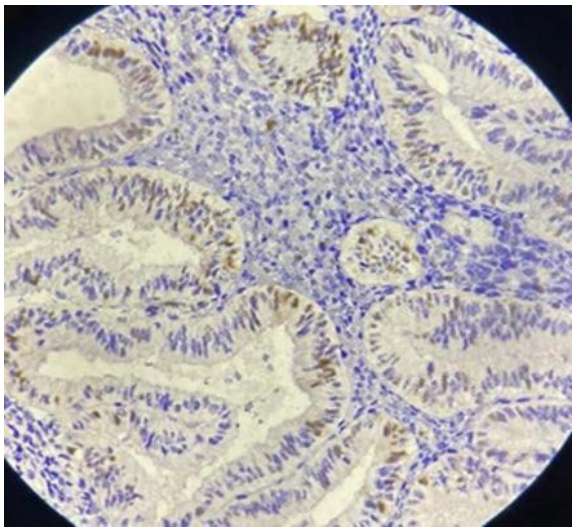

Figure 6: Endometrial hyperplasia without atypia showing weak expression of cyclin D1 with intensity +1 (40x)

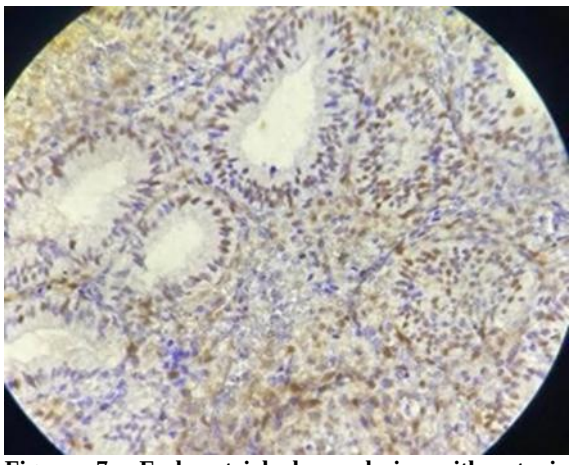

Figure 7: Endometrial hyperplasia with atypia showing moderate positivity of Cyclin D1 expression with intensity +2. (40X)

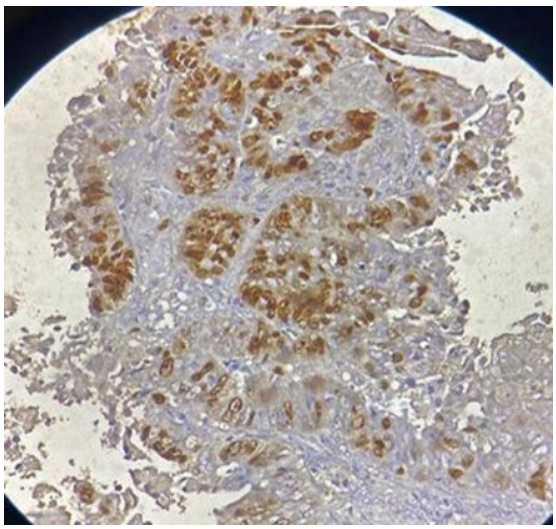

Figure 8: Endometrial carcinoma with strong cyclin d1 expression with intensity +3. (40x)

The predominance of cases in middle-aged women observed in this study correlates with previous studies that have reported higher occurrence of endometrial hyperplasia and carcinoma during the perimenopausal and early postmenopausal period. The findings emphasize the importance of careful clinical evaluation and histopathological examination in women presenting with abnormal uterine bleeding in this age group.

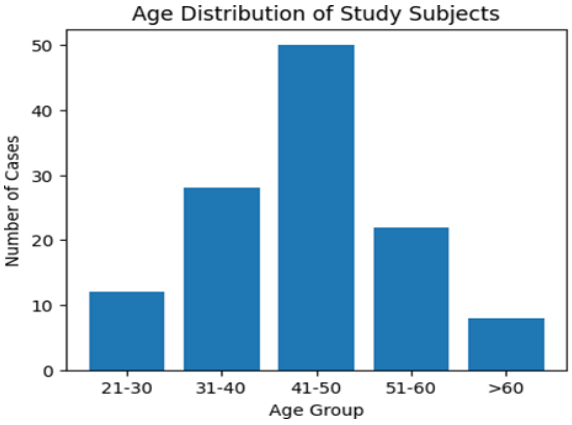

Table 2: Distribution of Endometrial Patterns

Endometrial Pattern	Cases	Percentage
Proliferative Endometrium	40	33.3
Hyperplasiawithout Atypia	35	29.2
Hyperplasia with Atypia	20	16.7
Endometrial Carcinoma	25	20.8

Among the various histopathological patterns observed in the study, proliferative endometrium was the most common finding, accounting for 33.3% of cases. This was followed by hyperplasia without atypia, which constituted 29.2% of cases. The predominance of proliferative endometrium indicates that a substantial number of patients presented with hormonally stimulated but non-neoplastic endometrial changes.

Hyperplasia with atypia represented 16.7% of cases and is considered a significant premalignant lesion because of its increased risk for progression to endometrial carcinoma. The presence of atypical hyperplasia in a considerable proportion of patients highlights the importance of early diagnosis and monitoring of these lesions.

Endometrial carcinoma accounted for 20.8% of the total cases included in the study. This relatively high proportion of malignant lesions reflects the clinical significance of abnormal endometrial proliferation and underscores the necessity of histopathological and immunohistochemical evaluation in suspected cases.

The sequential distribution from proliferative endometrium to hyperplasia and carcinoma observed in the present study supports the concept of stepwise progression of endometrial pathology. Persistent estrogenic stimulation without adequate progesterone opposition is believed to play a major role in this progression from benign proliferative lesions to premalignant and malignant conditions.

Table 3: Cyclin D1 Expression Pattern

Pattern	+1	+2	+3
Proliferative Endometrium	28	10	2
Hyperplasia without Atypia	10	20	5
Hyperplasia with Atypia	2	8	10
Endometrial Carcinoma	0	0	25

Cyclin D1 immunoexpression showed a progressive increase in intensity from proliferative endometrium to endometrial carcinoma. In proliferative endometrium, the majority of cases demonstrated weak positivity (+1), while only a small number of cases exhibited strong positivity (+3). This finding indicates low proliferative activity in normal proliferative endometrium.

In cases of hyperplasia without atypia, moderate positivity (+2) was the predominant pattern, suggesting increased cellular proliferation compared to normal endometrium. A smaller number of cases showed strong positivity, indicating gradual upregulation of Cyclin D1 expression during hyperplastic transformation.

Hyperplasia with atypia demonstrated markedly increased Cyclin D1 expression, with most cases exhibiting strong positivity (+3). This observation suggests that Cyclin D1 overexpression may be associated with the development of cytological atypia and increased malignant potential.

All cases of endometrial carcinoma showed intense (+3) Cyclin D1 positivity, while none exhibited weak or moderate staining. This finding strongly supports the role of Cyclin D1 in endometrial carcinogenesis. The progressive increase in Cyclin D1 expression from proliferative endometrium to atypical hyperplasia and carcinoma indicates that Cyclin D1 may serve as an important biomarker for disease progression and malignant transformation.

The findings of the present study are comparable with previous studies that reported increased Cyclin D1 expression in premalignant and malignant endometrial lesions. Overexpression of Cyclin D1 promotes cell cycle progression from G1 to S phase,thereby contributing to uncontrolled cellular proliferation and tumor development. Hence, Cyclin D1 immunohistochemistry may be useful as an adjunct diagnostic and prognostic marker in endometrial pathology.

DISCUSSION

Endometrial carcinoma represents one of the most significant gynecological malignancies and is frequently preceded by a spectrum of precursor lesions ranging from proliferative endometrium to endometrial hyperplasia without atypia, endometrial hyperplasia with atypia, and finally endometrial carcinoma.[16] The progression from benign endometrial proliferation to carcinoma is driven by persistent estrogenic stimulation, hormonal imbalance, and molecular alterations involving oncogenes and cell cycle regulatory proteins, particularly Cyclin D1.[17,18]The histopathological and immunohistochemical findings observed in the present study clearly demonstrate this sequential progression and correlate well with previously published literature.

The present study demonstrated that the highest number of cases occurred in the 41–50 years age

group (41.7%), followed by the 31–40 years age group (23.3%), indicating that endometrial lesions predominantly occur during the perimenopausal period. Similar observations were reported by Thukral et al. and Raffone et al., who attributed the increased incidence of endometrial hyperplasia and carcinoma during this age to prolonged estrogen exposure and anovulatory cycles.[19,20]

Histopathological evaluation revealed proliferative endometrium in 33.3% of cases, endometrial hyperplasia without atypia in 29.2%, endometrial hyperplasia with atypia in 16.7%, and endometrial carcinoma in 20.8% of cases. This distribution supports the concept of stepwise progression from benign proliferative endometrium to premalignant and malignant lesions, as described by Mutter et al. and the World Health Organization classification of endometrial intraepithelial neoplasia.[21,22]

The histopathological features observed in the present study further support this sequential progression. Figure 3 demonstrates Hematoxylin and Eosin stained section of endometrial hyperplasia with atypia (40×) showing loss of polarity, round to oval hyperchromatic nuclei,open chromatin, and prominent nucleoli, indicating significant cytological atypia and increased malignant potential. These microscopic findings correlate with the moderate Cyclin D1 positivity (intensity +2) demonstrated in endometrial hyperplasia with atypia (40×) in Figure 7, suggesting increased proliferative activity compared with benign lesions. Increased Cyclin D1 expression in atypical hyperplasia has been consistently associated with enhanced cellular proliferation and progression toward endometrial carcinoma.[23,25,26]

Similarly, Figure 1 shows Hematoxylin and Eosin stained section of endometrial hyperplasia without atypia (10×) demonstrating closely packed glands with increased glandular to stromal ratio and stromal breakdown, while Figure 2 shows Hematoxylin and Eosin stained section of endometrial hyperplasia without atypia (40×) revealing hyperchromasia of nuclei without significant cytological atypia. These morphological findings correspond with the weak Cyclin D1 expression (intensity +1) observed in endometrial hyperplasia without atypia (40×) in Figure 6, reflecting increased proliferative activity compared with proliferative endometrium but considerably lower expression than atypical hyperplasia and carcinoma. This gradual increase in Cyclin D1 expression supports the concept that cellular proliferative activity progressively increases with increasing severity of endometrial lesions.[23,26,27]

The malignant morphological features were evident in Figure 4, which demonstrates Hematoxylin and Eosin stained section of endometrial carcinoma (10×) showing papillary arrangement, while Figure 5 demonstrates Hematoxylin and Eosin stained section of endometrial carcinoma (40×) revealing hyperchromatic nuclei with prominent nucleoli and eosinophilic cytoplasm, confirming the diagnosis of endometrial carcinoma. These histopathological findings correlate with the strong Cyclin D1 expression (intensity +3) demonstrated in endometrial carcinoma (40×) in Figure 8, indicating markedly increased proliferative activity and malignant transformation. Similar observations have been reported by Balan et al., who demonstratedintense nuclear Cyclin D1 expression in endometrial carcinoma and concluded that Cyclin D1 plays an important role in tumor progression and aggressive biological behaviour.[24]

In contrast, Figure 9 demonstrates proliferative endometrium showing negative Cyclin D1 expression (40×), representing physiological proliferative endometrium without abnormal cellular proliferation. This finding further emphasizes the progressive increase in Cyclin D1 expression from proliferative endometrium through endometrial hyperplasia without atypia and endometrial hyperplasia with atypia to endometrial carcinoma. The sequential increase observed in the present study strongly supports the role of Cyclin D1 as a marker of endometrial carcinogenesis.[23]

The most significant finding of the present study was the progressive increase in Cyclin D1 expression across the spectrum of endometrial lesions. Proliferative endometrium demonstrated negative Cyclin D1 expression (Figure 9), endometrial hyperplasia without atypia demonstrated weak positivity with intensity +1 (Figure 1), endometrial hyperplasia with atypia demonstrated moderate positivity with intensity +2 (Figure 8), whereas endometrial carcinoma demonstrated strong positivity with intensity +3 (Figure 8). This progressive increase in immunohistochemical expression parallels the increasing severity of histopathological changes observed in Figures 2–6 and strongly supports the role of Cyclin D1 in endometrial carcinogenesis. Cyclin D1 facilitates progression of cells from the G1 phase to the S phase of the cell cycle, thereby promoting uncontrolled cellular proliferation and tumour development.[23]

The findings of the present study correlate well with previous studies conducted by Thukral et al., Shevra et al., and Raffone et al. Thukral et al. demonstrated significantly increased Cyclin D1 expression in atypical hyperplasia and endometrial carcinoma compared with proliferative endometrium.[25] Shevra et al. also reported progressive increase in Cyclin D1 immunoreactivity with increasing severity of endometrial lesions, suggesting its usefulness as a marker ofneoplastic progression.[26] Raffone et al., in a systematic review, concluded that Cyclin D1 overexpression is consistently associated with premalignant and malignant endometrial lesions and may assist in risk stratification of endometrial hyperplasia.[27]

Recent molecular studies have further strengthened the biological significance of Cyclin D1. Otto and Sicinski emphasized that Cyclin D1 and Cyclin-dependent kinase 4/Cyclin-dependent kinase 6

pathways represent important therapeutic targets in several malignancies.[28] Musgrove et al. also demonstrated that Cyclin D1 overexpression contributes not only to increased cellular proliferation but also to resistance to apoptosis and tumour progression.[29] These findings suggest that Cyclin D1 has both diagnostic and therapeutic significance in endometrial carcinoma.

The moderate Cyclin D1 positivity observed in endometrial hyperplasia with atypia (Figure 7) is particularly important because atypical hyperplasia is a well-recognized precursor of endometrial carcinoma. Likewise, the strong diffuse positivity observed in endometrial carcinoma (Figure 8) reflects increased proliferative activity and may correlate with aggressive biological behaviour. Therefore, immunohistochemical assessment of Cyclin D1, together with careful histopathological evaluation (Figures 2–6), may help identify high-risk lesions requiring closer clinical surveillance and appropriate therapeutic intervention.

Overall, the present study demonstrates a clear correlation between histopathological progression and Cyclin D1 immunoexpression. The sequential increase in Cyclin D1 expression from negative expression in proliferative endometrium, weak expression in endometrial hyperplasia without atypia (Figure 6), moderate expression in endometrial hyperplasia with atypia (Figure 7), and strong expression in endometrial carcinoma (Figure 8) supports its role as a valuable biomarker for distinguishing benign, premalignant, and malignant endometrial lesions. The corresponding histopathological findings observed in Figures 2–6 further validate this progression. Therefore, Cyclin D1 immunohistochemistry may contribute significantly to thediagnosis, prognostic assessment, and future targeted therapeutic strategies in endometrial carcinoma.[30]

CONCLUSION

Cyclin D1 expression increases progressively from proliferative endometrium to hyperplasia and carcinoma. Strong nuclear positivity in atypical hyperplasia and endometrial carcinoma indicates its significant role in endometrial carcinogenesis. Immunohistochemical evaluation of Cyclin D1 may aid in distinguishing premalignant and malignant endometrial lesions and may serve as a useful prognostic biomarker.

REFERENCES

1. Ferlay J, et al. Global cancer statistics 2021. CA Cancer J Clin. 2021.
2. Berek JS, Hacker NF. Berek and Hacker's Gynecologic Oncology. 7th ed.Wolters Kluwer; 2021.
3. Felix AS, Yang HP, Bell DW, Sherman ME. Epidemiology of endometrial carcinoma. Adv Exp Med Biol. 2022;943:3-46.
4. WHO Classification of Female Genital Tumours. 5th ed. IARC; 2020.
5. Mutter GL, Bergeron C, Deligdisch L, et al. Spectrum of endometrial hyperplasia and EIN. Mod Pathol. 2021;34:123-137.
6. Singh N, Hirschowitz L, Zaino R, et al. Pathologic prognostic factors in endometrial carcinoma. Int J Gynecol Pathol. 2021;40(S1):S93-S113.
7. Sherr CJ. D-type cyclins and cancer. Nat Rev Cancer. 2021;21(6):339-354.
8. Otto T, Sicinski P. Cell cycle proteins as therapeutic targets in cancer. Nat Rev Cancer. 2023;23(2):95-115.
9. Musgrove EA, Caldon CE, Barraclough J, Stone A, Sutherland RL. Cyclin D as a therapeutic target in cancer. Nat Rev Cancer. 2022;22(9):558-572.
10. Raffone A, Travaglino A, Saccone G, et al. Cyclin D1 expression in endometrial hyperplasia and carcinoma: A systematic review. Pathol Res Pract. 2022;238:154056.
11. Balan R, Cozaru GC, Georgescu CV, et al. Role of Cyclin D1 in endometrial carcinogenesis and tumor progression. Rom J Morphol Embryol. 2023;64(2):215-223.
12. Donnellan R, Chetty R. Cyclin D1 and human neoplasia. Mol Pathol. 1998.
13. Thukral S, Sharma ML, Kumar A, et al. Immunohistochemical expression of Cyclin D1 in endometrial lesions and carcinoma. J Obstet Gynecol India. 2021;71(4):401-408.
14. Shevra CR, et al. Cyclin D1 expression in endometrial pathology. Int J Res Med Sci. 2019.
15. Balan R, et al. Cyclin D1 expression in endometrial lesions. Rom J Morphol Embryol. 2017.
16. Kurman RJ, Carcangiu ML, Herrington CS, Young RH. WHO Classification of Tumours of Female Reproductive Organs. IARC; 2020.
17. Lax SF. Molecular genetic pathways in endometrial carcinoma. J Clin Pathol.2021.
18. Sherr CJ, Roberts JM. CDK inhibitors and cell cycle control. Genes Dev. 2021.
19. Thukral S, et al. Cyclin D1 immunoreactivity in endometrial lesions. J Obstet Gynecol India. 2021.
20. Raffone A, et al. Cyclin D1 in premalignant endometrial lesions. Pathol Res Pract., 2022.
21. Mutter GL, et al. Endometrial hyperplasia and carcinoma progression. Mod Pathol. 2021.
22. WHO Classification of Female Genital Tumours. 5th ed. IARC; 2020.
23. Sherr CJ. Cell cycle control and Cyclin D1 dysregulation. Nat Rev Cancer. 2021.
24. Balan R, Cozaru GC, Georgescu CV, et al. Cyclin D1 in endometrial carcinoma progression. Rom J Morphol Embryol. 2023.
25. Thukral S, Sharma ML, Kumar A, et al. Cyclin D1 in hyperplasia and carcinoma.J Obstet Gynecol India. 2021.
26. Shevra CR, et al. Cyclin D1 expression in endometrial pathology. Int J Res Med Sci. 2019.
27. Raffone A, Travaglino A, Saccone G, et al. Systematic review of Cyclin D1 in endometrial lesions. Pathol Res Pract. 2022.
28. Otto T, Sicinski P. CDK pathways in cancer therapy. Nat Rev Cancer. 2023.
29. Musgrove EA, et al. Cyclin D1 as a therapeutic target. Nat Rev Cancer. 2022.
30. Balan R, et al. Cyclin D1 and tumor progression in endometrial lesions. Rom J Morphol Embryol. 2023.