Section: Anatomy

Original Research Article

ANATOMICAL VARIATIONS IN THE ORIGIN AND BRANCHING PATTERNS OF THE DEEP FEMORAL ARTERY AND ITS CIRCUMFLEX BRANCHES IN HUMAN CADAVERS

Pradeep Bhatt[1], Bhavna N Jani[2]

[1]Post graduate, Shri M P Shah Government Medical College, Jamnagar, Gujarat, India.
[2]Consultant Obstetrics and Gynaecologist, Anuj Surgical and Maternity Hospital, Morbi, Gujarat, India.

Received *: 25/09/2026*
Received in revised form *: 23/10/2026*
Accepted *: 06/11/2026*

Corresponding Author:
Dr. Pradeep Bhatt,
Post graduate, Shri M P Shah Government Medical College, Jamnagar, Gujarat, India.
Email: drpradeep6598@gmail.com

DOI: 10.70034/ijmedph.2026.4.364

Source of Support: Nil,
Conflict of Interest: None declared

Int J Med Pub Health
2026; 16 (4); 2416-2419

ABSTRACT

Background: The profunda femoris artery (PFA) and its circumflex branches exhibit considerable anatomical variations. Knowledge of these variations is important for vascular interventions, orthopaedic procedures and reconstructive surgery. This study was aimed to study the anatomical variations in the origin, course and branching patterns of the PFA, medial circumflex femoral artery (MCFA) and lateral circumflex femoral artery (LCFA).

Materials and Methods: A descriptive cadaveric study consists twenty-four adult human cadavers (18 males and 6 females), aged 22-67 years, were included. Bilateral lower limbs were dissected, yielding 48 specimens. The origin, length and distance of the PFA from the mid-inguinal point, along with the origins and distances of the circumflex femoral arteries, were documented. Data were analysed using descriptive statistics.

Results: The posterolateral aspect was the predominant site of PFA origin, observed in 70.83% of right and 66.67% of left limbs. The PFA most frequently originated 31-40 mm from the mid-inguinal point (52.08%). Its length was predominantly 11-12 cm (52.08%). The MCFA originated from the PFA in 83.33% of limbs, whereas the corresponding proportion for the LCFA was 77.08%. Common-trunk, direct femoral and dual origins were also observed. The most frequent MCFA-PFA distance was 21-30 mm, while the LCFA-PFA distance was predominantly 11-20 mm.

Conclusion: The study demonstrates clinically relevant variations in femoral arterial anatomy. Awareness of these variations may assist in surgical planning and help reduce inadvertent vascular injury.

Keywords: Profunda femoris artery, medial circumflex femoral artery, lateral circumflex femoral artery, anatomical variations, cadaveric study.

INTRODUCTION

The profunda femoris artery (PFA), also known as the deep artery of the thigh, is the principal arterial supply to the muscles of the posterior and deep compartments of the thigh. It usually arises from the posterolateral aspect of the femoral artery, a short distance distal to the inguinal ligament, and gives rise to perforating branches and the medial and lateral circumflex femoral arteries. Variations in its origin, course and branching pattern are anatomically important because they may influence the safety and outcome of vascular, orthopaedic and reconstructive procedures.[1]

The medial circumflex femoral artery (MCFA) is particularly significant because it contributes substantially to the blood supply of the femoral head and neck through its retinacular branches. Consequently, variations in its origin or course may increase the risk of vascular injury during procedures such as hip arthroplasty, femoral neck fixation and proximal femoral surgery. The lateral circumflex femoral artery (LCFA), which supplies the anterior and lateral regions of the thigh, is also important in reconstructive surgery and the design of vascularised tissue flaps. Anatomical studies have demonstrated considerable variation in the origins of both circumflex arteries, including direct origin from the

femoral artery, common-trunk formation and other atypical patterns.[2-4]

Knowledge of the distance of the PFA origin from the mid-inguinal point, its length and the spatial relationship of the circumflex arteries is useful for surgical planning and femoral vascular interventions. However, reported frequencies of these variations differ across anatomical populations and studies.[5,6] Therefore, the present cadaveric study was undertaken to evaluate the origin, site of origin and length of the PFA, together with the origin patterns and distances of the MCFA and LCFA in 48 lower limbs obtained from 24 adult human cadavers.

MATERIALS AND METHODS

The present descriptive cadaveric study was conducted in the Departments of Anatomy at Shri M P Shah Government Medical College, Jamnagar from April 2024 to March 2026. The study included 24 adult human cadavers (18 males and 6 females), aged 22-67 years. Bilateral lower limbs were dissected, yielding a total of 48 specimens (24 right and 24 left limbs). The study protocol was approved by the institutional ethics committee. The cadavers with previous femoral surgery, traumatic injury, and gross pathological changes were excluded.

The femoral triangle was dissected following standard anatomical procedures described in Cunningham's Manual of Practical Anatomy. A transverse incision was made between the anterior superior iliac spine and pubic tubercle, followed by a vertical incision extending from the midpoint of the transverse incision towards the upper third of the thigh. The skin and superficial fascia were reflected, and the sartorius and adductor longus muscles were identified and retracted to expose the femoral sheath. The femoral artery, femoral vein and profunda femoris artery (PFA) were subsequently identified and carefully dissected to expose their branches.

The anatomical parameters recorded included the source and site of origin, course and branching pattern of the PFA, medial circumflex femoral artery (MCFA) and lateral circumflex femoral artery (LCFA). The site of origin of the PFA was classified as posterolateral, posteromedial, posterior or lateral in relation to the femoral artery. The distance between the mid-inguinal point and the origin of the PFA, as well as the total length of the PFA, was documented. The origins of the MCFA and LCFA were classified according to their source, including direct origin from the PFA, independent origin from the femoral artery, common trunk formation, dual origin and absence. The distances between the origins of the circumflex arteries and the PFA were also recorded.

All anatomical measurements were obtained using a transparent measuring scale or thread and documented separately for the right and left lower limbs. Representative anatomical variations were photographed for documentation.

Statistical analysis: The observations were extracted to Microsoft Excel sheet and analysed using SPSS v.26.0. Using descriptive statistics, categorical variables were expressed as frequencies and percentages, with findings presented separately for the right and left lower limbs.

RESULTS

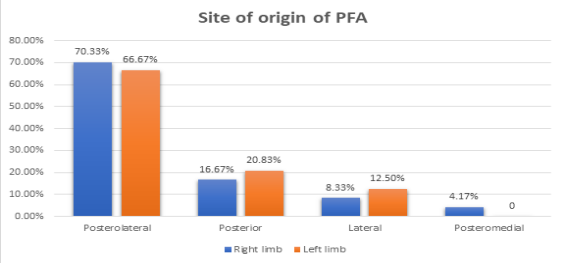

Figure 1: Side-wise distribution of the site of origin of PFA

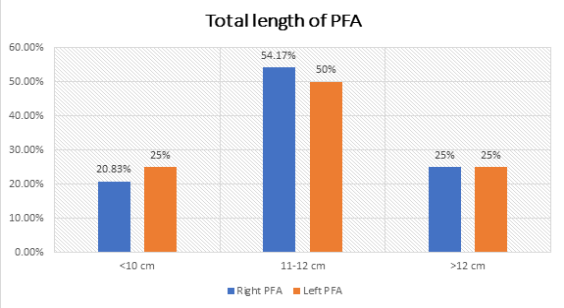

Figure 2: Distribution according to total length of PFA

Table 1: Demographic characteristics.

Characteristic	Number	Percentage
Cadavers	24	100%
Male cadavers	18	75%
Female cadavers	6	25%
Age (mean ± SD)	45.8 ± 14.0	
Age range (years)	22-67	
Right lower limbs	24	50%
Left lower limbs	24	50%
Total lower limbs	48	100%

Table 2: Distance between the mid-inguinal point and origin of PFA

Distance (mm)	Right side	Left side	Total
	Number (%)	Number (%)	Number (%)
Less than 10	1 (4.17)	2 (8.33%)	3 (6.25%)
11-20	3 (12.5%)	4 (16.67%)	7 (14.58%)

21-30	2 (8.33%)	3 (12.5%)	5 (10.42%)
31-40	12 (50%)	13 (54.17%)	25 (52.08%)
41-50	5 (20.83%)	2 (8.33%)	7 (14.58%)
> 50	1 (4.17%)	0	1 (2.08%)
Total	24 (100%)	24 (100)	48 (100%)

Table 3: Source of origin of medial circumflex femoral artery.

Origin	Right side	Left side
	Number (%)	Number (%)
PFA	19 (79.17%)	21 (87.5%)
Common trunk from FA	2 (8.33%)	2 (8.33%)
Direct from FA	2 (8.33%)	1 (4.17%)
Dual origin	1 (4.17%)	0
Total	24 (100%)	24 (100%)

Table 4: Source of origin of lateral circumflex femoral artery.

Origin	Right side	Left side
	Number (%)	Number (%)
PFA	18 (75%)	19 (79.17%)
Common trunk from FA	3 (12.5%)	2 (8.33%)
Direct from FA	2 (8.33%)	1 (4.17%)
Dual origin	1 (4.17%)	1 (4.17%)
Absent	0	1 (4.17%)
Total	24 (100%)	24 (100%)

Table 5: Distance between origin of MCFA and LCFA with PFA.

Side of limb	Distance from origin to PFA (In mm)			
	<10	11-20	21-30	>30
Medial circumflex femoral artery VS PFA				
Right limb	1 (4.17%)	10 (41.67%)	13 (54.17%)	0
Left limb	0	7 (29.17%)	16 (66.67%)	1 (4.17%)
Lateral circumflex femoral artery VS PFA				
Right limb	3 (12.5%)	17 (70.83%)	3 (12.50%)	1 (4.17%)
Left limb	0	19 (79.17%)	3 (12.50%)	2 (8.33%)

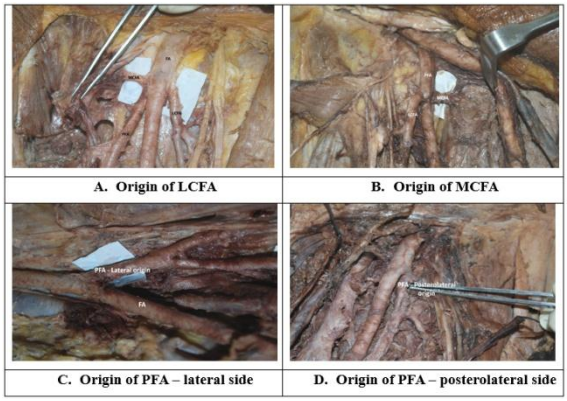

Figure 1: Origin of PFA and source of origin of MCFA and LCFA.

DISCUSSION

The present cadaveric study evaluated the anatomical variations in the origin, length and branching pattern of the profunda femoris artery (PFA), together with the origins and topographical relationships of the medial and lateral circumflex femoral arteries (MCFA and LCFA). The study included 24 adult cadavers (48 lower limbs), comprising 18 male and 6 female cadavers, with a mean age of 45.8±14.0 years. The principal finding was the predominance of a posterolateral origin of the PFA, observed in approximately two-thirds of the specimens. The PFA most frequently originated 31-40 mm from the mid-inguinal point, while the MCFA and LCFA most commonly arose from the PFA. These findings are clinically relevant because the femoral arterial branching pattern is important during vascular access, catheterisation, reconstructive procedures, orthopaedic surgery around the proximal femur and management of traumatic injuries.

The present study demonstrated that the PFA most frequently originated from the posterolateral aspect of the femoral artery, accounting for 70.83% of right and 66.67% of left limbs. Posterior origin was the second most frequent pattern, followed by lateral origin; posteromedial origin was uncommon and was not observed on the left side. This distribution is broadly consistent with the findings of George and Santhakumary, who reported posterolateral origin in 63.3% of specimens from a South Indian population. Manjappa and Prasanna also documented posterolateral origin as the predominant pattern, particularly on the left side.[4,7] Nasr et al., however, reported a lower frequency of posterolateral origin (approximately 42%), with posterior, lateral and posteromedial origins also represented.[3] Such differences may reflect population variation, sample size, classification criteria and dissection methodology. The meta-analysis by Tomaszewski et al. further established that the origin of the deep femoral artery is variable, identifying posterior origin as the most frequent pooled pattern (38.8%).[8]

In present study, the distance between the mid-inguinal point and PFA origin was most frequently 31-40 mm, observed in 52.08% of limbs. This is

comparable with the findings of Manjappa and Prasanna, who reported a mean distance of approximately 3.56 cm, and Prakash et al., who documented a median distance of 4.2 cm.[4,7] Tomaszewski et al. reported a pooled mean distance of 41.15mm, providing further support for the observation that the PFA commonly originates around 4cm distal to the mid-inguinal point.[8] These findings are clinically relevant because the level of PFA origin may influence femoral arterial access, catheter placement and surgical exposure in the femoral triangle. The PFA length was most commonly within the 11-12 cm category in the present study. Since comparable length measurements were not consistently available in the cited studies, direct numerical comparison is limited.

The MCFA arose from the PFA in 79.17% of right and 87.5% of left limbs, giving an overall frequency of 83.33%. This is higher than the pooled prevalence of 64.6% reported by Tomaszewski et al. in their meta-analysis of 4,351 lower limbs.[5] Prakash et al. reported PFA origin in 67.2% of limbs, while Manjappa and Prasanna described considerable side-wise variation.[4,7] In the present study, the remaining patterns included common-trunk and direct femoral artery origins, with one instance of dual origin. These variations are important because the MCFA contributes substantially to the vascular supply of the femoral head; unexpected origin or course may increase the risk of vascular injury during hip surgery and proximal femoral procedures.

The LCFA originated from the PFA in 75% of right and 79.17% of left limbs (77.08% overall). This finding is comparable with Prakash et al., who reported PFA origin in 81.25% of limbs, and with the South Indian observations of Manjappa and Prasanna.[4,7] Nevertheless, Ma et al. demonstrated substantial diversity in LCFA origin and branching patterns, emphasising the need to recognise variant anatomy during vascular reconstruction and surgical flap procedures.[6] The present study also identified common-trunk, direct femoral, dual-origin and absent patterns, reinforcing that the usual PFA-derived configuration cannot be assumed in every patient.

The MCFA-PFA distance was most frequently 21-30 mm (60.42%), whereas the LCFA-PFA distance was most commonly 11-20 mm (75%). Nasr et al. reported mean distances of approximately 18-23 mm for the circumflex arteries, broadly supporting the close relationship between their origins and the PFA. These measurements may assist anatomical orientation during dissection and operative procedures.[3,9] Overall, the findings demonstrate clinically relevant variability in the PFA and its circumflex branches. However, the modest sample size and descriptive design limit generalisation; larger studies using standardised continuous measurements and imaging correlation would provide stronger evidence.

CONCLUSION

The present cadaveric study demonstrates considerable anatomical variation in the origin and branching patterns of the profunda femoris artery and its circumflex branches. The posterolateral aspect was the predominant site of PFA origin, most commonly located 31-40 mm from the mid-inguinal point. The MCFA and LCFA predominantly originated from the PFA, although variations such as direct femoral origin, common trunks, dual origins and absence were observed. These findings highlight the importance of detailed knowledge of femoral arterial anatomy for vascular interventions, orthopaedic procedures and reconstructive surgery. Awareness of these variations may help minimise inadvertent vascular injury and improve surgical planning.

REFERENCES

1. Ariyanachi K, Motwani R, Chandrupatla M. Unilateral Anomalous Profunda Femoris Artery: An Anatomical Variation of Clinical Significance. Cureus. 2022;14(12):e32188.
2. Prakash, Kumari J, Kumar Bhardwaj A, Jose BA, Kumar Yadav S, Singh G. Variations in the origins of the profunda femoris, medial and lateral femoral circumflex arteries: a cadaver study in the Indian population. Rom J Morphol Embryol. 2010;51(1):167-70.
3. Nasr AY, Badawoud MH, Al-Hayani AA, Hussein AM. Origin of profunda femoris artery and its circumflex femoral branches: anatomical variations and clinical significance. Folia Morphol (Warsz). 2014;73(1):58-67.
4. Manjappa T, Prasanna LC. Anatomical variations of the profunda femoris artery and its branches-a cadaveric study in South Indian population. Indian J Surg. 2014;76(4):288-92.
5. Tomaszewski KA, Henry BM, Vikse J, Roy J, Pękala PA, Svensen M, Guay DL, Saganiak K, Walocha JA. The origin of the medial circumflex femoral artery: a meta-analysis and proposal of a new classification system. PeerJ. 2016;4: e1726.
6. Ma M, Sang H, Ye Y, Zhuang H, Zhuang Z, Qiu Y, et al. An analysis of the variations and clinical applications of the lateral circumflex femoral artery. Folia Morphol (Warsz). 2021;80(3):557-66.
7. George A, Santhakumary MT. A cadaveric study on the variations of the profunda femoris artery in South India. Asian J Med Sci. 2021;12(2):86-90.
8. Tomaszewski KA, Henry BM, Vikse J, Pękala P, Roy J, Svensen M, Guay D, Hsieh WC, Loukas M, Walocha JA. Variations in the origin of the deep femoral artery: A meta-analysis. Clin Anat. 2017;30(1):106-113.
9. Tomaszewski KA, Vikse J, Henry BM et al. The variable origin of the lateral circumflex femoral artery: a meta-analysis and proposal for a new classification system. Folia Morphologica. 2017;76(2):157-167.