Section: Plastic and Reconstructive Surgery

Original Research Article

EVALUATION OF OUTCOMES OF USING AUTOGENOUS ILIAC CREST BONE GRAFT FOR ORBITAL FLOOR FRACTURES IN A MEDICAL COLLEGE OF KOLKATA

Dipraswatta Mahapatra[1], Nipen Kumar Saha[2], Shreya Sarkar[3], Rup Narayan Bhattacharya[4]

[1]3rd YearPost-Doctoral Trainee, Department of Plastic and Reconstructive Surgery, R. G. Kar Medical College and Hospital, Kolkata, West Bengal, India.
[2]3rd YearPost-Doctoral Trainee, Department of Plastic and Reconstructive Surgery, R. G. Kar Medical College and Hospital, Kolkata, West Bengal, India.
[3]Senior Resident, MCh, Department of Plastic and Reconstructive Surgery, R. G. Kar Medical College and Hospital, Kolkata, West Bengal, India.
[4]Professor and HOD, Department of Plastic and Reconstructive Surgery, R. G. Kar Medical College and Hospital, Kolkata, West Bengal, India.

Received *: 06/10/2026*
Received in revised form *: 03/11/2026*
Accepted *: 16/11/2026*

Corresponding Author:
Dr.Shreya Sarkar,
Senior Resident, MCh, Department of Plastic and Reconstructive Surgery, R. G. Kar Medical College and Hospital, Kolkata, West Bengal, India.
Email: drshreyasarkar2009@gmail.com

DOI:10.70034/ijmedph.2026.4.358

Source of Support: Nil,
Conflict of Interest: Nonedeclared

Int J Med Pub Health
2026; 16 (4); 2380-2385

ABSTRACT

Background: Orbital floor fractures are common maxillofacial injuries causing functional and aesthetic disturbances. Reconstruction restores orbital volume and ocular position. Autogenous iliac crest bone offers easy harvesting and adaptability. This study evaluates clinical and CT-based volumetric outcomes following iliac crest bone grafting within 14 days of injury.

Aims: To evaluate the outcomes of autogenous iliac crest cortical bone grafting for symptomatic orbital blowout fractures, including correction of diplopia and enophthalmos, orbital volume restoration on CT, and postoperative recipient- and donor-site outcomes.

Materials and Methods: The present study was a prospective observational study. This Study was conducted from August, 2024 to January, 2026 (18 months). Department of Plastic and Reconstructive Surgery, R. G. Kar Medical College and Hospital, Kolkata. Study population 15.

Results: Among 15 patients, all were male, with most aged 21–30 years (53.3%) and injured in road traffic accidents. Diplopia decreased from 46.7% preoperatively to 6.7% at 3 months, while enophthalmos resolved in all patients. Infraorbital nerve paraesthesia decreased from 93.3% to 13.3%, and eyeball movement restriction resolved completely. Donor-site complications were absent in 80.0%. Mean orbital volume discrepancy decreased from 3.060000 ± .9068706 to .850667 ± .3567205.

Conclusion: Autogenous iliac crest cortical bone grafting achieved satisfactory functional and morphological outcomes in orbital floor fractures. Complete resolution of enophthalmos and marked improvement in diplopia, paraesthesia, and ocular motility occurred by three months, with restored orbital volume, satisfactory graft integration, and minimal donor-site morbidity.

Keywords: Autogenous iliac crest bone graft; Orbital floor fracture; Orbital reconstruction; Enophthalmos; Diplopia.

INTRODUCTION

Possibly no other area of the face other than the eyes is under such constant dynamic and social scrutiny, as they are the first to gain attention in the face and remain the focus of the onlooker. The face, being an anatomically and functionally complex area has to be reconstructed most physiologically and aesthetically following trauma or ablation. Maxillofacial trauma has become the commonly reported casualty in our country due to the rising rate of road traffic accidents and acts of interpersonal violence. Orbital fractures represent one of the most common conditions encountered in maxillofacial trauma, whether a

blowout fracture or as part of complex fractures. Though the first recorded description of a case of orbital blowout with enophthalmos was made by Lang in 1889, the term "Blowout fracture" was coined by Smith and Regan in 1957.[1] Smith describes the term as a "fracture of the floor of the orbit which may be accompanied by displacement of the orbital contents into the maxillary sinus". In 1960, Converse and Smith introduced the concept of Pure and Impure Blowout fracture,[2] based on the association of rim fracture. Orbital floor is a common injury accompanying mid-face trauma. Its incidence ranges from 18 to 50% of all cranio-maxillofacial traumas, depending on the geographic region, injury mechanism, and study population. Blowout fracture results in aesthetic deficits including enophthalmos, hypoglobus, dystopia and functional deficits including diplopia, restricted ocular movements and Infraorbital nerve paraesthesia.[3] Failure to prompt recognition and treatment of these injuries may result in significant functional and cosmetic problems. The goals of reconstruction of fractures of the orbital floor are to free the incarcerated or prolapsed orbital tissue from the fracture defect and to span the defect with an implant to recover the volume of the orbital cavity and rectify the position of the eyeball.[4] Numerous materials have been tried including autogenous, alloplastic and allogenic materials but with none fulfilling all the ideal properties. Various authors have advocated the use of autogenous grafts from sites such as the Calvarium, Auricular cartilage, Nasoseptal, cartilage, anterior wall of the maxillary sinus, Contralateral Coronoid Process, Mandibular symphysis, Rib, and Ilium. The choice of the graft depends on the size of the defect, location of the defect, curvature of orbit in the region, condition of lining sinus, and donor site preference.[5] Iliac bone is comparable to Calvarial bone in the immediate and secondary repair of orbital wall deformities following blowout fracture. The Iliac bone is easy to harvest, and the medial cortex of the anterior iliac crest is relatively easy to shape to fit the internal orbital wall.[6] Few studies are available concerning immediate reconstruction with iliac bone according to which good aesthetic and functional outcomes can be achieved.[7,6] This prospective observational study intends to evaluate the efficacy of an iliac bone graft in restoring the orbital floor defect in an orbital blowout. Also, the volumetric correction of the orbital defect using nonvascularizedautogenous iliac crest bone grafts both pre and post-operatively are compared using computed tomography. Understanding the outcomes of using iliac crest bone grafting within 14 days of injury for orbital floor fractures in a tertiary care center has not been conducted in sufficient numbers for improving the management of these injuries as well as optimizing patient outcomes in terms of quality of life and overall health.

MATERIALS AND METHODS

Study design: This is a prospective observational study.

Place of study: Department of Plastic and Reconstructive Surgery, R. G. Kar Medical College and Hospital, Kolkata.

Period of study: From August, 2024 to January, 2026 (18 months).

Study Population: All the patients both male and female of age group 13-70 years attending with orbital floor fractures in trauma emergency or in OPD of Plastic and reconstructive surgery of R. G. Kar Medical College and Hospital, Kolkata during the period of study after applying inclusion and exclusion criteria.

Sample size: 15 patients.

Inclusion Criteria

Patients both male and female of age group between 13-70 years attending trauma emergency or plastic and reconstructive surgery OPD with displaced orbital floor fractures with/or

- Enophthalmos
- Hypoglobus
- Diplopia
- Radiological evidence of orbital content herniation in floor defect
- Mechanical restriction in ocular motility (Forced Duction Test positive)
- Presentation up to 14 days from the date of the injury.

Exclusion Criteria

- Patients with associated head injury
- Optic neuropathy/post-trauma blindness
- Globe perforation/retinal detachment
- Extensive soft tissue injury and local sepsis
- Patients of the age group of less than 13 years.

Study Variable:

- **Demographic variables:** Age and sex.
- **Clinical variables:** Diplopia, enophthalmos, ocular movement, and infraorbital nerve sensation.
- **Radiological variables:** Preoperative and postoperative orbital volume assessed by computed tomography.
- **Outcome variables:** Recipient-site and donor-site complications and overall postoperative functional and aesthetic outcomes.

Statistical Analysis: For statistical analysis, data were initially entered into a Microsoft Excel spreadsheet and then analyzed using SPSS (version 27.0; SPSS Inc., Chicago, IL, USA) and GraphPad Prism (version 5). Numerical variables were summarized using means and standard deviations, while Data were entered into Excel and analyzed using SPSS and GraphPad Prism. Numerical variables were summarized using means and standard deviations, while categorical variables were described with counts and percentages. Two-sample t-tests were used to compare independent groups, while paired t-tests accounted for correlations in

paired data. Chi-square tests (including Fisher's exact test for small sample sizes) were used for categorical data comparisons. P-values ≤ 0.05 were considered statistically significant.

Image Gallery

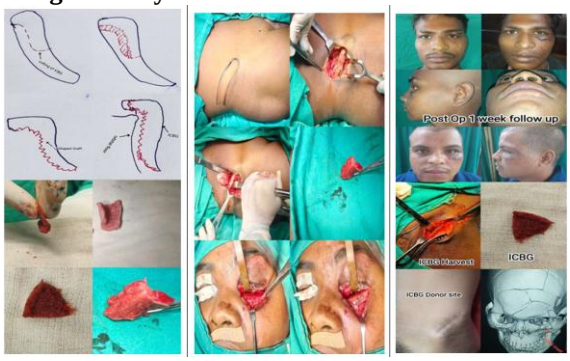



RESULTS

Table 1: Demographic characteristics, mechanism of injury and treatment profile of study participants (N=15)

Variable	Category	Frequency (n)	Percent (%)
Sex	Male	15	100
Mechanism of injury	RTA	12	—
	IPV	3	—
Age group (years)	≤20	2	13.3
	21–30	8	53.3
	31–40	5	33.3
Treatment	LT FLR WITH ICBG	4	26.7
	LT FLR WITH ICBG, ORIF FOR ZMC#	3	20
	RT FLR WITH ICBG	4	26.7
	RT FLR WITH ICBG, ORIF FOR ZMC#	4	26.7

Table 2: Preoperative and postoperative status of diplopia (N=15)

Assessment	Category	Frequency (n)	Percent (%)
Diplopia – Preoperative	Absent	8	53.3
	Present	7	46.7
Diplopia – Postoperative 1 week	Absent	8	53.3
	Present	7	46.7
Diplopia – Postoperative 1 month	Absent	9	60
	Present	6	40
Diplopia – Postoperative 3 months	Absent	14	93.3
	Present	1	6.7

Table 3: Preoperative and postoperative status of enophthalmos (N=15)

Assessment	Category	Frequency (n)	Percent (%)
Enophthalmos – Preoperative	Present	15	100
Enophthalmos – Postoperative 1 week	Present	15	100
Enophthalmos – Postoperative 1 month	Absent	9	60
	Present	6	40
Enophthalmos – Postoperative 3 months	Absent	15	100

Table 4: Preoperative and postoperative infraorbital nerve paraesthesia and eyeball movement restriction (N=15)

Variable	Assessment	Category	Frequency (n)	Percent (%)
ION Paraesthesia	Preoperative	Absent	1	6.7
		Present	14	93.3
	Postoperative 1 week	Absent	1	6.7
		Present	14	93.3
	Postoperative 1 month	Absent	6	40
		Present	9	60
	Postoperative 3 months	Absent	13	86.7
		Present	2	13.3
Eyeball movement restriction	Preoperative	Absent	8	53.3
		Present	7	46.7
	Postoperative 1 week	Absent	8	53.3
		Present	7	46.7
	Postoperative 1 month	Absent	10	66.7

		Present	5	33.3
	Postoperative 3 months	Absent	15	100

Table 5: Graft donor-site complications following iliac crest bone graft harvesting (N=15)

Donor-site complication	Frequency (n)	Percent (%)
Elevated scar	1	6.7
Mild pain	2	13.3
Nil	12	80
Total	**15**	**100**

Table 6: Clinical and radiological characteristics of the study participants

Parameter	Mean ± SD
Age (Years)	27.73 ± 5.431
Defect Size (cm × cm)	2.13 ± .352
Unaffected Side OV	25.47 ± 2.295
Affected Side Pre OP OV	28.773333 ± 2.5869719
Affected Side OV 3 month-Post OP	26.5133 ± 2.09590
OV Change Pre OP	3.060000 ± .9068706
OV Change 3 Month-Post OP	.850667 ± .3567205
Graft Density (HU)	1087.27 ± 138.113

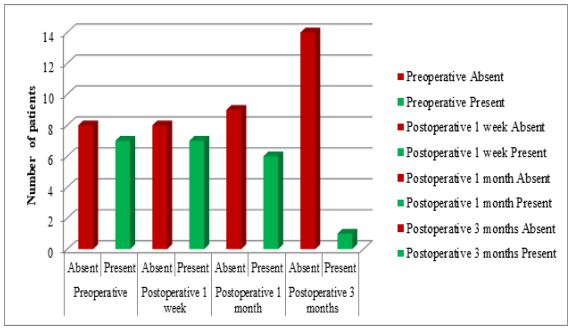

Figure 1: Preoperative and postoperative status of diplopia (N=15)

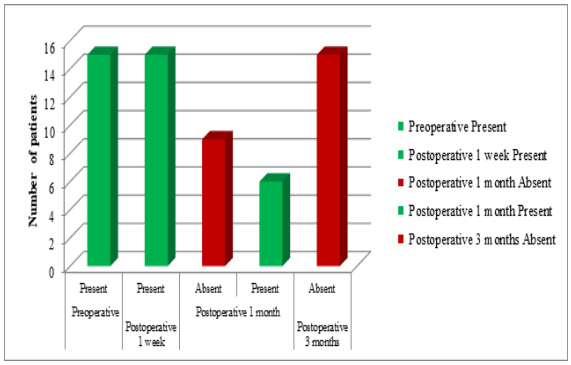

Figure 2: Preoperative and postoperative status of enophthalmos (N=15)

Table 1 shows the demographic characteristics, mechanism of injury and treatment profile of the 15 study patients. All patients were male (15, 100.0%). Road traffic accidents accounted for 12 cases, while 3 cases were due to interpersonal violence. The majority of patients were aged 21–30 years (8, 53.3%), followed by 31–40 years (5, 33.3%) and ≤20 years (2, 13.3%). Regarding treatment, 4 (26.7%) underwent left floor reconstruction with iliac crest bone graft, 3 (20.0%) underwent left floor reconstruction with iliac crest bone graft along with ORIF for ZMC fracture, while 4 (26.7%) each underwent right floor reconstruction with iliac crest bone graft and right floor reconstruction with iliac crest bone graft along with ORIF for ZMC fracture.

Table 2 demonstrates the postoperative changes in diplopia among the 15 patients. Preoperatively, diplopia was absent in 8 (53.3%) patients and present in 7 (46.7%). At 1 week postoperatively, the distribution remained unchanged, with 8 (53.3%) patients without diplopia and 7 (46.7%) with diplopia. At 1 month, 9 (60.0%) patients had no diplopia, while 6 (40.0%) continued to have diplopia. By 3 months, absence of diplopia was observed in 14 (93.3%) patients, while only 1 (6.7%) had persistent diplopia.

Table 3 shows the changes in enophthalmos following orbital floor reconstruction. Preoperatively, enophthalmos was present in all 15 (100.0%) patients. At 1 week postoperatively, enophthalmos remained present in all 15 (100.0%) patients. At 1 month, enophthalmos was absent in 9 (60.0%) patients and remained present in 6 (40.0%). By 3 months postoperatively, enophthalmos was absent in all 15 (100.0%) patients.

Table 4 presents the postoperative changes in infraorbital nerve paraesthesia and eyeball movement restriction. Preoperatively, infraorbital nerve paraesthesia was present in 14 (93.3%) patients and absent in 1 (6.7%). The same distribution was observed at 1 week postoperatively. At 1 month, paraesthesia was absent in 6 (40.0%) and present in 9 (60.0%), while at 3 months it was absent in 13 (86.7%) and present in 2 (13.3%). Regarding eyeball movement restriction, it was present in 7 (46.7%) patients preoperatively and at 1 week. At 1 month, it was present in 5 (33.3%), whereas by 3 months, all 15 (100.0%) patients had no restriction.

Table 5 describes donor-site complications following iliac crest bone graft harvesting. Most patients, 12 (80.0%), had no donor-site complication. Mild pain was reported in 2 (13.3%) patients, while an elevated scar was observed in 1 (6.7%) patient. Thus, the majority of patients had no documented donor-site complication.

Table 6 presents the clinical and radiological characteristics of the study patients. The mean age was 27.73 ± 5.431 years and the mean defect size was

2.13 ± .352 cm × cm. The mean orbital volume of the unaffected side was 25.47 ± 2.295, while the affected side preoperative orbital volume was 28.773333 ± 2.5869719. At 3 months postoperatively, the mean affected-side orbital volume was 26.5133 ± 2.09590. The mean orbital volume change decreased from 3.060000 ± .9068706 preoperatively to .850667 ± .3567205 at 3 months postoperatively. The mean graft density was 1087.27 ± 138.113 HU.

DISCUSSION

In the present study, all 15 participants were male (100.0%), with the majority belonging to the 21–30-year age group (53.3%). Road traffic accidents constituted the major mechanism of injury, accounting for 12 cases, while 3 cases were due to interpersonal violence. Similar patterns have been reported in previous studies, where road traffic accidents and interpersonal violence were important causes of orbital and maxillofacial trauma. A study by Alasady MS et al. involving 15 patients with orbital floor fractures also evaluated early reconstruction using autogenous anterior iliac crest bone grafts, providing a particularly comparable study population to the present study.[7] Other studies have similarly reported a predominance of young adult males among patients undergoing orbital floor reconstruction Ram et al. and Zunz et al.[8,9]

In the present study, diplopia was present preoperatively in 7 (46.7%) patients. At 1 week postoperatively, the proportion remained unchanged, with diplopia present in 7 (46.7%) patients. At 1 month, diplopia was present in 6 (40.0%) patients, while by 3 months it was present in only 1 (6.7%) patient. Thus, a marked improvement in diplopia was observed during follow-up. Alasady MS et al. reported postoperative diplopia in 13.3% of patients following reconstruction with anterior iliac crest bone graft, which is comparable to the low rate observed in the present study at 3 months.[7] Dubois et al. in a prospective study of 24 patients reconstructed using iliac crest bone grafts, reported that diplopia present in the central field preoperatively was absent at the final follow-up.[10] Similarly, Harish et al. reported satisfactory correction of diplopia following reconstruction with thin autogenous iliac cancellous bone grafts.[11] These findings support the functional effectiveness of iliac bone grafting in restoring the orbital floor and improving ocular motility.

Enophthalmos was present in all 15 (100.0%) patients preoperatively and remained present in all patients at 1 week. At 1 month, it was absent in 9 (60.0%) patients and present in 6 (40.0%), whereas at 3 months, all 15 (100.0%) patients had no enophthalmos. Alasady MS et al. reported postoperative enophthalmos in only 6.7% of patients after iliac bone graft reconstruction.[7] In another retrospective study involving 20 patients treated with autogenous iliac crest bone grafts, only one patient developed postoperative enophthalmos O'Connell et al.[12]Dubois et al. also reported that only one patient had persistent enophthalmos at final follow-up following iliac crest reconstruction.[10] The complete absence of enophthalmos at 3 months in the present study therefore indicates satisfactory restoration of orbital contour and volume.

The present study also demonstrated progressive improvement in infraorbital nerve paraesthesia. Preoperatively, paraesthesia was present in 14 (93.3%) patients. The same proportion remained at 1 week, but improvement was observed subsequently, with paraesthesia present in 9 (60.0%) patients at 1 month and only 2 (13.3%) patients at 3 months. This progressive recovery is consistent with the natural recovery of infraorbital nerve function following decompression and stabilization of the orbital floor. Studies evaluating iliac crest graft reconstruction have similarly documented low rates of persistent postoperative sensory complications Garg et al.[13]

Eyeball movement restriction was present in 7 (46.7%) patients preoperatively and remained present in 7 (46.7%) patients at 1 week. At 1 month, restriction was present in 5 (33.3%) patients, while at 3 months, none of the 15 (100.0%) patients had persistent eyeball movement restriction. In a comparative study of iliac crest and mandibular bone grafts, correction of restricted ocular movement was achieved in all patients in the iliac crest group Garg et al.[13] Dubois et al. similarly demonstrated good restoration of ocular function following iliac crest reconstruction.[10] The complete resolution of movement restriction at 3 months in the present study is therefore consistent with these previous observations.

Regarding donor-site morbidity, 12 (80.0%) patients had no donor-site complication. Mild pain was reported in 2 (13.3%) patients, while an elevated scar was observed in 1 (6.7%) patient. Alasady MS et al. reported limited donor-site morbidity, with pain and gait disturbance occurring in individual patients and resolving within 1 month.[7] A retrospective study of 20 patients by O'Connell et al. reported no significant donor-site morbidity following iliac crest harvesting.[12] More recent CT-based research has also described minimal donor-site complications, with scarring being the most frequently noted issue Strabbing et al.[14]The low frequency of complications in the present study indicates acceptable morbidity associated with iliac crest harvesting.

The CT-based analysis in the present study demonstrated a mean unaffected-side orbital volume of 25.47 ± 2.295, compared with a mean affected-side preoperative orbital volume of 28.773333 ± 2.5869719. At 3 months postoperatively, the mean affected-side orbital volume decreased to 26.5133 ± 2.09590. The mean orbital volume change was 3.060000 ± .9068706 preoperatively and .850667 ± .3567205 at 3 months postoperatively. These findings indicate substantial correction of the preoperative orbital volume discrepancy following reconstruction.

Anitha et al. specifically used CT-based volumetric assessment to evaluate orbital reconstruction with iliac bone graft and reported satisfactory radiological outcomes.[15] Kumar et al. also emphasized the importance of CT assessment for evaluating graft position, orbital volume, and postoperative remodeling.[16]

The mean graft density in the present study was 1087.27 ± 138.113 HU, with values ranging from 876 to 1347 HU. The radiological findings are relevant because the stability and remodeling characteristics of autogenous iliac bone influence long-term orbital reconstruction. Recent research evaluating iliac crest grafts with CT demonstrated substantial graft remodeling and resorption over time, while clinical outcomes remained satisfactory, with no clinically relevant enophthalmos or diplopia despite graft volume reduction Strabbing et al.[14]This suggests that radiological graft remodeling does not necessarily translate into poor clinical outcomes.

CONCLUSION

We concluded that the autogenous iliac crest bone graft method of orbital floor repair was very successful in restoring both morphological and functional results. By three months, all patients had fully corrected their enophthalmos and most of them had fixed their diplopia, indicating a notable increase in extraocular muscle activity. Infraorbital nerve paraesthesia and ocular motility restrictions showed substantial recovery over the follow-up period. Graft density demonstrated adequate bone integration without resorption and orbital volume measures verified the restoration of symmetry between the damaged and unaffected sides. The majority of patients had no problems, and donor site morbidity was very low. Overall, autogenous iliac crest cortical bone grafting proved to be a reliable and safe technique for reconstructing displaced orbital floor fractures, providing excellent functional, aesthetic and structural outcomes.

REFERENCES

1. Smith B, Regan WF Jr. Blow-out fracture of the orbit; mechanism and correction of internal orbital fracture. Am J Ophthalmol. 1957;44:733-739.
2. JM C. Blowout fracture of the floor of the orbit. Trans Am AcdOpthalmolOtolaryngol. 1960;64:676-88.
3. Roncevic R, Malinger, B. Experience with various procedures in the treatment of orbital floor fractures. J. Maxillofac. Surg. 1981;9(2):81-4.
4. Ahlmann, E, Patzakis M, Roidis N, Shepherd, L, Holtom, P. Comparison of anterior and posterior iliac crest bone grafts in terms of harvest-site morbidity and functional outcomes. J Bone Joint Surg (Am.). 2002;84(5):716-20.
5. Saha AK, Samaddar S, Kumar A, Chakraborty A, Deb B. A comparative study of orbital blow out fracture repair, using autogenous bone graft and alloplastic materials. Indian Journal of Otolaryngology and Head & Neck Surgery. 2019 Dec;71(4):542-9.
6. Kontio RK, Laine P, Salo A, Paukku P, Lindqvist C, Suuronen R. Reconstruction of internal orbital wall fracture with iliac crest free bone graft: clinical, computed tomography, and magnetic resonance imaging follow-up study. Plastic & Reconstructive Surgery. 2006 Nov;118(6):1365-74.
7. Alasady MS, Kanj A, Kanj AE. Evaluation of the outcomes of using iliac bone graft for reconstruction of traumatic orbital floor fractures. Journal of population therapeutics and clinical pharmacology= Journal de la therapeutique des populations et de la pharmacologieclinique. 2022 Jun 16;29(2):e71-8.
8. Ram H, Singh RK, Mohammad S, Gupta AK. Efficacy of iliac crest vs. medpor in orbital floor reconstruction.Journal of maxillofacial and oral surgery. 2010 Jun;9(2):134-41.
9. Zunz ME, Blanc DO, Leibovitch MI. Traumatic orbital floor fractures: repair with autogenous bone grafts in a tertiary trauma center. Journal of oral and maxillofacial surgery. 2012 Mar 1;70(3):584-92.
10. Dubois L, Steenen SA, Gooris PJ, Bos RR, Becking AG. Controversies in orbital reconstruction—III. Biomaterials for orbital reconstruction: a review with clinical recommendations. International journal of oral and maxillofacial surgery. 2016 Jan 1;45(1):41-50.
11. Harish S. Autogenous grafts for orbital floor reconstruction: A review. International Journal of Oral and Craniofacial Science. 2017:046-52.
12. O'Connell JE, Hartnett C, Hickey-Dwyer M, Kearns GJ. Reconstruction of orbital floor blow-out fractures with autogenous iliac crest bone: a retrospective study including maxillofacial and ophthalmology perspectives. Journal of Cranio-Maxillofacial Surgery. 2015 Mar 1;43(2):192-8.
13. Garg V, Giraddi GB, Roy S. Comparison of efficacy of mandible and iliac bone as autogenous bone graft for orbital floor reconstruction. Journal of maxillofacial and oral surgery. 2015 Jun;14(2):291-8.
14. Strabbing EM, Kronig SA, van der Mooren RJ, Wevers M, Paridaens D, Koudstaal MJ, Wolvius EW. Autologous Iliac Crest Bone Grafts in Orbital Floor Reconstruction: A Quantifying Study of Graft Resorption and Clinical Outcome. Journal of Maxillofacial and Oral Surgery. 2026 Jan 27:1-8.
15. Anitha GL, Maheswari GU, Sethurajan B. Mandibular symphysis graft versus iliac cortical graft in reconstructing floor in orbital blow out fracture: A comparative study. Annals of maxillofacial surgery. 2012 Jan;2(1):24.
16. Kumar BP, Chowdary MR, Brahme VR, Devi VV, Kupendra S, Bhanot R, Dubey A. Comparison between Metal Mesh and Iliac Bonegraft in the Reconstruction of Orbital Floor Fracture—A Clinical Study. Journal of Pharmacy &Bioallied Sciences. 2024 Jul 31;16(Suppl 3):S2637.