Section: General Surgery

Original Research Article

A COMPARATIVE STUDY BETWEEN FLAP QUILTING SUTURES WITH AXILLARY DRAIN VERSUS CONVENTIONAL SUTURES WITH AXILLARY AND PECTORAL DRAIN IN REDUCING POST-MODIFIED RADICAL MASTECTOMY SEROMA FORMATION

Bikramjit Maity[1], Buddhadeb Show[2], Sibasish Maity[3]

[1]Associate Professor, MBBS, DNB, FMAS, FIAGES, Department of General Surgery, NRS Medical College and Hospital, Kolkata, India.
[2]Resident, MBBS, Department of General Surgery, NRS Medical College and Hospital, Kolkata, India.
[3]Assistant Professor, MBBS, MS, MCh (Plastic Surgery), Department of General Surgery, NRS Medical College and Hospital, Kolkata, India.

Received *: 05/10/2026*
Received in revised form *: 04/11/2026*
Accepted *: 16/11/2026*

Corresponding Author:
Dr. Sibasish Maity,
Assistant Professor, MBBS, MS, MCh (Plastic Surgery), Department of General Surgery, NRS Medical College and Hospital, Kolkata, India.
Email: sibasishmaiti@gmail.com

DOI: 10.70034/ijmedph.2026.4.357

Source of Support: Nil,
Conflict of Interest: None declared

Int J Med Pub Health
2026; 16 (4); 2375-2379

ABSTRACT

Background: Seroma is one of the commonest early complications after modified radical mastectomy (MRM) and axillary dissection. Persistent dead space, disruption of lymphatics and shearing between the skin flaps and chest wall contribute to fluid accumulation. Flap quilting aims to obliterate this dead space by fixing the mastectomy flaps to the underlying muscle and may reduce seroma-related morbidity. **Aims:** To compare flap quilting sutures with an axillary drain versus conventional closure with axillary and pectoral drains after MRM, primarily for postoperative seroma formation and secondarily for other postoperative morbidity, drain removal and hospital stay.

Materials and Methods: This hospital-based analytical longitudinal study was conducted in the Department of General Surgery, NRS Medical College and Hospital, Kolkata, from June 2024 to November 2025. Seventy women undergoing MRM for breast carcinoma were studied in two equal groups (n=35 each).

Results: The groups were comparable for age, BMI and cancer stage. Seroma occurred in 9/35 (25.7%) patients in the quilting group versus 19/35 (54.3%) in the conventional group (χ^2=5.95, p=0.015). Mean drain-removal time was 3.97±0.82 days with quilting and 7.57±1.63 days with conventional closure (p<0.001). Mean hospital stay was 4.11±0.80 versus 9.97±1.40 days, respectively (p<0.001).

Conclusion: Flap quilting after MRM was associated with a significantly lower seroma rate and substantially earlier drain removal and discharge than conventional closure. It is a practical technique for reducing postoperative dead-space-related morbidity after mastectomy.

Keywords: Modified radical mastectomy; flap quilting; seroma; axillary drain; breast cancer; drain removal; hospital stay.

INTRODUCTION

Breast cancer is a heterogeneous malignant disease and remains a major cause of cancer morbidity among women worldwide. Its management is determined by tumour biology, stage, patient factors and available multimodal treatment. Surgery continues to have a central role in operable disease, and modified radical mastectomy (MRM) remains an established procedure for selected patients requiring mastectomy with axillary clearance.[1-4]

Despite improvements in operative technique and perioperative care, postoperative wound morbidity after mastectomy remains clinically important. Seroma, defined as a pathological collection of serous fluid beneath the skin flaps or in the axillary dead space, is among the most frequently encountered complications.[5-7] Reported mechanisms include transection of lymphatic and

blood vessels, inflammatory exudation, creation of a large dead space and repeated shear movement between the elevated flap and underlying chest wall.[8] Seroma may cause discomfort, repeated aspirations, delayed wound healing, flap compromise, infection and delay in subsequent oncological treatment.

Many strategies have been evaluated to prevent seroma, including prolonged drainage, compression, fibrin sealants, tissue adhesives and different methods of flap fixation. However, no single preventive method has eliminated the problem. Conventional MRM closure leaves a potential space between the skin flap and pectoral fascia, usually managed with suction drains. Quilting sutures provide mechanical fixation of the flap to the underlying pectoral fascia or muscle, thereby reducing dead space and limiting shearing. This principle has gained renewed interest because it may reduce both seroma formation and dependence on prolonged drainage.[9]

Evidence from comparative studies, randomized trials and meta-analysis has generally suggested lower seroma rates after flap fixation or quilting, although the magnitude of benefit and effects on drainage, hospital stay and other wound complications vary among studies.[10] The technique may also permit the use of fewer drains, which can improve postoperative comfort and potentially shorten hospitalization. At the same time, concerns remain regarding added operative steps, flap dimpling, cosmetic appearance and whether benefits are consistent across different patient populations.[11] Postmastectomy seroma is multifactorial. Age, body habitus, hypertension, diabetes, extent of axillary dissection, tumour stage and neoadjuvant treatment may influence postoperative wound outcomes. Therefore, baseline comparability between treatment groups is important when evaluating the independent effect of a closure technique. Recent studies have also examined quilting in relation to drain duration, wound complications and length of hospital stay, with several reporting clinically meaningful reductions in postoperative resource use.[12]

In the present study, women undergoing MRM were managed either with flap quilting sutures and a single axillary drain or with conventional closure using axillary and pectoral drains. The study was designed to assess whether obliteration of the mastectomy dead space by quilting could reduce postoperative seroma and related morbidity in a tertiary-care surgical setting.

The present study aims to assess the impact of quilting on rates of post-MRM seroma formation and associated postoperative morbidity, including superficial skin necrosis, flap necrosis, wound gaping, drain removal and length of hospital stay. The study also compared these outcomes between quilting and conventional closure groups.

MATERIALS AND METHODS

Study design: Hospital-based analytical longitudinal study.

Place of study: Department of General Surgery, NRS Medical College and Hospital, Kolkata, West Bengal, India.

Period of study: June 2024 to November 2025 (18 months).

Study Population: Female patients in good general condition undergoing modified radical mastectomy for breast carcinoma and admitted to the General Surgery inpatient department.

Sample size: Seventy patients, divided into two equal groups of 35.

Inclusion Criteria

1. Patients in good general condition undergoing MRM for breast carcinoma within 18 to 70 years of age willing for regular follow-up were enrolled in this study.
2. Female patients undergoing modified radical mastectomy for carcinoma breast irrespective of stage

Exclusion Criteria

Patients undergoing

- Mastectomy without axillary dissection
- Those opting for breast conservation surgery
- Those with inoperable disease
- Patients on anticoagulant treatment

Statistical Analysis: For statistical analysis, data were initially entered into a Microsoft Excel spreadsheet and then analyzed using SPSS (version 27.0; SPSS Inc., Chicago, IL, USA) and GraphPad Prism (version 5). Numerical variables were summarized using means and standard deviations, while categorical variables were described with counts and percentages. Two-sample t-tests were used to compare independent groups, while paired t-tests accounted for correlations in paired data. Chi-square tests (including Fisher's exact test for small sample sizes) were used for categorical data comparisons. P-values ≤ 0.05 were considered statistically significant.

RESULTS

Table 1: Comparison of age between the two groups

Age	Conventional n (%)	Quilting n (%)	Total n (%)	p-value
<50 years	14 (40.0%)	11 (31.4%)	25 (35.7%)	0.454
>50 years	21 (60.0%)	24 (68.6%)	45 (64.3%)	

Table 2: Comparison of BMI between the two groups

BMI (kg/m²)	Conventional n (%)	Quilting n (%)	Total n (%)	p-value
<25	25 (71.4%)	22 (62.9%)	47 (67.1%)	0.445
>25	10 (28.6%)	13 (37.1%)	23 (32.9%)	

Table 3: Comparison of breast-cancer stage between the two groups

Stage	Conventional n (%)	Quilting n (%)	Total n (%)	p-value
I	9 (25.7%)	13 (37.1%)	22 (31.4%)	0.156
II	9 (25.7%)	14 (40.0%)	23 (32.9%)	
III	9 (25.7%)	5 (14.3%)	14 (20.0%)	
IV	8 (22.9%)	3 (8.6%)	11 (15.7%)	

Table 4: Comparison of postoperative seroma formation

Seroma	Conventional n (%)	Quilting n (%)	Total n (%)	p-value
No	16 (45.7%)	26 (74.3%)	42 (60.0%)	0.015
Yes	19 (54.3%)	9 (25.7%)	28 (40.0%)	

Table 5: Comparison of time to drain removal

Group	N	Mean (days)	SD	SEM	p-value
Quilting suture	35	3.97	0.822	0.139	<0.001
Conventional suture	35	7.57	1.632	0.276	

Table 6: Comparison of length of hospital stay

Group	N	Mean (days)	SD	SEM	p-value
Quilting suture	35	4.11	0.796	0.135	<0.001
Conventional suture	35	9.97	1.403	0.237	

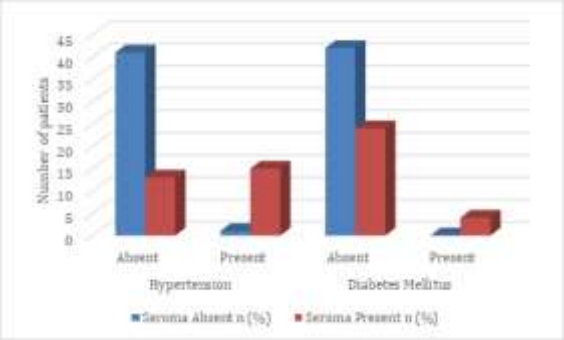

Figure 1: Association of Hypertension and Diabetes Mellitus with Seroma Formation

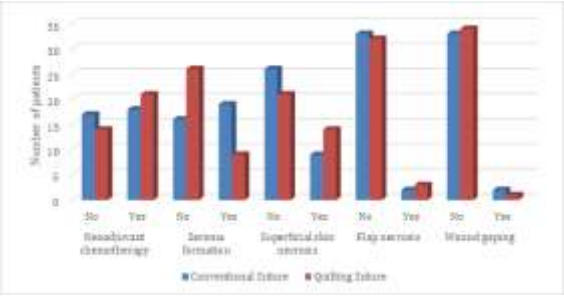

Figure 2: Comparison of Neoadjuvant Chemotherapy and Postoperative Complications Between Conventional Suture and Quilting Suture Groups

Table 1 showed that among the 70 patients, 35 patients were included in the conventional suture group and 35 in the quilting suture group. In the conventional group, 14 (40.0%) patients were aged <50 years and 21 (60.0%) were aged >50 years, whereas in the quilting group, 11 (31.4%) were aged <50 years and 24 (68.6%) were aged >50 years. Overall, 25 (35.7%) patients were aged <50 years and 45 (64.3%) were aged >50 years. There was no statistically significant difference in age distribution between the groups (p=0.454).

Table 2 showed that BMI <25 kg/m² was observed in 25 (71.4%) patients in the conventional group and 22 (62.9%) in the quilting group, while BMI >25 kg/m² was present in 10 (28.6%) and 13 (37.1%) patients, respectively. Overall, 47 (67.1%) patients had BMI <25 kg/m² and 23 (32.9%) had BMI >25 kg/m². The difference in BMI distribution between the two groups was not statistically significant (p=0.445).

Table 3 showed that in the conventional group, Stage I, II, III and IV breast cancer were each present in 9 (25.7%), 9 (25.7%), 9 (25.7%) and 8 (22.9%) patients, respectively. In the quilting group, the corresponding numbers were 13 (37.1%), 14 (40.0%), 5 (14.3%) and 3 (8.6%). Overall, Stage II was most frequent in 23 (32.9%) patients, followed by Stage I in 22 (31.4%), Stage III in 14 (20.0%) and Stage IV in 11 (15.7%). Stage distribution did not differ significantly between the groups (p=0.156).

Table 4 showed that postoperative seroma developed in 19 (54.3%) patients in the conventional group compared with 9 (25.7%) patients in the quilting group. Seroma was absent in 16 (45.7%) and 26 (74.3%) patients, respectively. Overall, seroma occurred in 28 (40.0%) of the 70 patients. The incidence of seroma was significantly lower in the quilting group than in the conventional group (p=0.015).

Table 5 showed that the mean time to drain removal was 3.97 ± 0.82 days in the quilting suture group compared with 7.57 ± 1.63 days in the conventional suture group. The difference was statistically significant (p<0.001), demonstrating substantially earlier drain removal following flap quilting.

Table 6 showed that the mean length of hospital stay was 4.11 ± 0.80 days in the quilting suture group and

9.97 ± 1.40 days in the conventional suture group. The hospital stay was significantly shorter in the quilting group (p<0.001).

DISCUSSION

The present study compared flap quilting with a single axillary drain against conventional closure with axillary and pectoral drains following MRM. The principal finding was a significantly lower incidence of postoperative seroma in the quilting group (25.7%) than in the conventional group (54.3%; p=0.015). Quilting was also associated with earlier drain removal and a markedly shorter hospital stay. These findings support the biological rationale that fixation of the mastectomy flap to the underlying chest wall reduces dead space and shear, thereby limiting accumulation of lymphatic and inflammatory fluid.

Baseline characteristics were broadly comparable. Nearly two-thirds of participants were older than 50 years, and approximately one-third had BMI >25 kg/m². Neither age nor BMI differed significantly between groups. Cancer-stage distribution was also statistically similar. This comparability is important because age, obesity, tumour burden and treatment-related factors have been discussed as potential modifiers of postoperative wound morbidity and seroma risk.[5,8,9]

The overall seroma incidence in this study was 40.0%, but the group-specific rates demonstrated a clear difference: 54.3% after conventional closure versus 25.7% after quilting. Earlier literature described seroma as a frequent complication after mastectomy and axillary dissection.[5-8] More recent work has focused on mechanical flap fixation. Mazouni et al. reported reduced seroma with quilting after mastectomy,[10] and a meta-analysis by Eliav et al. found quilting to be associated with lower seroma formation.[13] The direction of effect in the present study is consistent with those observations.

Recent comparative studies further support the use of quilting. Meena et al. evaluated quilting for flap closure after MRM and reported lower seroma-related morbidity.[14] Malpani et al. similarly found a significant reduction in postmastectomy seroma with quilting.[15] Jayalal et al. reported a lower incidence of seroma in patients treated with quilting sutures than with conventional sutures.[16] Foulon et al. demonstrated reduced seroma after quilting while also examining aesthetic outcomes, suggesting that dead-space closure can be effective without necessarily producing unacceptable cosmetic consequences.[17] Jakhetiya et al. and Bhagchandani et al. also reported favorable postoperative outcomes with quilting or flap fixation approaches.[18,19]

Drain duration is clinically relevant because prolonged drainage can increase discomfort, restrict mobility, complicate discharge planning and require additional wound care. In the present study, drains were removed at a mean of 3.97±0.82 days in the quilting group compared with 7.57±1.63 days in the conventional group (p<0.001). This difference is consistent with the concept that reduced dead space leads to lower fluid production and earlier achievement of the drain-removal threshold. Manjunath et al. reported that mastectomy flap fixation reduced postoperative fluid drainage and seroma formation,[11] while other recent quilting studies have likewise described reduced drainage requirements.[14-19]

Hospital stay was also significantly reduced, from 9.97±1.40 days with conventional closure to 4.11±0.80 days with quilting. Although discharge practices differ among institutions, earlier drain removal and fewer seroma-related interventions can plausibly facilitate earlier discharge. The magnitude of the difference observed here suggests that quilting may have implications not only for wound outcomes but also for bed utilization and patient convenience. Historical work has linked postmastectomy complications to longer hospital stay,[7] and contemporary studies increasingly evaluate recovery and resource use alongside seroma incidence.

The thesis also assessed superficial skin necrosis, flap necrosis and wound gaping. Superficial skin necrosis occurred in 32.9% overall and was numerically higher in the quilting group (40.0%) than in the conventional group (25.7%), but the difference was not significant. Flap necrosis occurred in 7.1% overall (8.6% quilting vs 5.7% conventional), and wound gaping occurred in 4.3% overall (5.7% quilting vs 2.9% conventional); neither comparison was statistically significant. Thus, the reduction in seroma was not accompanied by a statistically demonstrated increase in these wound complications in this sample.

Patient factors also influenced seroma in the thesis analyses. Seroma was more frequent among patients aged >50 years, and significant associations were reported with higher BMI, hypertension and diabetes. These findings reinforce the multifactorial nature of postmastectomy seroma and suggest that closure technique operates alongside host-related risk factors. Careful perioperative optimization and closer surveillance of higher-risk patients therefore remain important even when quilting is used.

The study has limitations. It was conducted at a single center with 70 participants, limiting precision and generalizability. Follow-up for postoperative complications was four weeks, so later outcomes and long-term cosmetic effects were not assessed. The study compared two closure-and-drain strategies simultaneously; therefore, the observed benefit cannot be attributed exclusively to quilting independently of differences in drain configuration. Larger multicenter randomized studies with standardized drain protocols, longer follow-up, patient-reported outcomes and formal cosmetic assessment would strengthen the evidence.

Within these limitations, the study provides clinically relevant evidence from a tertiary-care setting. The significant reduction in seroma, earlier drain removal

and shorter hospitalization indicate that flap quilting is a useful dead-space management strategy after MRM and merits consideration as part of routine closure where surgical expertise and patient factors are appropriate.

CONCLUSION

In this hospital-based study of 70 women undergoing modified radical mastectomy, flap quilting sutures with a single axillary drain were associated with better early postoperative outcomes than conventional closure with axillary and pectoral drains. Seroma formation was significantly lower with quilting (25.7% vs 54.3%, p=0.015). Quilting also enabled significantly earlier drain removal (3.97±0.82 vs 7.57±1.63 days) and a shorter hospital stay (4.11±0.80 vs 9.97±1.40 days), both p<0.001. Baseline age, BMI and cancer stage were comparable between groups. Other wound complications did not show significant between-group differences. These findings support flap quilting as a practical method of reducing mastectomy dead space and postoperative seroma burden. Larger randomized multicenter studies with longer follow-up are recommended to confirm effectiveness and evaluate long-term cosmetic and patient-reported outcomes.

REFERENCES

1. World Cancer Research Fund. Breast cancer statistics [Internet]. Available from: https://www.wcrf.org/cancer-trends/breast-cancer-statistics/
2. American Cancer Society. How common is breast cancer? [Internet]. Available from: https://www.cancer.org/cancer/types/breast-cancer/about/how-common-is-breast-cancer.html
3. Waks AG, Winer EP. Breast cancer treatment: a review. JAMA. 2019;321(3):288-300.
4. Gradishar WJ, Moran MS, Abraham J, et al. Breast Cancer, Version 3.2022, NCCN Clinical Practice Guidelines in Oncology. J Natl Compr Canc Netw. 2022;20(6):691-722.
5. Bryant M, Baum M. Postoperative seroma following mastectomy and axillary dissection. Br J Surg. 1987;74:1187.
6. Watt-Boolsen S, Nielsen VB, Jensen J, Bak S. Postmastectomy seroma: a study of the nature and origin of seroma after mastectomy. Dan Med Bull. 1989;36:487-489.
7. Tejler G, Aspegren K. Complications and hospital stay after surgery for breast cancer: a prospective study of 385 patients. Br J Surg. 1985;72:542-544.
8. Porter KA, O'Connor S, Rimm E, Lopez M. Electrocautery as a factor in seroma formation following mastectomy. Am J Surg. 1998;176:8-11.
9. Kerin MJ, O'Hanlon DM, Kenny P, Kent PJ, Given HF. Argon-enhanced cutting and coagulation confers advantages over conventional electrocautery for mastectomy. Eur J Surg Oncol. 1996;22:571-573.
10. Mazouni C, et al. Quilting sutures reduces seroma in mastectomy. Clin Breast Cancer. 2015;15(4):289-293.
11. Manjunath P, Yelamanchi R, Agrawal H, et al. Effect of mastectomy flap fixation on post-operative fluid drainage and seroma formation in breast cancer patients: a double-blinded randomised control trial. Pol Przegl Chir. 2023;95(2):18-26.
12. Supraja S, et al. A randomised controlled trial comparing quilting technique versus conventional plain suturing in reducing post mastectomy seroma. Int J Curr Pharm Rev Res. 2025;17(6):883-888.
13. Eliav T, Novack V, Krieger Y. Effect of quilting on seroma formation in mastectomies: a meta-analysis. Surg Oncol. 2021;39:101665.
14. Meena S, Bishnoi S, Badkur, Mahendra ML, Vishnoi JR, Sharma N. A quilting sutures technique for flap closure in patients undergoing modified radical mastectomy for the prevention of seroma: a single-center, randomized controlled trial. J Educ Health Promot. 2024;13(1):240.
15. Malpani A, Kamble MA, Balwantkar S. Evaluation of quilting technique for reduction of post mastectomy seroma formation. Int J Res Med Sci. 2025;13(5):2004-2009.
16. Jayalal JA, Kumar SJ, Manovah JA, Michael L, Haaris M. Quilting sutures versus conventional sutures in modified radical mastectomy in reducing post-operative seroma formation: prospective controlled trial. Int J Acad Med Pharm.
17. Foulon A, Mancaux A, Theret P, et al. Efficacy and aesthetic outcomes for quilting sutures in the prevention of seroma after mastectomy. Sci Rep. 2023;13:1898.
18. Jakhetiya A, Patel D, Jakhetiya B, et al. Quilting sutures versus conventional closure to prevent seroma after modified radical mastectomy: a comparative study. Indian J Gynecol Oncol. 2025;23:89.
19. Bhagchandani M, Shukla V, Maurya RK, Chaudhary A, Kumar K. A comparative study between mastectomy flap quilting sutures with axillary drain versus conventional sutures with axillary and pectoral drain in reducing post-modified radical mastectomy seroma formation. Indian J Surg. 2023. doi:10.1007/s12262-023-03756-6.