Section: Pathology

Original Research Article

CLINICO-HISTOPATHOLOGICAL PANORAMA OF LEPROSY – A RETROSPECTIVE STUDY AT TERTIARY CARE CENTRE

Vidya Aher-Kale[1], Kunal Torane[2], Karuna Veer[3], Bharati Shirish Deore[4], Renuka Patil[5], Preeti Bajaj[6]

[1]*Assistant Professor, Department of Pathology, Dr.Vasantrao Pawar Medical College, Hospital & Research Centre, Nashik, Maharashtra, India.*
[2]*Assistant Professor, Dr. Vasantrao Pawar Medical College Hospital and Research Centre, Nashik, Maharashtra, India.*
[3]*Senior Resident, Dr. Vasantrao Pawar Medical College Hospital and Research Centre, Nashik, Maharashtra, India.*
[4]*Associate Professor, Department of Pathology, Dr. Vasantrao Pawar Medical College, Hospital & RC, Nashik, Maharashtra, India.*
[5]*Junior Resident, Dr. Vasantrao Pawar Medical College Hospital and Research Centre, Nashik, Maharashtra, India.*
[6]*Professor and Head of the Department, Department of Pathology, Dr. Vasantrao Pawar Medical College Hospital and Research Centre, Nashik, Maharashtra, India.*

Received *: 02/10/2026*
Received in revised form *: 26/10/2026*
Accepted *: 09/11/2026*

Corresponding Author:
Dr. Preeti Bajaj,
Professor and Head of the Department, Department of Pathology, Dr. Vasantrao Pawar Medical College Hospital and Research Centre, Nashik, Maharashtra, India.
Email: dr.prbajaj@gmail.com

DOI: 10.70034/ijmedph.2026.4.346

Source of Support: Nil,
Conflict of Interest: None declared

Int J Med Pub Health
2026; 16 (4); 2303-2308

ABSTRACT

Background: Leprosy is a chronic granulomatous infectious disease caused by Mycobacterium leprae that predominantly affects the skin and peripheral nerves. Despite significant reduction in prevalence following implementation of control programs, leprosy remains an important public health concern in developing countries, including India. Due to its varied clinical manifestations and overlap with other dermatological disorders, accurate diagnosis and classification remain challenging, highlighting the importance of histopathological evaluation. The objectives is to study the clinicohistopathological spectrum of leprosy and evaluate the correlation between clinical diagnosis and histopathological findings in skin biopsy specimens from a tertiary care center.

Materials and Methods: This retrospective observational study was conducted in the Department of Pathology, Dr. Vasantrao Pawar Medical College, Hospital and Research Centre, Nashik, from January 2023 to December 2024. A total of 156 clinically diagnosed leprosy cases were evaluated, of which 138 histopathologically confirmed cases were included in the final analysis. Skin biopsy specimens were processed routinely and stained with hematoxylin and eosin, while Fite–Faraco staining was performed to demonstrate lepra bacilli. Cases were classified according to the Ridley–Jopling classification system.

Results: The majority of patients belonged to the 21–40 years age group (45.65%) with male predominance (male ratio 1.3:1). Borderline Tuberculoid leprosy was the most common subtype (32.60%), followed by Lepromatous Leprosy (21.10%). Hypopigmented patches were the commonest presentation (56.52%), while upper limbs were the most frequently involved site (34.78%). Fite–Faraco positivity was observed in 40.57% cases. Clinicohistopathological concordance was observed in 63.76% cases.

Conclusion: Histopathological examination with Fite–Faraco staining remains essential for accurate diagnosis and classification of leprosy, facilitating early treatment and prevention of disability.

Keywords: Leprosy, histopathology, Fite–Faraco stain.

INTRODUCTION

Leprosy is among the oldest diseases known to humankind and continues to remain a significant infectious disease despite advances in diagnosis and treatment.[1] It is a chronic, granulomatous, and potentially disabling disease primarily caused by Mycobacterium leprae, affecting predominantly the cooler regions of the body, particularly the skin and peripheral superficial nerves. Historically, leprosy

has been recognized in ancient literature as "Kushtaroga." The causative organism, M. leprae, was first identified in 1873 by Armauer Hansen, marking a major milestone in understanding the disease etiology.[2,3]

Mycobacterium leprae primarily involves the skin and superficial peripheral nerves, resulting in a wide spectrum of clinical manifestations. The disease progression is characteristically chronic and complex, largely determined by the interaction between host immune responses and pathogen-related factors.[4]

The Ridley–Jopling classification remains the most widely accepted classification system for leprosy. This system categorizes the disease based on clinical presentation, histopathological characteristics, and host immunological response. Furthermore, it provides important insights into disease pathogenesis, progression, prognosis, and treatment outcomes. The classification includes Indeterminate Leprosy (IL), Tuberculoid Leprosy (TT), Borderline Tuberculoid Leprosy (BT), Mid-borderline Leprosy (BB), Borderline Lepromatous Leprosy (BL), and Lepromatous Leprosy (LL).[5]

The diverse clinical spectrum of leprosy and its resemblance to several dermatological conditions often make early diagnosis challenging, resulting in delayed recognition or misdiagnosis.[6] Therefore, histopathological examination plays a crucial role in the early detection, accurate categorization, and timely management of the disease, thereby helping prevent irreversible complications such as nerve damage, deformities, and disability.[7]

Globally, approximately 2–3 million individuals are estimated to be living with permanent disabilities attributable to leprosy. Recognizing this burden, the World Health Organization (WHO) introduced a five-year strategy (2011–2015) emphasizing early detection to reduce disability associated with leprosy. Subsequently, in April 2016, WHO launched the modified five-year "Global Leprosy Strategy 2016–2020" under the theme "Accelerating towards a leprosy-free world." In India, the Ministry of Health and Family Welfare implements the National Leprosy Eradication Programme (NLEP), which provides strategic guidance for state and union territory-level interventions. These initiatives have significantly reduced the prevalence rate of leprosy in India from 57.8 per 10,000 population in 1983 to 0.66 per 10,000 population in 2016. Nevertheless, India continues to account for nearly 60% of newly reported global cases annually and remains among the 22 global priority countries contributing approximately 95% of the worldwide leprosy burden. These observations underscore the continued need for focused research and strengthened disease control strategies to reduce the burden of leprosy in India.[8]

Leprosy continues to represent a major public health concern in many developing countries. Effective control of communicable diseases fundamentally depends upon timely identification of the causative organism and implementation of targeted interventions aimed at interrupting disease transmission.[9]

Although leprosy has achieved elimination status as a public health problem in India, it continues to persist in several regions. Consequently, ongoing research remains essential to better understand disease occurrence, transmission dynamics, diagnostic approaches, preventive interventions, and management strategies. Detailed clinicohistopathological studies are particularly important for re-evaluating clinical findings alongside histopathological parameters to improve diagnostic precision across the leprosy spectrum. Owing to the considerable clinical variability observed in early lesions, histopathological evaluation of skin biopsies should be considered an essential component of assessment in suspected cases. Correlation between clinical diagnosis and biopsy findings facilitates more accurate classification, prognostication, and therapeutic decision-making. Therefore, clinicohistopathological correlation assumes substantial importance in achieving early diagnosis and optimizing disease management.[10]

MATERIALS AND METHODS

This hospital-based observational study was conducted in the Department of Pathology, Dr. Vasantrao Pawar Medical College, Hospital and Research Centre, Nashik. The study evaluated the histomorphological characteristics of skin biopsy specimens obtained over a two-year period from January 2023 to December 2024 from clinically diagnosed cases of leprosy attending a tertiary care hospital. A total of 156 clinically diagnosed leprosy patients were included in the study. Ethical approval for the study was obtained from the Institutional Ethics Committee prior to commencement.

Skin biopsy specimens from clinically suspected leprosy patients were received from the Department of Dermatology, Dr. Vasantrao Pawar Medical College, Hospital and Research Centre, Nashik. All clinically diagnosed cases of leprosy, irrespective of age, sex, occupation, religion, or socioeconomic status, were included in the study. Cases with inadequate biopsy material, inconclusive histopathological findings, or poorly preserved specimens were excluded.

Biopsy specimens were obtained from representative skin lesions and transported to the histopathology laboratory in glass or plastic containers containing 10% formalin solution. Relevant clinical details including patient history, presenting symptoms, characteristics of skin lesions, and provisional clinical diagnosis were recorded. Gross examination of biopsy specimens was performed with emphasis on specimen appearance and size.

Tissue samples were fixed in 10% neutral buffered formalin as early as possible after collection and processed preferably within 24 hours. Following

fixation, tissues were processed routinely, embedded in paraffin wax, and serial sections measuring 4–5 µm thickness were prepared. Histomorphological assessment was performed on sections stained with hematoxylin and eosin (H&E). Additionally, Fite–Faraco (FF) staining was carried out for the identification and demonstration of lepra bacilli.

Histopathological evaluation and bacteriological assessment were performed for all specimens. Diagnosis of leprosy was established based on characteristic histopathological findings observed on routine H&E sections in conjunction with Fite–Faraco staining. Fite–Faraco stained sections were specifically examined for the presence of lepra bacilli, and the bacteriological index (BI) was documented for each case.

Based on histopathological features, cases were categorised according to the Ridley–Jopling classification system into Tuberculoid Leprosy (TT), Borderline Tuberculoid Leprosy (BT), Mid-borderline Leprosy (BB), Borderline Lepromatous Leprosy (BL), and Lepromatous Leprosy (LL).

The bacteriological index was graded according to Ridley's logarithmic scale under oil immersion microscopy to assess bacillary load as follows:

- 6+ : More than 1000 bacilli per average oil immersion field
- 5+ : 100–1000 bacilli per average oil immersion field
- 4+ : 10–100 bacilli per average oil immersion field
- 3+ : 1–10 bacilli per average oil immersion field
- 2+ : 1–10 bacilli in 10 oil immersion fields
- 1+ : 1–10 bacilli in 100 oil immersion fields

A minimum of 100 oil immersion fields were examined before assigning the final bacteriological index for each specimen.

RESULTS

A total of 156 clinically diagnosed cases of leprosy were evaluated during the study period. Of these, three biopsy specimens yielded inconclusive findings, while 15 cases were determined not to be leprosy on histopathological examination. Therefore, 138 confirmed cases of leprosy were included in the final analysis, accounting for 88.46% of the clinically suspected cases.

The majority of patients belonged to the 21–40 years age group, comprising 63 cases (45.65%). A male predominance was observed, with 77 male patients (55.79%) and 61 female patients (44.20%), resulting in a male-to-female ratio of 1.3:1.

Among the 138 skin biopsy specimens analysed histopathologically, Borderline Tuberculoid (BT) leprosy was the most common subtype, accounting for 45 cases (32.60%). This was followed by Lepromatous Leprosy (LL) with 29 cases (21.10%), Borderline Lepromatous (BL) leprosy with 25 cases (18.12%), Tuberculoid Leprosy (TT) with 13 cases (9.42%), Mid-borderline/Borderline (BB) leprosy with 10 cases (7.24%), Indeterminate Leprosy with 7 cases (5.07%), Histoid leprosy with 6 cases (4.34%), and Erythema Nodosum Leprosum (ENL) with 3 cases (2.17%). A detailed description of all cases with age and gender distribution is given in [Table 1].

Table 1: Age- and Gender wise distribution of cases.

Entity	TT		BT		BB		BL		LL		IL		ENL		HL		Total
Age/ Gender	M	F	M	F	M	F	M	F	M	F	M	F	M	F	M	F	
1-20	1	1	2	2	0	0	1	1	1	0	0	0	0	0	0	0	9
21-40	4	2	12	8	2	2	7	4	8	5	2	1	0	3	0	3	63
41-60	2	1	6	6	2	1	3	3	5	4	0	1	0	1	0	0	35
61-80	1	0	3	2	1	0	2	1	2	1	2	1	0	2	0	0	18
>80	1	0	2	2	1	1	2	1	2	1	0	0	0	0	0	0	13
Total	13		45		10		25		29		7		6		3		138

With respect to anatomical distribution, the upper limbs constituted the most commonly involved site, observed in 48 cases (34.78%), followed by the trunk in 38 cases (27.53%), lower limbs in 35 cases (25.36%), and head and neck region involvement in 17 cases (12.31%) [Table 2].

Table 2: Distribution of cases by site of lesions.

SITE	No. of Cases	Percentage (%)
Head and neck	17	12.32
Trunk	38	27.54
Upper limbs	48	34.78
Lower limbs	35	25.36
Total	138	100

Fite–Faraco staining was performed in all cases, of which 56 cases (40.57%) demonstrated positivity for lepra bacilli. No bacilli were identified in any case of Tuberculoid Leprosy (TT). In contrast, all cases of Lepromatous Leprosy (LL), Histoid leprosy, and Erythema Nodosum Leprosum (ENL) demonstrated Fite–Faraco positivity.

The most frequent clinical presentation observed was hypopigmented patches, reported in 78 cases (56.52%), followed by erythematous patches in 29 cases (21.10%). Histopathological examination revealed that epithelioid cell granulomas and giant cells were predominantly associated with the tuberculoid spectrum of disease, whereas histiocytic

infiltration, perivascular inflammation, and perineural involvement were more frequently encountered in lesions belonging to the lepromatous spectrum.

Clinicohistopathological correlation demonstrated concordance in 88 cases, yielding an overall correlation rate of 63.76%, indicating moderate agreement between clinical and histopathological diagnosis.

Histopathological examination of skin punch biopsy specimens demonstrated characteristic morphological features of different clinical forms of leprosy. The lepromatous leprosy specimen showed epidermal thinning with a subepidermal grenz zone and diffuse dermal infiltration by sheets of foamy macrophages (Virchow cells), admixed with sparse lymphocytes. Perineural inflammatory infiltration was also observed, indicating neural involvement. Fite Faraco staining demonstrated numerous acid-fast bacilli arranged in globi within foamy histiocytes. The histoid leprosy specimen revealed an atrophic epidermis separated from the underlying dermal lesion by a narrow grenz zone, with a well circumscribed nodular proliferation of spindle shaped histiocytes arranged in interlacing fascicles, whorls and storiform patterns. In contrast, the tuberculoid leprosy specimen showed well-formed dermal epithelioid cell granulomas comprising epithelioid histiocytes, lymphocytes and occasional Langhans giant cells, with mild epidermal acanthosis and absence of a distinct grenz zone (Figures 1–5).

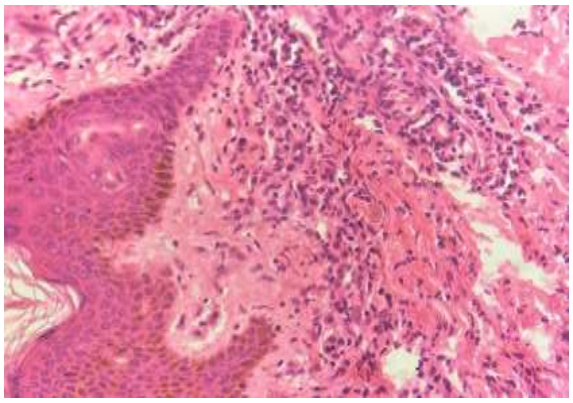

Figure 1: Lepromatous leprosy showing foamy macrophage infiltration and grenz zone.

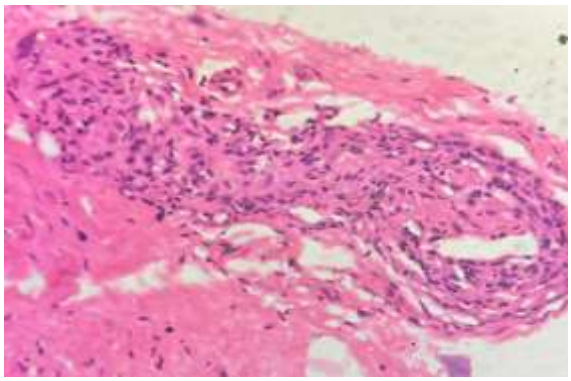

Figure 2: Lepromatous leprosy showing perineural inflammatory infiltration.

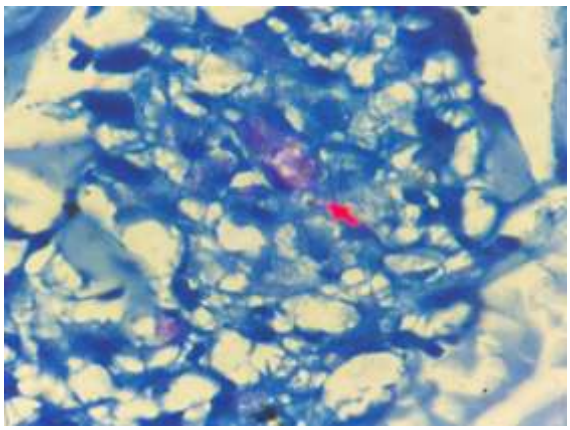

Figure 3: Fite Faraco stain demonstrating acid fast bacilli within foamy histiocytes.

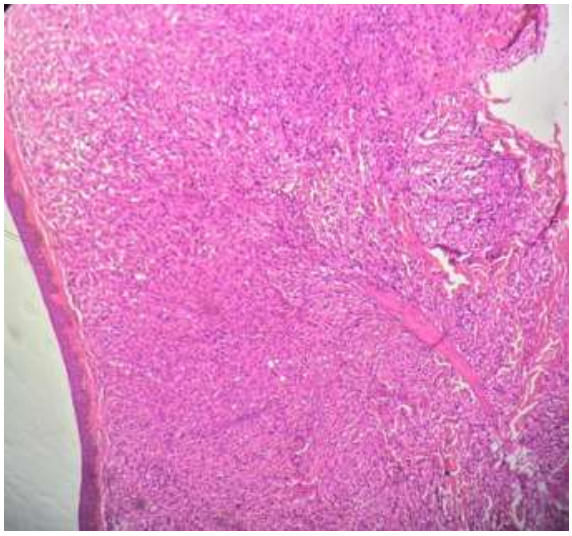

Figure 4: Histoid leprosy showing spindle shaped histiocytes in storiform and interlacing patterns.

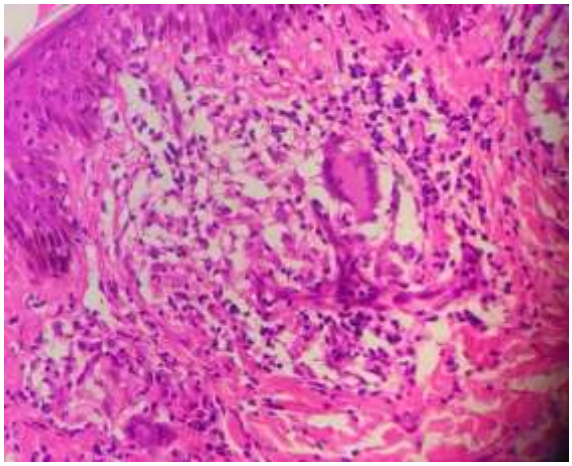

Figure 5: Tuberculoid leprosy showing well-formed epithelioid cell granulomas with Langhans giant cells.

DISCUSSION

Leprosy is a chronic, slowly progressive infectious disease caused by Mycobacterium leprae, primarily affecting the skin and peripheral nerves. Despite advancements in diagnostic modalities, histopathological examination of skin lesions

remains the gold standard for establishing an accurate diagnosis and classifying the disease spectrum.[11]

In the present study, the Ridley–Jopling classification system was employed for histopathological categorization of leprosy cases. In addition to the classical spectrum, Indeterminate leprosy, Histoid leprosy, and Erythema Nodosum Leprosum (ENL) were also included to encompass the complete clinicopathological spectrum encountered during the study period.[12] A total of 138 histopathologically confirmed cases of leprosy were included for analysis.

Leprosy can affect individuals across all age groups.[13] In the present study, the highest number of cases was observed in the 21–40 years age group. Similar age distribution patterns have been documented in several previous studies.[7,14–18] The predominance of cases within the economically productive age group highlights the significant socioeconomic burden associated with the disease.

A male predominance was observed in the present study, with a male-to-female ratio of 1.3:1. Comparable findings have been reported in previous studies conducted by Tilva K et al,[14] Ruchi et al,[18] Radha et al,[19] Vahini et al,[20] and Adhikari et al.[21] The higher prevalence among males may be attributable to increased occupational exposure, greater outdoor activity, and improved healthcare-seeking behaviour among men compared to women.

Borderline Tuberculoid (BT) leprosy constituted the most common histopathological subtype in the present study, accounting for 32.60% of cases. Similar observations have been reported by Atram et al,[7] and Bijjaragi et al,[22] Furthermore, studies by Naik et al,[23] Nadia et al,[24] Kadam et al,[25] and Mehta et al,[26] also demonstrated findings consistent with the present study. Following BT leprosy, Lepromatous Leprosy (LL) represented the second most common subtype, followed by Borderline Borderline (BB), Tuberculoid Leprosy (TT), Histoid leprosy, and ENL. Comparable distributions have been reported by Suri et al,[13] Murthy NB et al,[27] and Verma et al.[28]

Erythema Nodosum Leprosum (ENL) was the least common subtype observed in the present study, accounting for three cases (2.17%). Similar findings were documented by Semwal et al., who reported an incidence of 4.1% for ENL cases.[29] The borderline spectrum (BT, BB, and BL collectively) accounted for 67.39% of cases, indicating predominance of immunologically unstable forms of disease within the study population. Similar observations have been reported by Ruchi S et al.[18]

The upper limbs were identified as the most commonly affected anatomical site in the present study, although variations in anatomical distribution have been reported across different studies. These differences may reflect variability in disease presentation, population characteristics, and healthcare-seeking patterns.

Clinically, hypopigmented patches were the most frequent presenting feature, followed by erythematous patches. Similar clinical patterns have been documented in earlier studies.[10,14,20,27] Recognition of these common presentations is important for facilitating early clinical suspicion and timely diagnostic workup.

Fite–Faraco staining was performed in all cases for the identification of acid-fast bacilli (AFB), contributing substantially to diagnostic confirmation and classification of disease subtypes. Maximum positivity was observed among Borderline Lepromatous (BL), Lepromatous Leprosy (LL), and Histoid leprosy cases. Overall, Fite–Faraco positivity was observed in 56 of 138 cases (40.57%). Comparable positivity rates have been reported by Ruchi S et al,[18] Radha et al,[19] Chintak et al,[30] and Rekam A et al.[31] Notably, all cases of Tuberculoid Leprosy (TT) demonstrated complete negativity for AFB, whereas Histoid leprosy cases showed 100% positivity, reflecting the bacillary burden differences across the immunological spectrum of disease.

Clinicohistopathological correlation in the present study was observed in 63.76% of cases, indicating moderate concordance between clinical diagnosis and histopathological findings. Similar levels of agreement have been reported in previous studies.[6,13] This finding emphasizes the importance of integrating histopathological evaluation with clinical assessment for improving diagnostic accuracy and appropriate disease classification.

CONCLUSION

Skin biopsy is a minimally invasive procedure that plays a pivotal role in the diagnosis and classification of leprosy. Histopathological examination of skin biopsy specimens remains the gold standard for establishing an accurate diagnosis and categorizing the disease spectrum. Integration of histomorphological findings with clinical history and Fite–Faraco staining significantly enhances diagnostic accuracy, facilitates early detection, and aids in precise disease typing. Early and accurate diagnosis is crucial for timely initiation of treatment, prevention of complications and deformities, assessment of prognosis, and improvement of overall patient outcomes.

REFERENCES

1. Park JE, Park K. Epidemiology of communicable diseases. In: Park JE, Park K, editors. Textbook of Preventive and Social Medicine. Jabalpur: Banarsidas Bhanot; 1991. p. 215-25.
2. Rees RJW, Young DB. The microbiology of leprosy. In: Hastings RC, editor. Leprosy. New York: Churchill Livingstone; 1994. p. 49-83.
3. Menghani B, Gupta A, Gupta N, Gupta R. Pattern of leprosy: a histomorphological study with clinical correlation in Ajmer district. Ann Pathol Lab Med. 2021;8(3):100-5.
4. Walker SL, Lockwood DN. The clinical and immunological features of leprosy. Br Med Bull. 2006;78:103-21.
5. Jopling WH, McDougall AC. Definition, epidemiology and world distribution. In: Jopling WH, McDougall AC, editors. Handbook of Leprosy. 1st Indian ed. Delhi: CBS Publishers and Distributors; 1996. p. 10-53.

6. Kini RG, Choudhary H. Clinicopathological correlation in diagnosis of Hansen's disease: a histopathologist's perspective. J Interdiscip Histopathol. 2017;5:48-54.
7. Atram MA, Ghongade PV, Gangane NM. A clinicohistopathological correlation of Hansen's disease in a rural tertiary care hospital of central India. J Glob Infect Dis. 2020;12(4):191-6.
8. Narasimha Rao P, Suneetha S. Current situation of leprosy in India and its future implications. Indian Dermatol Online J. 2018;9(2):83-9.
9. Ganapathy R, Revankar CR. Leprosy control. In: Valia RG, Valia AR, editors. Textbook and Atlas of Dermatology. Mumbai: Bhalani Publishing House; 1994. p. 1427-37.
10. Manandhar U, Adhikari RC, Sayami G. Clinico-histopathological correlation of skin biopsies in leprosy. J Pathol Nepal. 2013;3:452-8.
11. Kaur S, Sharma VK, Basak P, Kaur I, Radotra BD. Concurrent skin and nerve histology in leprosy and its role in classification of leprosy. Lepr Rev. 1993;64:110-6.
12. Ridley DS, Jopling WH. A classification of leprosy for research purposes. Lepr Rev. 1962;33:119-28.
13. Suri SK, Iyer RR, Patel DU, Bandil S, Baxi S. Histopathology and clinicohistopathological correlation in Hansen's disease. J Res Med Dent Sci. 2014;2:37-44.
14. Tilva KK, Patel NK, Shah PD, et al. A clinicopathological study of leprosy: a study of skin biopsies. Int J Res Med Sci. 2022;10(10):2179-83.
15. Kumar A, Negi SR, Vaishnav K. A study of clinico-histopathological correlation of leprosy in a tertiary care hospital in western Rajasthan. J Res Med Dent Sci. 2014;2(3):43-8.
16. Shivani S, Nilesh S, Jignasa B. Clinicopathological correlation in leprosy. Int J Med Sci Public Health. 2019;8(6):459-64.
17. Bommaksanti J, Putta S, Gokhale S. Histopathological relevance in clinical spectrum of Hansen's disease. J Med Sci Clin Res. 2016;4(12):14678-84.
18. Ruchi S, Mamta K, Punam P. Histopathological panorama of leprosy in a tertiary care hospital of Bihar. J Clin Diagn Res. 2019;13(4):12-5.
19. Radha, Singh A, Kumar P, et al. A retrospective study of histomorphological spectrum of Hansen's disease in a tertiary care centre of Barabanki area. Asian J Pharm Clin Res. 2023;16(7):71-4.
20. Vahini G, Swathi C, Umarani P, Niharika GM, Asha T. A histopathological study of leprosy along with clinical correlation. Indian J Appl Res. 2020;10(1):101-4.
21. Bijjaragi S, Kulkarni V, Suresh KK, Kumar P. Correlation of clinical and histopathological classification of leprosy in post-elimination era. Indian J Lepr. 2012;84:271-5.
22. Naik SM, More SA, Joshi SR. Correlation of histomorphological findings with bacteriological index in leprosy patients. Iran J Pathol. 2022;17(1):48-55.
23. Nadia S, Rashmi J, Sohaib A, Rawat S, Thamarai NS, Meena H. Clinicopathological correlation of leprosy: a 4-year retrospective study from a tertiary referral center in North India. Int J Med Res Health Sci. 2015;4(2):350-4.
24. Kadam Y, Ashtekar R, Pawar V, Pimpale A. A study of leprosy patients attending a tertiary care hospital. Int J Community Med Public Health. 2016;3(12):3419-22.
25. Mehta B, Desai N, Khar S. Clinico-pathological correlation in leprosy. Int J Dermatol. 2012;51(1):1-5.
26. Murthy N. Histopathological study of leprosy [dissertation]. Bengaluru: Rajiv Gandhi University of Health Sciences; 2000.
27. Verma OP. Some epidemiological features of leprosy in a rural area in Hooghly district. Lepr India. 1976;48(4):371-81.
28. Semwal S, Joshi D, Goel G, Asati D, Kapoor N. Clinico-histological correlation in Hansen's disease: three-year experience at a newly established tertiary care center in central India. Indian J Dermatol. 2018;63(6):465-8.
29. Chinatal P, Nishal A. A study of clinico-histopathological correlation in Hansen's disease. Int J Pathol. 2019;9:157-61.
30. Rekam A, Jyothi J. A study on clinical histopathological correlation in Hansen's disease. Int J Clin Biomed Res. 2016;2:10-2.