Section: ENT

Original Research Article

MANAGEMENT OF COMPLICATIONS OF CHRONIC OTITIS MEDIA AT A TERTIARY HEALTH CARE CENTRE

Anisha Ramola[1], Trupal Patel[2], Avinash Shah[3], Bela J Prajapati[4], Jyoti Dubey[5], Rhea Sisodia[5], Juganjyot Singh[6], Urvashi Kargatiya[7]

[1]*Senior Resident, Department of ENT, B. J. Medical College and Civil Hospital, Ahmedabad, Gujarat, India*
[2]*Assistant Professor, Department of ENT, B. J. Medical College and Civil Hospital, Ahmedabad, Gujarat, India*
[3]*Assistant Professor, Department of ENT, Government (CL&SC) Spine Institute & Hospital, Ahmedabad, Gujarat, India*
[4]*Additional Professor, Department of ENT, B. J. Medical College and Civil Hospital, Ahmedabad, Gujarat, India*
[5]*Third Year Resident, Department of ENT, B. J. Medical College and Civil Hospital, Ahmedabad, Gujarat, India*
[6]*Second Year Resident, Department of ENT, B. J. Medical College and Civil Hospital, Ahmedabad, Gujarat, India*
[7]*First Year Resident, Department of ENT, B. J. Medical College and Civil Hospital, Ahmedabad, Gujarat, India*

Received *: 28/09/2026*
Received in revised form *: 23/10/2026*
Accepted *: 06/11/2026*

Corresponding Author:
Dr. Trupal Patel,
Assistant Professor, Department of ENT, B. J. Medical College and Civil Hospital, Ahmedabad, Gujarat, India.
Email: dr.trupal89@gmail.com

DOI: 10.70034/ijmedph.2026.4.333

Source of Support: Nil,
Conflict of Interest: None declared

Int J Med Pub Health
2026; 16 (4); 2210-2218

ABSTRACT

Background: Complications of chronic otitis media (COM) remain clinically important despite advances in antimicrobial therapy and ear surgery. This study described the presentation, complication patterns, management and follow-up findings in a tertiary-care cohort.

Materials and Methods: This hospital-based ambispective observational study included 73 patients with complicated COM treated in the Department of Otorhinolaryngology, Civil Hospital, Ahmedabad, from October 2022 to March 2025. Clinical presentation, examination findings, microbiology, intracranial and extracranial complications, treatment and follow-up outcomes were summarized descriptively.

Results: Mean age was 31.48 ± 14.66 years (range, 7–85); 47 patients (64.4%) were male. Ear discharge occurred in 73 (100%), fever in 60 (82.2%) and headache in 29 (39.7%). The principal complication was extracranial in 44 patients (60.3%) and intracranial in 29 (39.7%). Postaural abscess was recorded in 15 (20.5%) and facial weakness in 14 (19.2%). Pseudomonas aeruginosa was isolated in four patients (5.5%). Management incorporated antibiotics, mastoid surgery and neurosurgical intervention when indicated.

Conclusion: Complicated COM was associated with substantial extracranial and intracranial disease in this referral cohort. Timely diagnosis and coordinated otologic and neurosurgical management were central to clinical care.

Keywords: Chronic Otitis Media, Intracranial Abscess, Extracranial complications, Mastoidectomy, Otorrhoea.

INTRODUCTION

Chronic otitis media (COM) is a persistent inflammatory condition of the middle ear characterized by permanent abnormalities of the pars tensa (mucosal COM) or pars flaccida (squamosal COM). These abnormalities commonly result from previous episodes of acute otitis media, persistent negative middle ear pressure, or otitis media with effusion. Complications of COM develop when the infection extends beyond the mucosal boundaries of the middle ear cleft into adjacent anatomical structures, resulting in extracranial or intracranial complications.[1,2]

Chronic suppurative otitis media (CSOM) remains a significant public health concern, particularly in developing countries. According to historical estimates by the World Health Organization (WHO), approximately 65–330 million individuals worldwide are affected by CSOM, nearly 50% of whom experience hearing impairment. Furthermore, approximately 28,000 deaths annually have been attributed to complications of otitis media. The high burden of disease in developing countries has been associated with poor socioeconomic conditions,

undernutrition, inadequate health education, overcrowding, and unhygienic practices.[3,4]

According to the WHO workshop on otitis media held in 1996, countries with a prevalence of 1%–2% were classified as having a low prevalence, whereas those with a prevalence of 3%–6% were categorized as having a high prevalence of CSOM. India has historically been reported to have a prevalence of approximately 5.2%, placing it within the high-prevalence category, although prevalence estimates vary across populations and geographical regions.[4,5]

Early diagnosis and timely surgical intervention are essential in the management of complicated COM to prevent potentially life-threatening consequences. A lack of awareness regarding the seriousness of the disease, delayed presentation, and inadequate access to specialized healthcare services may contribute to the development of complications. Appropriate medical management combined with timely surgical intervention, particularly mastoidectomy when indicated, plays an important role in controlling infection and reducing associated morbidity and mortality.[6–8] Present Study was done with an aim to describe the presentation, complication patterns, management and follow-up findings of Chronic Otitis Media in a tertiary-care cohort.

MATERIALS AND METHODS

This hospital-based ambispective observational study included 73 patients with complicated chronic otitis media who were admitted to the Department of Otorhinolaryngology, Civil Hospital, Ahmedabad, and received medical management, surgical management or both. The study covered October 2022 to March 2025.The study was reviewed and approved by the Institution Ethics Committee of B. J Medical College, Civil Hospital Ahmedabad with approval number 63/2025 and dated 18/03/2025. Written and informed consent was obtained.

Patient selection

Inclusion criteria

1. Clinically and/or radiologically diagnosed cases of Complicated Chronic otitis media willing for follow up after 6 months.
2. Written informed consent to participate in the study.

Exclusion criteria

1. Congenital facial paralysis.
2. Benign or malignant brain tumours coexisting with complicated COM.
3. Immunocompromised status.

Patients of either sex with squamosal-type COM and clinical evidence of a complication were eligible, subject to the above criteria. Written informed consent was obtained from enrolled participants.

Patients presenting to the ENT outpatient department or emergency department underwent clinical assessment, including history taking and examination, before admission for treatment.

For suspected intracranial involvement, assessment included:

- Otoscopy
- General and local examination
- Ophthalmic examination for fundoscopy to rule out Papilloedema.
- Urgent Neurosurgery reference was done simultaneously
- CECT brain

Patients with confirmed meningitis or intracranial abscess were initially managed in consultation with neurosurgery; mastoid exploration for clearance of the otologic disease was undertaken after neurosurgical assessment and clearance.

Additional preoperative assessments, as clinically appropriate, included:

- Routine blood investigations (Hemogram, Liver and Renal function test, Coagulation profile, Serology)
- Chest Xray and baseline ECG
- Aural swab for culture and sensitivity (if discharge present)
- Pure Tone Audiometry (if patient is stable)

Postoperative assessments were planned at one, three and six months; the results also report a two-week wound assessment. Confidentiality was maintained by assigning a unique identification number to each patient.

The treatment pathway prioritized stabilization, antimicrobial treatment, neurosurgical intervention when indicated, definitive otologic surgery and prevention of recurrence.[7,12,13]

RESULTS

The study period ended in March 2025. The following tables and figures present the recorded clinical characteristics, complications, management and follow-up findings. Descriptive values are reported as recorded in the source dataset; where hypothesis tests are displayed, the prespecified threshold for statistical significance was $p < 0.05$. A total of 73 patients were included. Age distribution of the patients is as follows in table 1.

Table 1: Age distribution of patients included in the study

Age(years) group	Frequency	Percentage
<=10	2	2.7
11-20	16	21.9
21-30	21	28.8
31-40	22	30.1
41-50	5	6.8
51-60	5	6.8
>60	2	2.7
Total	73	100

Minimum age of patient included in the study was 7 years and maximum were 85 years. Most of the patients in study were in the age group of 31-40 years.

Table 2: Gender distribution of patients included in the study

Gender	Frequency	Percent
Male	47	64.4
Female	26	35.6
Total	73	100

There were 47 male patients (64.4%) and 26 female patients (35.6%).

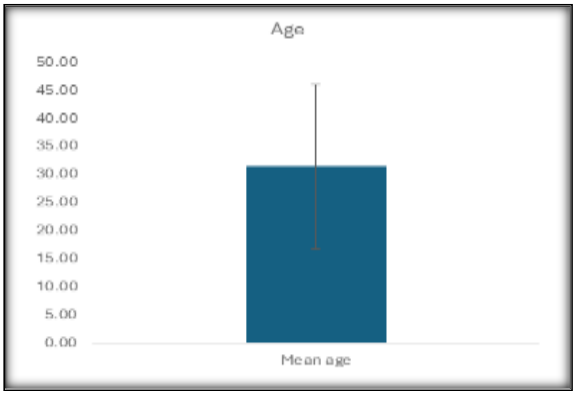

Figure 1: Mean Age of Study Participants

The mean age of our study was 31.48 years.

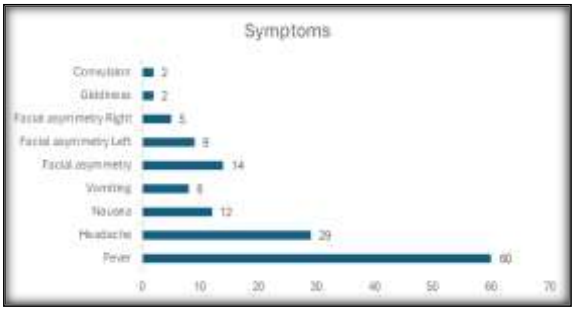

Figure 2: Symptom distribution in patients included in the study

Ear discharge was reported in all 73 patients (100%). Fever (60/73, 82.2%) and headache (29/73, 39.7%) were the next most frequent symptoms.

Table 3: CNS status of patients in the study

CNS symptoms	Number	Percentage
Within Normal Limits	68	93.2
Conscious, irritable	4	5.5
Drowsy	1	1.4
Total	73	100

Five patients (6.8%) had an altered level of consciousness or irritability at admission.

Table 4: Distribution of Otoscopic findings in patients included in the study

Otoscopic finding	Frequency	Percentage
Attic destruction	48	79.6
Attic destruction + Central perforation	1	1.4
Attic polyp, granulation, flakes	2	2.7
PSQ perforation, flakes	1	1.4
Attic retraction	3	4.1
Subtotal perforation, attic polyp	1	1.4
Otomastoid cavity, flakes	4	5.5
Central perforation, flakes	3	4.1
Total	73	100

Attic destruction was the most frequently recorded otoscopic finding.

Table 5: Distribution of Microorganisms isolated from patients included in the study

Aural swab CS Organism isolated	Frequency	Percent
No Organism Isolated	57	78.1
Acinetobacter baumnii	1	1.4
Acinetobacter sp.	1	1.4
CONS	2	2.7
Enterococcus sp.	1	1.4
Klebsiella sp.	1	1.4
Moraxella sp.	1	1.4
Proteus sp.	1	1.4
Pseudomonas aeruginosa	4	5.5
Staphylococcus aureus	3	4.1
Streptpcoccus pyogenes	1	1.4
Total	73	100

Among the 16 cases with a recorded organism, Pseudomonas aeruginosa (4/73, 5.5%) and Staphylococcus aureus (3/73, 4.1%) were most frequent. In the remaining 57 patients no organism was isolated.

Table 6: Distribution of type of complication in patients included in the study

Type of complication	Frequency	Percent
Intracranial	29	39.7
Extracranial	44	60.3
Total	73	100

The principal complication category was recorded as extracranial in 44 patients (60.3%) and intracranial in 29 patients (39.7%). There were 2 patients out of the total 73 in whom left sided facial paralysis was present along with left cerebellar abscess.

Only seven patients had Kernig's and Brudzinskis's sign positive.

Figure 3: Cerebellar signs

Cerebellar signs were documented in 16 patients in the figure (15 with multiple signs and one with ataxic gait only), corresponding to approximately 21.9%.

Papilloedema was documented in four patients (5.5%): one with grade 1 and three with grade 2 findings.

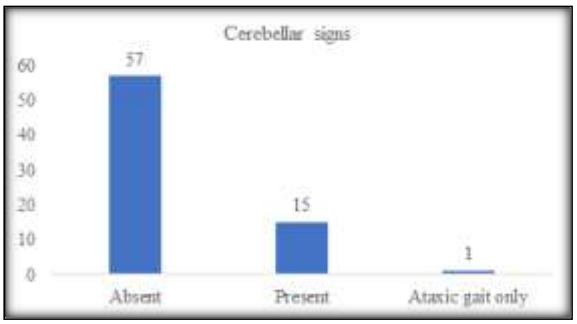

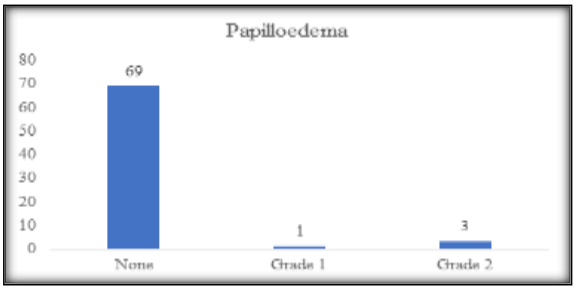

Figure 4: Fundoscopy findings

Table 7: Facial nerve paralysis distribution in the patients in study

Facial nerve paralysis grade	Frequency	Percent
No Facial Paralysis	59	80.8
Grade 3	1	1.4
Grade 4	9	12.3
Grade 5	3	4.1
Grade 6	1	1.4
Total	73	100

Preoperative facial nerve weakness was recorded in 14 patients (19.2%); two also had intracranial involvement.

Table 8: Distribution of Extracranial complications

Extracranial complication	Frequency	Percent
Postaural abscess	15	34
Preaural abscess	4	9
Bezold abscess	9	20.6
Facial nerve paralysis	14	32
Acute Labyrinthitis	1	2.2
Chronic suppurative labyrinthitis	1	2.2
Total	44	100

Postaural abscess was the most frequently recorded individual extracranial complication (15/73, 20.5%). Patients could have more than one extracranial complication.

Table 9: Distribution of Intracranial complications

Intracranial complication	Frequency	Percent
Cerebellar abscess	8	27.5
Cerebellar abscess IJV SS thrombosis	2	6.8
Cerebellar abscess SS thrombosis	1	3.4
Cerebellar abscess Meningitis	2	6.8
Cerebellar abscess Hydrocephalus	2	6.8
Lateral sinus thrombosis	1	3.4
Lateral sinus thrombophlebitis	5	17.2
Meningitis	3	10.3
Intracranial hypertension	1	3.4
Perisinus empyema	1	3.4
Subdural empyema tentorium cerebelli	1	3.4
PCF epidural empyema	2	6.8
Total	29	100

Cerebellar abscess, either alone or in combinationwith other intracranial findings, was frequently recorded.

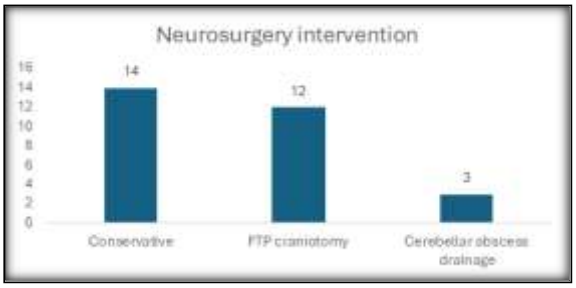

Figure 5: Neurosurgical intervention performed on patients included in study.

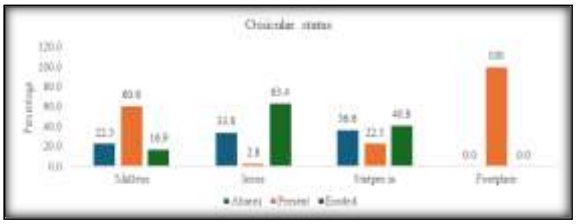

Figure 6: Ossicular status

The neurosurgical intervention figure shows 12 frontotemporal craniotomies and three cerebellar abscess drainages, alongside 14 conservatively managed cases.

The incus was the most commonly eroded ossicle (63.4%). The stapes was the most commonly absent ossicle (36.6%), while its footplate was preserved in all recorded cases.



Figure 7: Bone erosions

The mastoid cortex was frequently affected by erosion; lateral semicircular canal fistula was reported in 2.8% of patients. Granulation tissue was described over the facial canal (8.5%) and lateral semicircular canal (7%).

Table 10: Comparison of Type of complication with Age of patients included in the study

Age group	Type of complication			Pearson Chi-Square
	Intracranial	Extracranial	Total	P value
<=10	2	0	2	0.053
11-20	5	11	16	
21-30	12	9	21	
31-40	7	15	22	
41-50	0	5	5	
51-60	3	2	5	
>60	0	2	2	
Total	29	44	73	

The highest number of patients was in the 31–40-year age group. The reported association between age category and complication category did not meet the stated significance threshold (reported p = 0.053).

Table 11: Comparison of Complications type with Gender of patients included in the study

Gender	Cranial involvement			Pearson Chi-Square
	Intracranial	Extracranial	Total	P value
Male	19	28	47	0.91
Female	10	16	26	
Total	29	44	73	

Among 47 male patients, 19 had intracranial and 28 had extracranial complications; among 26 female patients, the corresponding counts were 10 and 16. No statistically significant association was reported (p = 0.91).

Table 12: Distribution of Post op follow up of patients in the study (2-week Post op follow up)

Post-op 2 week wound	Frequency	Percent
Not Healthy	3	4.1
Healthy	70	95.9
Total	73	100

The two-week follow-up table shows 70 healthy wounds. In three patients the wound was not healthy.

Table 13: One-month Post op follow up

One-month post-operative cavity	Frequency	Percent
Not Epithelized	3	4.1
Epithelized	70	95.9
Total	73	100

At one month, the follow-up table shows 70 epithelized cavities and three patients had non epithelized cavity

Table 14: Three-month Post op follow up

Three-month post-operative cavity	Frequency	Percent
Not epithelized	3	4.1
Epithelized	70	95.9
Facial weakness	14	19
Total	73	100

At three months, the table shows 70 epithelized cavities, three patient had non epithelized cavities. And in 14 patients with facial paralysis the weakness was reduced but did not return to normal.

Table 15: Six-month Post op follow up

Six months post-operative cavity	Frequency	Percent
Nt Epithelized	3	4.1
Epithelized	70	95.9
Total	73	100

The six-month, the table shows 70 epithelized cavities, three patients had non-epithelized cavities.



Figure 8: Facial Palsy Grade at 6 Month

At six months, the facial palsy Figure shows 11 patients with grade 1 and three with grade 2 findings.

DISCUSSION

The incidence of complications associated with chronic otitis media (COM) has declined considerably following the introduction of antibiotics, improvements in socioeconomic conditions, and advancements in healthcare facilities. Early diagnosis, appropriate antimicrobial treatment, and timely surgical intervention have contributed to reducing the morbidity and mortality associated with the disease. Nevertheless, complications of COM have remained an important clinical challenge in developing countries, where delayed presentation, inadequate awareness, and limited access to specialized healthcare facilities continue to influence disease outcomes.[3,4,6]

In the present study, the ages of the patients ranged from 7 to 85 years, with the highest proportion belonging to the 31–40-year age group. These findings were comparable to those reported by Mohite et al., who observed that the majority of affected patients belonged to the 35–55-year age group.[3] The male-to-female ratio in the present study was 2.3:1, indicating male predominance. Similarly, Basak reported a male predominance, with a male-to-female ratio of approximately 1.46:1.[5] Comparable patterns of male predominance have also been discussed in studies of otogenic complications by Bento et al. and Hussain and Khan.[9,10]

Most patients in the present study were labourers, farmers, students, and housewives, and a substantial proportion belonged to lower socioeconomic groups. Many patients presented with a prolonged history of ear discharge, suggesting delayed healthcare-seeking behaviour. Patients who developed intracranial complications frequently resided in remote rural areas where access to specialized medical facilities was limited. These findings were consistent with those of Mohite et al., who emphasized the role of delayed presentation and inadequate access to healthcare in the development of complications associated with COM.[3]

Otorrhoea was the most common presenting symptom and was observed in all patients (100%). This finding was comparable to the observations of Mohite et al., in whose study ear discharge was a prominent clinical feature.[3] Similarly, Borgohain and Saikia reported otorrhoea in 92% of patients, followed by earache in 60% and decreased hearing in 48%.[11] In the present study, patients with complications also presented with fever (82%), headache (40%), facial paralysis (19%), nausea (16%), vomiting (11%), and dizziness (3%). These findings highlighted the varied clinical presentation of complicated COM and emphasized the importance of identifying warning symptoms that may indicate extension of infection beyond the middle ear.

Altered sensorium was reported in 7% of patients and was observed in two cases of brain abscess associated with meningitis and one case of subdural empyema. Signs of meningeal irritation, including neck rigidity, Kernig's sign, and Brudzinski's sign, were also documented. Papilloedema was reported in 5.5% of patients, with three affected cases described. Similar clinical manifestations, particularly otorrhoea, headache, and fever, were reported by Mustafa et al., Raju et al., and Aslam and Al-Qahtani in patients with complications of chronic otitis media.[12–14]

These observations indicated that neurological manifestations in patients with chronic ear discharge should raise suspicion of intracranial involvement and warrant urgent evaluation.

Microbiological examination revealed sterile cultures in 57 cases, whereas bacterial growth was detected in the remaining 16 cases. Previous antibiotic exposure before presentation was a possible explanation for the high proportion of culture-negative specimens. Pseudomonas aeruginosa was the most commonly isolated organism (5.5%), followed by Staphylococcus aureus (4%). Other isolated organisms included coagulase-negative staphylococci, Streptococcus pyogenes, Enterococcus species, Klebsiella species, Moraxella species, Proteus species, and Acinetobacter species.

Mohite et al. also described culture-negative specimens among patients who had received intravenous antibiotics before microbiological sampling. In their study, Proteus mirabilis was isolated from four patients with intracranial complications, whereas Staphylococcus aureus, Pseudomonas species, and Escherichia coli were identified among patients with extracranial complications.[3] These findings demonstrated the diversity of microorganisms associated with complicated COM and reinforced the importance of microbiological assessment for guiding antimicrobial therapy.

In the present study, intracranial complications accounted for 40% of cases, whereas extracranial complications accounted for 60%. Extracranial complications were more frequent than intracranial complications. A similar distribution was observed by Mohite et al., who reported 14 cases of extracranial complications and six cases of intracranial complications among 20 patients.[3] The predominance of extracranial complications in both studies suggested that local extension of infection into adjacent extracranial structures was a frequent manifestation of complicated COM.

Brain abscess was the most common intracranial complication in the present study and accounted for 18 cases, representing approximately 24% of the total study population. Cerebellar abscesses, either occurring independently or in association with other intracranial complications, were particularly prominent. Postauricular subperiosteal abscess was the most common extracranial complication and was reported in approximately 20% of patients. Sharma et al. similarly reported brain abscess as an important intracranial complication and subperiosteal abscess as a common extracranial complication.[7] These findings emphasized the need for early recognition of both intracranial and extracranial disease extension.

All patients in the present study received medical management, including broad-spectrum intravenous antibiotics and topical antibiotic ear drops. Intravenous mannitol was administered to select patients with papilloedema, while oral anticoagulants were administered to patients diagnosed with intracranial venous sinus thrombosis. These interventions were combined with appropriate surgical management according to the type and severity of complications. Mohite et al. also emphasized the role of systemic antibiotic therapy and surgical intervention in the management of complicated COM.[3] Kirti and Yashveer similarly highlighted the importance of coordinated medical and surgical treatment, particularly in patients presenting with severe intracranial complications.[8]

Surgical management in the present study was individualized according to the site and extent of infection. Modified radical mastoidectomy (MRM) formed an important component of treatment, with additional procedures performed when required. Patients with cerebellar abscess underwent MRM combined with burr-hole drainage, whereas those with temporal lobe abscess underwent MRM with frontotemporoparietal craniotomy. Patients with meningitis received intravenous antibiotics along with mastoid surgery, while those with lateral sinus thrombosis received medical treatment, including antibiotics and anticoagulants, in addition to MRM. Extradural and subdural abscesses were managed using mastoidectomy combined with surgical drainage or excision as indicated.

For extracranial complications, patients with subperiosteal and Bezold abscesses underwent incision and drainage followed by MRM. Patients with labyrinthitis underwent mastoidectomy with adjunctive symptomatic medical treatment, whereas facial nerve paralysis was managed by MRM with facial nerve decompression in selected cases. These approaches were broadly comparable to those described by Mohite et al., although the specific surgical procedures varied according to the anatomical extent of infection and the clinical condition of the patient.[3] Mili et al. also described the importance of individualized surgical management in patients with complicated COM.[15]

Overall, the findings of the present study demonstrated that complicated COM continued to affect patients across a wide age range, particularly individuals from socioeconomically disadvantaged and rural populations. Otorrhoea remained the predominant presenting symptom, while fever, headache, neurological abnormalities, and facial nerve dysfunction were important indicators of complicated disease. Extracranial complications occurred more frequently than intracranial complications, with brain abscess and postauricular subperiosteal abscess representing important manifestations. The findings supported the importance of early diagnosis, appropriate antibiotic therapy, timely radiological assessment when indicated, and individualized surgical management to reduce the burden of complications associated with COM.[3,6–8]

Surgical management for each complication is stated and compared as follows:

Complication	Surgery performed in present study	Previous study	Surgery reported in comparison
Cerebellar abscess	MRM + burr-hole drainage	Mohite et al. [3]	Craniotomy followed by CWD mastoidectomy
Temporal lobe abscess	MRM + FTP craniotomy	Mohite et al. [3]	Craniotomy followed by CWD mastoidectomy
Meningitis	MRM + IV antibiotics	Mohite et al. [3]	IV antibiotics + CWD mastoidectomy
Lateral sinus thrombosis	MRM + IV antibiotics + oral anticoagulants	Mohite et al. [3]	Sinus exploration + CWD mastoidectomy
Extradural abscess	MRM + burr-hole drainage and abscess excision	Mohite et al. [3]	CWD mastoidectomy + IV antibiotics
Subdural abscess	MRM + burr-hole drainage and abscess excision	Mohite et al. [3]	CWD mastoidectomy + IV antibiotics
Subperiosteal abscess	Incision and drainage followed by MRM	Mohite et al. [3]	Incision and drainage followed by MRM
Bezold abscess	Incision and drainage followed by MRM	Mohite et al. [3]	Incision and drainage followed by MRM
Labyrinthitis	MRM + vestibular suppressants	Mohite et al. [3]	Lateral semicircular canal fistula repair + CWD mastoidectomy
Facial nerve paralysis	MRM + facial nerve decompression	Sarmah et al. [15]	Radical mastoidectomy + facial nerve decompression

CONCLUSION

The present study demonstrated that complications of chronic otitis media were predominantly observed among patients from lower socioeconomic backgrounds, particularly labourers, farmers, students, and housewives. Many patients with intracranial complications resided in rural areas with limited access to specialized healthcare facilities. The most commonly affected age group was 31–40 years, with a male-to-female ratio of 2.3:1. The ages of the affected patients ranged from 7 to 85 years. Otorrhoea was the most common presenting symptom (100%), with the majority of patients reporting ear discharge lasting for more than five years. Fever (82%) and headache (40%) were frequently associated with complicated cases. Neurological manifestations, including altered sensorium and drowsiness (7%), were associated with severe complications and an unfavourable prognosis, as two of the five patients presenting with altered sensorium succumbed to complications. Papilloedema was observed in 5.5% of patients and was an important indicator of raised intracranial pressure and severe intracranial involvement. Microbiological examination revealed bacterial growth in 16 patients, with Pseudomonas aeruginosa (5.5%) and Staphylococcus aureus (4%) being the most commonly isolated organisms. The remaining 57 patients had sterile cultures, possibly due to previous treatment with oral or topical antibiotics.

Extracranial complications accounted for 60% of cases, whereas intracranial complications accounted for 40%. Brain abscess (24%), predominantly involving the cerebellum, was the most common intracranial complication, while postauricular subperiosteal abscess (20%) was the most frequent extracranial complication. Contrast-enhanced computed tomography of the brain was an important imaging modality for detecting intracranial complications. Magnetic resonance imaging was performed in 28 of the 29 patients with intracranial complications and provided additional information regarding soft tissue involvement, meningeal enhancement, midline shift, and intracranial space-occupying lesions.

Management involved intravenous antibiotic therapy, modification of antimicrobial treatment based on culture and sensitivity findings, and appropriate surgical intervention. Patients with intracranial complications were managed in collaboration with the neurosurgical team. Modified radical mastoidectomy was the principal surgical procedure, aimed at eradicating the underlying disease and achieving a safe, dry ear. The findings emphasized the importance of early diagnosis, timely referral, appropriate imaging, effective antimicrobial therapy, and multidisciplinary surgical management in reducing the morbidity and mortality associated with complicated chronic otitis media. Improving healthcare accessibility and awareness, particularly among rural and socioeconomically disadvantaged populations, may help prevent delayed presentation and potentially life-threatening complications.

REFERENCES

1. Watkinson JC, Clarke RW, editors. Scott-Brown's otorhinolaryngology and head and neck surgery. 8th ed. Boca Raton (FL): CRC Press; 2018.
2. Gulya AJ, Minor LB, Poe DS, editors. Glasscock-Shambaugh surgery of the ear. 6th ed. Shelton (CT): People's Medical Publishing House; 2010.
3. Mohite AA, Mane RS, Patil BC, Mohanty RM. Complications of chronic suppurative otitis media and their management: five year study at tertiary care centre. Int J Otorhinolaryngol Head Neck Surg. 2019;5(4):900-905. doi:10.18203/issn.2454-5929.ijohns20192593.
4. Khairkar M, Deshmukh P, Maity H, Deotale V. Chronic suppurative otitis media: a comprehensive review of epidemiology, pathogenesis, microbiology, and complications. Cureus. 2023;15(8). doi:10.7759/cureus.43729.
5. Basak B, Biswas KD, Choudhary A, Biswas S. Socio-demography and clinico-pathological correlates of chronic otitis media: a tertiary care govt. hospital based epidemiological study in eastern India. J Med Sci Clin Res. 2019;7(6):124-132. doi:10.18535/jmscr/v7i6.24.
6. Dubey SP, Larawin V, Molumi CP. Complications of chronic suppurative otitis media and their management. Laryngoscope. 2007;117(2):264-267.

7. Sharma N, Jaiswal AA, Banerjee PK, Garg AK. Complications of chronic suppurative otitis media and their management: a single institution 12 years experience. Indian J Otolaryngol Head Neck Surg. 2015;67(4):353-360. doi:10.1007/s12070-015-0836-5.
8. Kirti YK, Yashveer JK. Dilemmas in current management of complicated chronic otitis media. Indian J Otolaryngol Head Neck Surg. 2019;71(2):155-160. doi:10.1007/s12070-018-1334-3.
9. Bento R, de Brito R, Ribas GC. Surgical management of intracranial complications of otogenic infection. Ear Nose Throat J. 2006;85(1):36-39. doi:10.1177/014556130608500111.
10. Hussain A, Khan AR. Frequency of intra cranial complications in chronic otitis media. J Ayub Med Coll Abbottabad. 2005;17(1):75-77.
11. Borgohain R, Saikia A. Complications of squamosal type of chronic otitis media- its management in a tertiary care centre. Int J Otorhinolaryngol Head Neck Surg. 2022;8(12):971-976. doi:10.18203/issn.2454-5929.ijohns20223046.
12. Mustafa A, Heta A, Kastrati B, Dreshaj S. Complications of chronic otitis media with cholesteatoma during a 10-year period in Kosovo. Eur Arch Otorhinolaryngol. 2008;265(12):1477-1482.
13. Raju AN, Rani TM, Ramesh K, Kumari AA. A clinical study on management of complications of chronic suppurative otitis media. Int J Pharm Clin Res. 2021;13(6):820-827.
14. Aslam W, Al-Qahtani A. Complications of otitis media. In: Al-Qahtani A, Haidar H, Larem A, editors. Textbook of clinical otolaryngology. Cham: Springer; 2021. p. 87-92.
15. Mili MK, Kalita S, Sarmah M, Talukdar S, Goswami S. Complications of chronic otitis media and their management: a study at tertiary care centre. Int J Res Med Sci. 2023;11(11):4082-4087. doi:10.18203/2320-6012.ijrms20233379.