Section: Ophthalmology

Original Research Article

OPTICAL COHERENCE TOMOGRAPHY ANGIOGRAPHY CHANGES IN PATIENTS WITH NEWLY DIAGNOSED HYPERTENSION WITHOUT RETINOPATHY

Sushil Kumar Kar[1]

[1]*Assistant Professor, Department of Ophthalmology, Hitech Medical College, Rourkela, Odisha, India.*

Received *: 02/10/2026*
Received in revised form *: 26/10/2026*
Accepted *: 10/11/2026*

Corresponding Author:
Dr. Sushil Kumar Kar,
Assistant Professor, Department of Ophthalmology, Hitech Medical College, Rourkela, Odisha, India.
Email: drsushilophthal@gmail.com

DOI: 10.70034/ijmedph.2026.4.332

Source of Support: Nil,
Conflict of Interest: None declared

Int J Med Pub Health
2026; 16 (4); 2204-2209

ABSTRACT

Background: Retinal microvascular abnormalities may precede clinically visible hypertensive retinopathy. Optical coherence tomography angiography (OCTA) enables noninvasive assessment of macular capillary density and foveal avascular zone (FAZ) area. The aim is to compare macular OCTA parameters in adults with newly diagnosed hypertension without visible retinopathy and normotensive controls.

Materials and Methods: This manuscript is structured as a prospective observational comparative study at Hi-Tech Medical College, Rourkela, Odisha, during August 2025–August 2026. One eye per participant is assessed at enrollment. Because study records were not provided, the example uses simulated measurements from 60 hypertensive participants and 60 controls. Superficial parafoveal vessel density is the primary outcome; deep vessel density and FAZ area are secondary outcomes. Mean differences, 95% confidence intervals and P values are shown solely to demonstrate reporting. The diagnostic threshold, treatment status, OCTA scan protocol, image-quality criteria, ethics approval and consent procedures remain to be verified against the study records before submission.

Results: In the simulated example, mean superficial vessel density was 46.4 ± 2.3% in the hypertension group and 49.1 ± 2.6% in controls (difference −2.68 percentage points; 95% CI −3.57 to −1.78; $P < 0.001$). Deep vessel density was 47.9 ± 3.2% versus 49.2 ± 3.2% (difference −1.33; 95% CI −2.49 to −0.18; $P = 0.024$). FAZ area was 0.335 ± 0.070 versus 0.282 ± 0.061 mm² (difference 0.053 mm²; 95% CI 0.029 to 0.077; $P < 0.001$).

Conclusion: These simulated results demonstrate a format for reporting early OCTA differences. They are not patient findings; clinical conclusions require verified participant data, imaging details and ethics information.

Keywords: Hypertension; optical coherence tomography angiography; retinal microcirculation; vessel density; foveal avascular zone; hypertensive retinopathy.

INTRODUCTION

Hypertension is a common source of injury to the microcirculation, and the retina is one of the few tissues in which living small vessels can be examined directly. Clinical fundoscopy identifies established hypertensive retinal signs such as arteriolar narrowing, arteriovenous changes, hemorrhage and exudation, but its normal appearance does not necessarily exclude earlier capillary alterations. The term newly diagnosed describes the date of clinical recognition, however, and does not prove that blood pressure was previously normal. Diagnostic timing and treatment exposure matter when interpreting retinal measurements.

Optical coherence tomography angiography (OCTA) produces depth-resolved images of the retinal and choroidal circulation by detecting changes between repeated optical coherence tomography scans. It requires no intravenous dye, permits repeat imaging, and separates the superficial and deep capillary plexuses. Common quantitative measures include vessel density or perfusion density, depending on the device algorithm, and the area of the foveal avascular

zone (FAZ). These are related but not interchangeable metrics: vessel density may quantify perfused vessel area or vessel length, whereas FAZ delineation depends on segmentation and image processing. Motion, low signal strength, projection artifacts and differences in scan size may materially influence estimates. Thus, a numerical OCTA result must be interpreted in light of the instrument and acquisition protocol.[1,2]

The biological rationale is plausible. Persistent elevation of systemic pressure can accompany endothelial dysfunction, altered autoregulation, arteriolar remodeling and capillary flow changes. Retinal capillaries may show an altered perfusion pattern before conventional examination identifies overt retinopathy. A study of adults with treated hypertension related deep vascular plexus capillary density to blood pressure and renal variables, while other work has reported relationships between microvascular measurements and inner retinal structure. Neither association alone shows that a low OCTA value is caused by hypertension, and shared vascular risk factors remain important alternative explanations.[3,4]

Clinical studies have examined the earliest visible stage from several angles. In a small case-control study that included people with a first diagnosis of hypertension, deep plexus vessel density and FAZ differed between groups. A separate study of patients with hypertension but without clinically evident retinopathy reported macular and optic nerve head OCTA changes; however, its hypertensive participants had disease durations of five years or longer. Another cohort assessed differing levels of blood pressure control in patients without hypertensive retinopathy. Together these reports support investigating subclinical retinal differences, while also showing why duration and medication exposure should not be conflated with a new diagnosis.[5–7]

Broader studies of essential or systemic hypertension have evaluated superficial and deep macular perfusion, peripapillary vessels and neural retinal layers. Their observations have not always agreed on the most affected plexus or region. Differences in participant age, hypertension severity, comorbidities, treated status, scan size and segmentation boundaries offer possible reasons. Studies that specifically enrolled untreated hypertensive participants are especially relevant to the newly diagnosed setting, although untreated status by itself does not establish the onset date of elevated blood pressure.[8–10]

Quantitative syntheses reinforce the need to specify a primary OCTA endpoint before looking at multiple sectors. One meta-analysis found lower superficial foveal and parafoveal vessel density among hypertensive participants and a larger deep plexus FAZ, with heterogeneity. Another synthesis found reductions in both superficial and deep macular vessel density, but pooled estimates may not apply directly to one clinic population. A study of retinal microvascular changes in chronic hypertension further illustrates the role of disease stage.[11–13]

Recent work has examined vascular responsiveness and compared different OCTA analytical approaches, emphasizing that a static vessel-density value is not a direct measurement of absolute blood flow and that processing methods can change estimates. Standardized quality control and a defined unit of analysis are consequently necessary for credible comparisons.[14,15] People seen close to their first hypertension diagnosis, with no clinically visible retinopathy, may differ from long-standing cohorts in exposure duration and treatment history. This study was designed to compare macular OCTA measurements in such patients with those in normotensive adults and to explore relationships with measured blood pressure. The prespecified primary outcome should be the parafoveal superficial plexus vessel density; deep plexus density and FAZ area are secondary outcomes. All numerical examples are simulated and require replacement with study data.

MATERIALS AND METHODS

Design, site and study period: This was designed as a prospective observational comparative study of adults with newly diagnosed hypertension without visible retinopathy and contemporaneously recruited normotensive controls. Eligible participants would be enrolled prospectively and undergo one standardized blood pressure and OCTA assessment at enrollment; no longitudinal OCTA follow-up is assumed. The stated recruitment period is August 2025 through August 2026 at Hi-Tech Medical College, Rourkela, Odisha. Confirm whether Bargarh was an additional recruitment or imaging site before submission.

Inclusion criteria

1. Adults aged 18 years or older.
2. Patients with a first diagnosis of primary hypertension, confirmed according to the study's blood pressure assessment protocol, for the hypertension group.
3. Adults with no history of hypertension and normal blood pressure at assessment for the control group.
4. No visible hypertensive retinopathy on retinal examination.
5. A gradable macular optical coherence tomography angiography image from the eye selected for analysis.

Exclusion criteria

1. Diabetes mellitus or another systemic disease known to affect the retinal microvasculature.
2. Retinal vascular or macular disease that could alter the measured OCTA parameters.
3. Glaucoma or optic nerve disease.
4. Previous retinal surgery or refractive error outside the limits specified in the study protocol.
5. Media opacity or OCTA scans with poor signal strength, motion artifact or segmentation error that prevented reliable measurement.

Blood pressure and ocular assessment: Record age, sex, body mass index, smoking, comorbidities, medication use and the time from first diagnosis to OCTA. State blood pressure instrument, cuff size, rest period, number of repeated measurements and use of office versus home or ambulatory readings. Describe visual acuity, refraction or axial length, intraocular pressure, and dilated fundus assessment. Confirm whether graders were masked to clinical group.

OCTA protocol and outcomes: Specify the OCTA manufacturer, model, software version, macular scan size, segmentation boundaries and image quality threshold. The suggested primary endpoint is parafoveal superficial capillary plexus vessel density (%). Secondary endpoints are deep plexus parafoveal vessel density (%) and FAZ area (mm^2); include optic disc measures only if acquired. A trained reader should review motion, projection and segmentation artifacts and reject or correct scans using documented criteria. These are proposed reporting fields rather than assertions about procedures completed.

Sample size: The sample size was calculated for the primary outcome, parafoveal superficial capillary plexus vessel density. Assuming a between-group difference of 1.5 percentage points and a common standard deviation of 2.9 percentage points, a two-sided significance level of 0.05 and 80% power, the calculated minimum was 59 participants per group. This was rounded to 60 participants per group, giving a total target sample of 120 participants. One eligible eye per participant was included in the analysis.

Statistical analysis: Statistical analyses were performed using IBM SPSS Statistics, version 26.0 (IBM Corp., Armonk, NY, USA). One eye per participant was included in the analysis. Continuous variables were summarized as mean ± standard deviation or median with interquartile range, according to their distribution; categorical variables were reported as frequencies and percentages. The primary outcome was parafoveal superficial capillary plexus vessel density. Mean OCTA measurements were compared between the hypertension and control groups using Welch's independent-samples t test. Between-group mean differences were reported with 95% confidence intervals. Deep parafoveal vessel density and foveal avascular zone area were secondary outcomes, and their P values were interpreted as exploratory. All tests were two-sided, with $P < 0.05$ considered statistically significant for the primary outcome. The number of missing measurements and scans excluded because of inadequate image quality was reported for each group.

Ethics: The study was conducted after approval from an institutional ethics committee. Written informed consent was obtained from all participants before enrollment and ocular imaging. Participant information was de-identified for analysis, and confidentiality was maintained throughout the study.

RESULTS

This worked example contains 120 hypothetical participants, with one eligible eye per person: 60 in the newly diagnosed hypertension group and 60 normotensive controls. No screening or exclusion counts, missing scan counts or actual patient records were supplied. Accordingly, a participant flow figure and recruitment rate cannot be reported. All values below reproduce the synthetic [Table 1 and 2] and must be replaced before submission.

In [Table 1], the simulated hypertension group was older on average than controls (48.5 ± 8.6 versus 44.7 ± 7.0 years). Mean systolic blood pressure was 151.4 ± 9.2 versus 117.2 ± 7.7 mmHg, and mean diastolic blood pressure was 95.6 ± 6.8 versus 74.4 ± 4.9 mmHg. These descriptive values establish only the example group profile; the age difference would require consideration in a real adjusted analysis.

The illustrative primary endpoint, superficial parafoveal vessel density, averaged 46.4 ± 2.3% in the hypertension group and 49.1 ± 2.6% in controls (mean difference −2.68 percentage points; 95% CI −3.57 to −1.78; $P < 0.001$). Deep parafoveal vessel density was 47.9 ± 3.2% versus 49.2 ± 3.2% (difference −1.33 percentage points; 95% CI −2.49 to −0.18; $P = 0.024$). FAZ area was 0.335 ± 0.070 versus 0.282 ± 0.061 mm^2 (difference 0.053 mm^2; 95% CI 0.029 to 0.077; $P < 0.001$). These unadjusted comparisons appear in [Table 2]. The secondary P values are exploratory and have not been corrected for multiple comparisons.

An exploratory description of the simulated hypertension group by systolic blood pressure at imaging is provided in [Table 3]. In this example, 25 participants had a reading below 150 mmHg and 35 had a reading of at least 150 mmHg. The superficial vessel-density means were 47.3 ± 2.2% and 45.8 ± 2.2%, respectively. This post hoc threshold is for illustration only; no subgroup inference or clinical threshold is proposed.

Table 1: Baseline characteristics of the simulated hypertension and control groups

Characteristic	Hypertension (n = 60)	Control (n = 60)
Age (years)	48.5 ± 8.6	44.7 ± 7.0
Systolic pressure (mmHg)	151.4 ± 9.2	117.2 ± 7.7
Diastolic pressure (mmHg)	95.6 ± 6.8	74.4 ± 4.9

Note: Values are mean ± standard deviation. The groups and measurements are simulated examples, not participant data.

[Figure 1] displays the simulated superficial and deep vessel-density means, while [Figure 2] displays simulated FAZ area; error bars represent standard deviations. Both figures use the same synthetic

dataset as [Table 2]. No adjusted estimates, pressure–OCTA correlations or image-quality exclusions can be reported without the actual dataset. None of these illustrative differences is evidence of a clinical effect in participants at the stated study site.

Table 2: Simulated comparison of macular OCTA parameters between groups

OCTA parameter	Hypertension (n = 60)	Control (n = 60)	Mean difference (95% CI)	P value
Superficial parafoveal vessel density (%)	46.4 ± 2.3	49.1 ± 2.6	−2.68 (−3.57 to −1.78)	<0.001
Deep parafoveal vessel density (%)	47.9 ± 3.2	49.2 ± 3.2	−1.33 (−2.49 to −0.18)	0.024
Foveal avascular zone (mm²)	0.335 ± 0.070	0.282 ± 0.061	0.053 (0.029 to 0.077)	<0.001

Note: Values are mean ± standard deviation. Differences are hypertension minus control; 95% confidence intervals and P values are from the illustrative Welch comparisons. Vessel-density differences are in percentage points; the FAZ-area difference is in mm². Secondary-endpoint P values are exploratory and unadjusted. All values are simulated, not participant data. CI, confidence interval; FAZ, foveal avascular zone; OCTA, optical coherence tomography angiography.

Table 3: Simulated OCTA parameters by systolic blood pressure in the hypertension group

Characteristic	Systolic BP <150 mmHg (n = 25)	Systolic BP ≥150 mmHg (n = 35)
Systolic blood pressure (mmHg)	143.0 ± 4.7	157.4 ± 6.5
Diastolic blood pressure (mmHg)	95.0 ± 6.7	96.0 ± 7.0
Superficial parafoveal density (%)	47.3 ± 2.2	45.8 ± 2.2
Deep parafoveal density (%)	47.4 ± 3.1	48.2 ± 3.3
Foveal avascular zone (mm²)	0.326 ± 0.065	0.341 ± 0.073

Note: Values are mean ± standard deviation. The 150 mmHg systolic BP split is illustrative and post hoc; no subgroup P values were calculated. All values are simulated, not participant data. BP, blood pressure; FAZ, foveal avascular zone; OCTA, optical coherence tomography angiography.

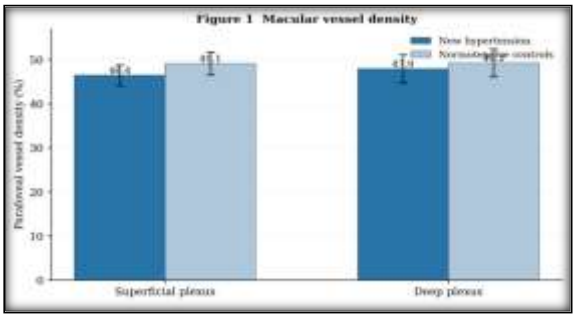

[Figure 1] Simulated mean parafoveal vessel density in the superficial and deep capillary plexuses. Error bars show standard deviation. The values are synthetic and are not scans or measurements from study participants.

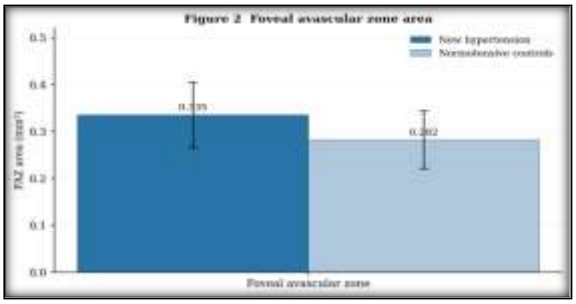

[Figure 2] Simulated mean FAZ area in the two example groups. Error bars show standard deviation. The chart is generated from synthetic values and must be replaced with real results.

DISCUSSION

The illustrative analysis shows lower superficial parafoveal vessel density and a larger FAZ area in the simulated newly diagnosed hypertension group than in simulated normotensive controls. They are generated examples, not observations from participants at the study institution. No empirical inference or claim of statistical significance about this clinical cohort can be drawn from them. Replace this paragraph with the observed effect size and confidence interval.

The general comparison is motivated by a body of observational evidence. Chua and colleagues described retinal capillary measurements in adults with treated hypertension; work relating retinal microvascular metrics to ganglion cell-inner plexiform layer thickness suggests that vascular and neural measurements can be considered together, while not establishing their sequence.[3,4] Donati and colleagues included participants with newly identified hypertension, making their observations particularly relevant to the intended population. Hua and colleagues described abnormalities in patients without visible hypertensive retinopathy, but those patients had longer recorded disease duration. Their findings therefore support a rationale for early assessment without establishing the result of the present study.[5,6]

Duration and control of blood pressure complicate comparison across studies. Newly diagnosed hypertension may have been present for months or years before its recognition. Reports comparing intensive, standard and poor blood pressure control, as well as studies in untreated essential hypertension, suggest that these variables deserve separate description.[7,10] The eventual analysis should state whether diagnosis was confirmed using repeated office readings or out-of-office measurements, report the interval between diagnosis and OCTA, and present treatment exposure before imaging.

Anatomic interpretation also requires restraint. OCTA detects motion contrast from flowing blood cells and depicts perfused vascular structures within an algorithm-defined slab. A reduction in measured vessel density may reflect slower flow below the detection threshold, segmentation error or optical signal attenuation as well as structural capillary rarefaction. FAZ boundaries can vary with image quality, magnification and software. The superficial and deep plexuses have different anatomical definitions across devices, and projection artifacts can influence deep images.[1,2,11-15] For this reason, the final report should name the exact instrument and software, scan dimensions, quality threshold, segmentation boundaries, eye selection rule and whether image graders were masked. The charted values must be interpreted in the units generated by that particular instrument.

Two published meta-analyses broadly support lower retinal vessel density in hypertension, but their plexus-specific estimates are not identical and several comparisons showed heterogeneity.[11,12] This is a reason to emphasize one prespecified primary measure and its confidence interval, then treat regional and FAZ findings as secondary. A result confined to the deep plexus, for example, should not be portrayed as a uniform loss across the entire retina. Conversely, the absence of a detectable difference in one sector does not establish that early hypertension has no retinal effects. Assessment of age, sex, axial length, smoking, diabetes exclusion, image signal strength and medication use is necessary before a difference can be attributed plausibly to hypertensive status.

Other studies have assessed retinal microvascular changes across chronic hypertension, visual retinopathy status and vascular responsiveness.[8,9,13,14] The comparison with these cohorts should use the actual age range, diagnostic criteria, duration and device from the completed study. If both eyes are included, account for within-person correlation. Adjustment should be specified before inspecting results, and the report should avoid presenting a large collection of uncorrected sector comparisons as independent confirmatory findings.

The clinical value of OCTA remains to be determined. A group-level difference does not show that an OCTA threshold diagnoses hypertension, predicts cardiovascular events, identifies target-organ damage elsewhere, or warrants changing medication. Those applications would require externally validated diagnostic or longitudinal prognostic studies, calibrated devices and evidence that the result changes decisions or outcomes. Repeat imaging after documented blood pressure control could help distinguish a stable structural alteration from a perfusion-related signal, provided follow-up timing, treatment and scan quality are handled consistently. Until then, the final conclusion should describe a retinal imaging association within the sampled population rather than a screening recommendation. For interpretation of completed results, show the absolute group difference beside the baseline distribution and consider a sensitivity analysis restricted to treatment-naive patients if their number is sufficient. Such analyses should be declared exploratory if they were not prespecified.

The present manuscript has a specific interim limitation beyond the ordinary limits of a single-centre prospective observational study: its Results, tables and figures currently contain simulated data. Ethical approval, consent, recruitment, exclusions, imaging settings and sample size calculation have not been verified from source documents. These details must be reconciled with the actual protocol. Bargarh was also mentioned as a possible study location whereas Hi-Tech Medical College, Rourkela was identified as the study institution; the setting must be confirmed before submission. A scientifically complete article requires de-identified participant-level or verified aggregate data, the actual OCTA outputs and the final statistical analysis. Transparent reporting of the completed cohort and analysis should follow STROBE guidance.[16]

Strengths: The proposed framework focuses on early diagnosis, excludes visible retinopathy and prespecifies one primary OCTA measure. Standardized acquisition, masked grading and a contemporaneous control group would strengthen a completed study if they were in fact used. These features must be checked against the protocol.

Limitations: The present numeric analysis is entirely simulated and has no inferential value. The final prospective observational study may also be limited by a single center, modest sample, unknown duration of previously unrecognized hypertension, differences in axial length and image quality, and residual confounding. A prospective recruitment design with a single OCTA time point still cannot establish causation or improvement after treatment. Confirm these limits against the actual data and methods.

CONCLUSION

OCTA can assess retinal microcirculation in newly diagnosed hypertension without visible retinopathy. The illustrative comparisons show how superficial and deep vessel density and foveal avascular zone area may be reported. These numbers are generated examples and cannot establish a clinical association. Interpretation of this prospective cohort requires verified participant data. Longitudinal studies should test whether OCTA measures change with blood pressure control or predict outcomes.

REFERENCES

1. Spaide RF, Fujimoto JG, Waheed NK. Optical coherence tomography angiography. Prog Retin Eye Res. 2018;64:1–55. doi:10.1016/j.preteyeres.2017.07.002. PMID:28760677.
2. Onishi AC, Fawzi AA. An overview of optical coherence tomography angiography and the posterior pole. Ther Adv Ophthalmol. 2019;11:2515841419840249. doi:10.1177/2515841419840249. PMID:30984909.

3. Chua J, Chin CWL, Hong J, et al. Impact of hypertension on retinal capillary microvasculature using optical coherence tomographic angiography. J Hypertens. 2019;37:572–580. doi:10.1097/HJH.0000000000001916. PMID:30113530.
4. Lim HB, Lee MW, Park JH, et al. Changes in ganglion cell-inner plexiform layer thickness and retinal microvasculature in hypertension: an optical coherence tomography angiography study. Am J Ophthalmol. 2019;199:167–176. PMID:30502337.
5. Donati S, Maresca AM, Cattaneo J, et al. Optical coherence tomography angiography and arterial hypertension: a role in identifying subclinical microvascular damage? Eur J Ophthalmol. 2021;31(1):158–165. doi:10.1177/1120672119880390. PMID:31617414.
6. Hua D, Xu Y, Zeng X, et al. Use of optical coherence tomography angiography for assessment of microvascular changes in the macula and optic nerve head in hypertensive patients without hypertensive retinopathy. Microvasc Res. 2020;129:103969. doi:10.1016/j.mvr.2019.103969. PMID:31874131.
7. Hua D, Xu Y, Zhang X, et al. Retinal microvascular changes in hypertensive patients with different levels of blood pressure control and without hypertensive retinopathy. Curr Eye Res. 2021;46(1):107–114. doi:10.1080/02713683.2020.1775260. PMID:32498561.
8. Peng Q, Hu Y, Huang M, et al. Retinal neurovascular impairment in patients with essential hypertension: an optical coherence tomography angiography study. Invest Ophthalmol Vis Sci. 2020;61(8):42. doi:10.1167/iovs.61.8.42. PMID:32725211.
9. Sun C, Ladores C, Hong J, et al. Systemic hypertension associated retinal microvascular changes can be detected with optical coherence tomography angiography. Sci Rep. 2020;10:9580. doi:10.1038/s41598-020-66736-w. PMID:32533105.
10. Xu Q, Sun H, Huang X, Qu Y. Retinal microvascular metrics in untreated essential hypertensives using optical coherence tomography angiography. Graefes Arch Clin Exp Ophthalmol. 2021;259(2):395–403. doi:10.1007/s00417-020-04714-8. PMID:32613576.
11. Anjos R, Ferreira A, Barkoudah E, Claggett B, Abegão Pinto L, Miguel A. Application of optical coherence tomography angiography macular analysis for systemic hypertension: a systematic review and meta-analysis. Am J Hypertens. 2022;35:356–364. doi:10.1093/ajh/hpab172. PMID:34718393.
12. Tan WT, Yao X, Le TT, et al. The application of optical coherence tomography angiography in systemic hypertension: a meta-analysis. Front Med (Lausanne). 2021;8:778330. doi:10.3389/fmed.2021.778330. PMID:34859021.
13. Lee WH, Park JH, Won Y, et al. Retinal microvascular change in hypertension as measured by optical coherence tomography angiography. Sci Rep. 2019;9:156. doi:10.1038/s41598-018-36474-1. PMID:30655557.
14. Zeng R, Garg I, Bannai D, et al. Retinal microvasculature and vasoreactivity changes in hypertension using optical coherence tomography-angiography. Graefes Arch Clin Exp Ophthalmol. 2022;260:3505–3515. doi:10.1007/s00417-022-05706-6. PMID:35678840.
15. Courtie E, Kirkpatrick JRM, Taylor M, et al. Optical coherence tomography angiography analysis methods: a systematic review and meta-analysis. Sci Rep. 2024;14:9643. doi:10.1038/s41598-024-54306-3. PMID:38670997.
16. von Elm E, Altman DG, Egger M, et al. The Strengthening the Reporting of Observational Studies in Epidemiology (STROBE) statement: guidelines for reporting observational studies. PLoS Med. 2007;4:e296. doi:10.1371/journal.pmed.0040296.