



Original Research Article

ROLE OF MULTIDETECTOR CT IN EVALUATION OF MASTOIDITIS AND RELATED PATHOLOGIES WITH CLINICAL AND SURGICAL CORRELATION

Madhavi Thatipamula¹, Ankadi Shywini Kumari², Manikonda Raghavender Reddy³, G G L Sravya⁴

¹Associate Professor, Department of Radiology, Bhaskar Medical College, Moinabad Mandal, R.R. District, Hyderabad, Telangana State, India.

²Assistant Professor, Department of Radiology, Bhaskar Medical College, Moinabad Mandal R.R. District, Hyderabad, Telangana State, India.

³Assistant Professor, Department of Radiology, Bhaskar Medical College, Moinabad Mandal R.R. District, Hyderabad, Telangana State, India.

⁴Senior Resident, Department of Radiology, Gandhi Medical College, Secunderabad, Telangana, India.

Received : 12/03/2026
Received in revised form : 04/05/2026
Accepted : 19/05/2026

Corresponding Author:

Dr. G G L Sravya,
Senior Resident, Department of
Radiology, Gandhi Medical College,
Secunderabad, Telangana, India.
Email: gglsravya@gmail.com

DOI: 10.70034/ijmedph.2026.2.462

Source of Support: Nil,
Conflict of Interest: None declared

Int J Med Pub Health
2026; 16 (2); 2793-2802

ABSTRACT

Background: Mastoiditis and chronic middle ear pathologies remain significant causes of hearing impairment and intracranial complications. Accurate preoperative assessment is essential for disease characterization, surgical planning, and prevention of complications. Multidetector computed tomography (MDCT) plays a vital role in evaluating temporal bone anatomy and disease extent.

Materials and Methods: This prospective observational study included 50 patients clinically suspected of mastoid pathology. All patients underwent detailed clinical evaluation, audiological assessment, and MDCT temporal bone imaging followed by surgical correlation where indicated. CT findings related to mastoid air cells, middle ear cavity, ossicular chain, scutum, facial canal, and associated complications were analyzed statistically.

Results: The most affected age group was 31–40 years (34%) with slight female predominance (54%). Conductive hearing loss was the most common audiological finding (76%). MDCT demonstrated mastoid sclerosis with soft tissue opacification in 58% and middle ear cavity soft tissue in 84% of patients. Scutum abnormalities were observed in 28%, while ossicular erosion was identified in 32%, predominantly involving the malleus and incus. Facial canal dehiscence was noted in 12% of cases. Cholesteatoma and granulation tissue represented major intraoperative findings. Tympanic membrane perforation was present in all patients, with subtotal perforation being the commonest type (32%). Significant radiologic–surgical correlation was observed for mastoid pathology, cholesteatoma, and ossicular erosion ($p < 0.001$).

Conclusion: MDCT is a highly valuable imaging modality for evaluating mastoid diseases and chronic otitis media. It provides excellent delineation of disease extent, ossicular involvement, facial canal status, and anatomical variations, thereby improving surgical planning and reducing operative complications.

Keywords: Mastoiditis; Multidetector Computed Tomography (MDCT); Chronic Otitis Media; Cholesteatoma; Temporal Bone Imaging; Ossicular Erosion; Mastoid Air Cells; Facial Canal Dehiscence; Middle Ear Pathology; Radiologic–Surgical Correlation.

INTRODUCTION

Mastoiditis is an infection that involves inflammation of the mastoid bone, often a result of untreated or inadequately treated middle ear infections. It can cause significant morbidity and, if left unrecognized

or untreated, may lead to complications such as abscess formation, hearing loss, meningitis, or even sepsis.^[1] With the advancement of medical imaging techniques, multidetector computed tomography (MDCT) has emerged as a critical tool in evaluating mastoiditis and related pathologies, offering a non-

invasive, rapid, and highly detailed assessment of the temporal bone structures. Its ability to provide cross-sectional imaging with high spatial resolution has revolutionized the approach to diagnosing and managing such conditions, allowing for precise visualization of bone and soft tissue involvement.^[1,2] The clinical presentation of mastoiditis typically includes ear pain, discharge, hearing loss, fever, irritability but the symptoms can vary depending on the severity and progression of the disease. In many cases, mastoiditis occurs as a complication of acute otitis media, with the infection extending from the middle ear to the mastoid air cells. This extension if not treated in a timely manner, may progress to other complications, including intracranial involvement. Thus, early and accurate diagnosis is essential, and MDCT plays a key role in confirming the diagnosis, determining the extent of the disease, and guiding treatment strategies.^[2,3]

MDCT is a particularly valuable imaging modality for evaluating temporal bone pathologies, including mastoiditis, due to its excellent resolution of bony structures and its ability to detect subtle osseous changes.^[3] The high spatial resolution of MDCT allows for detailed visualization of the mastoid air cells, the middle ear, and the surrounding structures. The degree of mastoid air cell opacification can be assessed, which is a key indicator of inflammation and infection. Additionally, MDCT can identify the presence of a cholesteatoma, which may be associated with chronic mastoiditis. The role of MDCT in evaluating mastoiditis is not limited to its diagnostic capabilities; it also plays a significant role in monitoring disease progression and assessing the effectiveness of treatment. The ability to assess post-treatment changes allows clinicians to monitor the success of therapy and adjust management as needed.^[4,5]

If a patient presents with classic signs of mastoiditis, such as ear pain, discharge and swelling, along with a history of untreated or inadequately treated otitis media, MDCT may be ordered to confirm the diagnosis and assess the severity of the condition.^[5,6] The imaging findings, such as mastoid air cell opacification, bone destruction, and the presence of abscesses, can help determine whether the infection is localized or if there is any intracranial extension or

involvement of adjacent structures, such as the facial nerve.^[6]

Furthermore, MDCT plays a crucial role in the multidisciplinary approach to mastoiditis management, involving otolaryngologists, radiologists, and surgeons. In severe cases, where surgical intervention is indicated, the surgeon can use the MDCT findings to plan the procedure and minimize the risk of complications.^[6] In a good sample size, with the clinical suspicion of mastoiditis is made, with MDCT the spectrum of the mastoiditis and related pathologies can be detected, and with surgical findings, we can correlate the radiological pathologies clinically & surgically, and we can know the efficiency of MDCT in detecting the mastoid pathologies.

MATERIALS AND METHODS

Type of study: Cross-sectional observational study.

Place of study: This study was conducted in the patients referred for CT mastoid to the Department of Radio-diagnosis in Bhaskar Medical College & General Hospital over a period of 18 months.

Inclusion Criteria: All patients referred to the department of radio diagnosis for CT mastoid.

Exclusion Criteria: Pregnant women, Postoperative cases of mastoidectomy.

Study Period: 18 months

Sample Size: 50 cases were taken up for study.

Informed consent was taken from patient/guardian.

CT Protocol

CT mastoid was performed on Toshiba Alexion 16 slice multidetector CT scanner using following protocol.

The study was conducted with subject in supine position with the breath held.

High resolution serial 1 mm thick reconstructions were obtained in axial, sagittal and coronal planes using VITREA workstation on TOSHIBA software.

Contrast enhanced CT was done when required.

The study was approved by the ethical committee of the institute.

Statistical Analysis: Chi-Square test was used to compare the correlation between CT and surgical findings. A p- value of < 0.001 was considered to indicate a statistical significance.

RESULTS

Table 1: Demographic profile and clinical characteristics of the study population

Variable	Frequency (n=50)	Percentage (%)
Age Group (Years)		
0–10	1	2.0
11–20	3	6.0
21–30	16	32.0
31–40	17	34.0
41–50	10	20.0
51–60	3	6.0
Gender		
Female	27	54.0
Male	23	46.0
Side of Involvement		

Bilateral	8	16.0
Left	29	58.0
Right	13	26.0
Clinical Symptoms		
Discharge with Hearing Loss	23	46.0
Pain with Discharge	14	28.0
Pain, Discharge and Hearing Loss	13	26.0
Type of Hearing Loss		
Conductive	38	76.0
Mixed	12	24.0

The majority of patients were between 21–40 years of age (66%), with the highest frequency observed in the 31–40 year age group. A slight female predominance was noted. Left-sided disease was more common than right-sided disease, and

conductive hearing loss was the predominant audiological abnormality. Ear discharge associated with hearing loss was the most frequent clinical presentation.

Table 2: Overall spectrum of CT findings in mastoid pathology

CT Finding	Frequency	Percentage (%)
Mastoid opacification/sclerosis	44	88.0
Middle ear cavity soft tissue	42	84.0
Ossicular erosion	14	28.0
Scutum abnormality	14	28.0
Facial canal dehiscence	7	14.0
Bone erosion	4	8.0

Mastoid opacification/sclerosis was the most common CT finding, followed by middle ear cavity soft tissue opacification. Ossicular erosion and scutum abnormalities were identified in over one-

fourth of patients, while facial canal and bony erosions were less frequent but clinically significant findings.

Table 3: MDCT evaluation of mastoid air cells, EAC, middle ear cavity, and scutum

Parameter	Frequency	Percentage (%)
Mastoid Air Cells		
Normal	6	12.0
Sclerosed with Soft Tissue	29	58.0
Soft Tissue Opacification	15	30.0
External Auditory Canal (EAC)		
Normal	44	88.0
Abnormal	6	12.0
Middle Ear Cavity Appearance		
Normal	8	16.0
Soft Tissue	42	84.0
Predominant location in Middle Ear Cavity		
Epitympanum	20	40.0
Mesotympanum	24	48.0
Hypotympanum	8	16.0
Scutum Status		
Normal	36	72.0
Blunted	8	16.0
Eroded	6	12.0

Sclerosed mastoid air cells with soft tissue opacification represented the predominant mastoid pattern, reflecting chronic inflammatory changes. Most patients demonstrated normal EAC appearance, whereas middle ear soft tissue opacification was

identified in the majority of cases, particularly within the mesotympanum. Scutum abnormalities were present in 28% of patients, indicating possible cholesteatomatous disease.

Table 4: MDCT assessment of ossicular erosion and adjacent temporal bone structures

Parameter	Frequency	Percentage (%)
Ossicular Erosion		
Normal	36	72.0
Erosion of Malleus	2	4.0
Erosion of Malleus and Incus	7	14.0
Erosion of Incus	4	8.0
Erosion of Malleus, Incus, and Stapes	1	2.0
Prussack's Space		
Normal	32	64.0

Soft Tissue	18	36.0
Facial Canal Status		
Normal	43	86.0
Eroded	7	14.0
Sinus Tympani		
Normal	42	84.0
Soft Tissue	8	16.0
Bony Erosion		
Normal	46	92.0
Tegmen Tympani Erosion	2	4.0
Tegmen Mastoid Erosion	2	4.0

Combined malleus and incus erosion was the most common ossicular abnormality. Prussak's space involvement and sinus tympani soft tissue suggested

cholesteatomatous extension in a subset of patients. Facial canal and tegmen erosions, though less frequent, have important surgical implications.

Table 5: MDCT evaluation of inner ear structures and contralateral mastoid region

Parameter	Frequency	Percentage (%)
Jugular Bulb		
Normal	41	82.0
High Riding	9	18.0
Cochlea and Semicircular Canals		
Normal	48	96.0
Dysplastic SCC	2	4.0
Contralateral Ear		
Normal	38	76.0
Soft Tissue	12	24.0

A high-riding jugular bulb was identified in nearly one-fifth of patients. Most patients showed preserved inner ear architecture, with occasional isolated semicircular canal dysplasia. Contralateral mastoid

soft tissue changes were observed in 24% of patients, emphasizing the value of bilateral imaging assessment.

Table 6: Intraoperative findings during mastoid surgery

Surgical Finding	Frequency	Percentage (%)
Cholesteatoma	12	24.0
Dehiscent Facial Canal	8	16.0
Edematous Mucosa	2	4.0
Granulation Tissue	5	10.0
Ossicular Pathology	16	32.0
Normal Findings	7	14.0
Ossicular Status		
Erosion of Incus	2	4.0
Erosion of Malleus	4	8.0
Erosion of Malleus and Incus	9	18.0
Erosion of Malleus, Incus, and Stapes	1	2.0
Normal Ossicles	34	68.0
Mastoid Pneumatization		
Sclerotic	33	66.0
Pneumatized	13	26.0
Diploetic	4	8.0

Ossicular pathology and cholesteatoma were the most frequent intraoperative abnormalities. Most mastoids were sclerotic intraoperatively, reflecting chronic

inflammatory remodeling. Combined malleus and incus erosion represented the commonest ossicular destruction pattern observed surgically.

Table 7: Tympanic membrane perforation patterns identified during surgery

Type of Perforation	Frequency	Percentage (%)
Subtotal Perforation	16	32.0
Attic Perforation	15	30.0
Central Perforation	12	24.0
Marginal Perforation	7	14.0
Total	50	100.0

Subtotal perforation was the most common tympanic membrane abnormality, followed closely by attic perforation. These perforation patterns are typically

associated with chronic suppurative otitis media and cholesteatoma formation.

Table 8: Radiological–surgical correlation and statistical association

Parameter	CT Positive	Surgical Positive	Statistical Significance
Ossicular Erosion	14	16	Chi-square = 41.32, p < 0.001
Facial Canal Dehiscence	7	8	Chi-square = 42.72, p < 0.001
Mastoid Pathology	46	46	p < 0.01
Cholesteatoma	12	12	p < 0.01
Association Analysis	Significant Observation		
Ossicular erosion vs mastoid air cell pathology	Ossicular erosion was more common in sclerosed mastoids with soft tissue opacification		
Middle ear cavity soft tissue vs intraoperative findings	Soft tissue opacification in MEC was associated with increased intraoperative abnormalities		

Radiological findings demonstrated excellent agreement with intraoperative observations. MDCT showed high diagnostic accuracy in identifying ossicular erosion, facial canal dehiscence, mastoid pathology, and cholesteatoma. Significant associations were also noted between mastoid sclerosis and ossicular destruction, as well as between middle ear cavity soft tissue and operative complications.

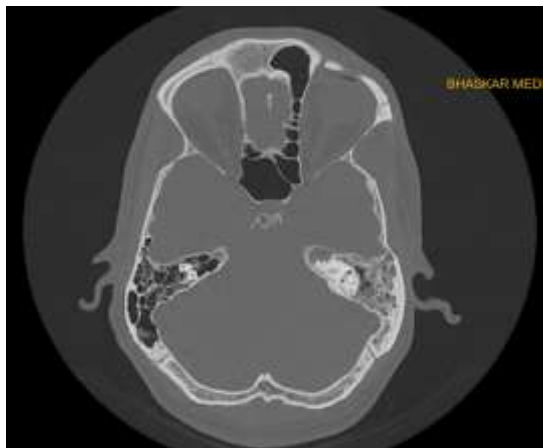

Figure 1a

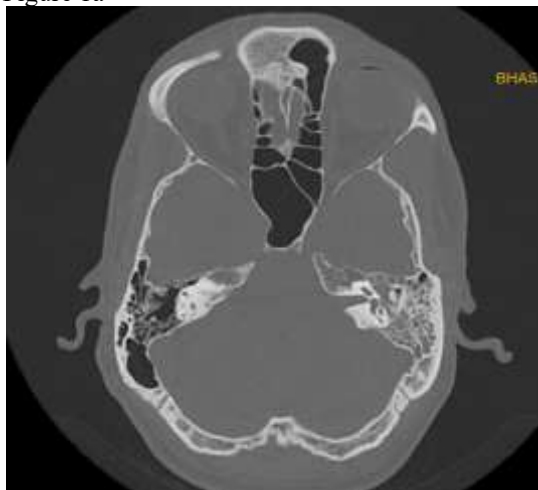

Figure 1b

Figure 1a & 1b. 45 year old male with complaints of discharge and decreased hearing. HRCT axial images of temporal bone demonstrating soft tissue opacification in left epi-, meso-tympanum and mastoid air cells. Ossicular chain intact.

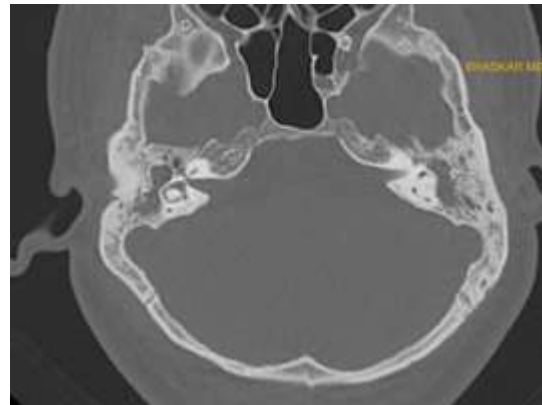


Figure 2a

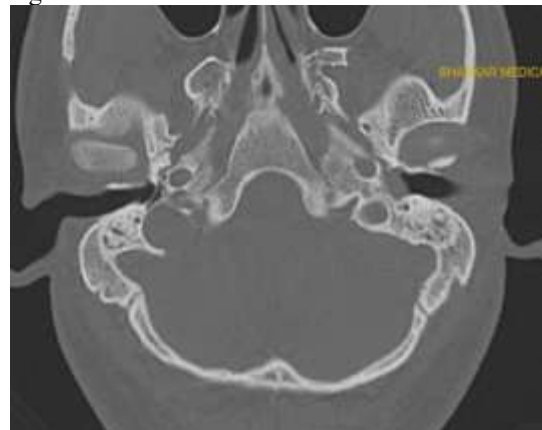


Figure 2b

Figure 2a & 2b. 25 year old male with c/o pain & discharge. HRCT axial images of temporal bone show soft tissue opacification in right epi- and meso-tympanum, erosion of incus and head of malleus, paucity of mastoid air cells with resorption of septa, sclerosis of bone and high riding jugular bulb. Left side: Soft tissue opacity in middle ear cavity, aditus ad antrum, mastoid antrum and mastoid air cells with ossicular erosion.

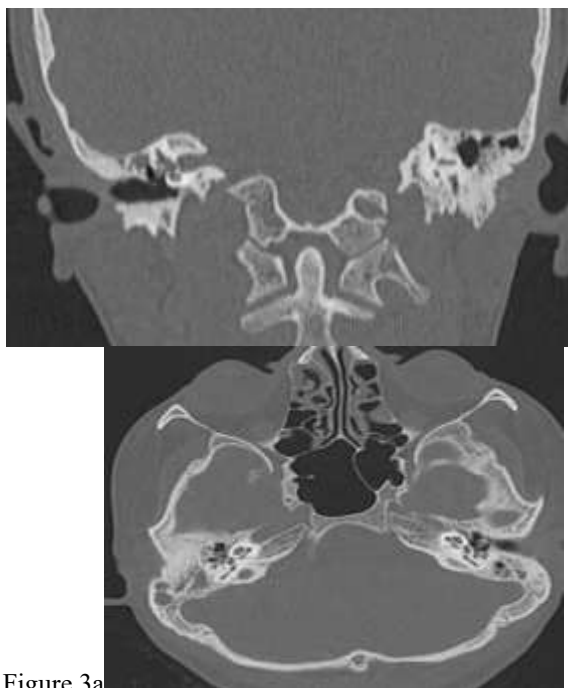


Figure 3a

DISCUSSION

In this cross-sectional observational study conducted at Bhaskar Medical College, 50 patients with clinically suspected mastoiditis underwent evaluation using multidetector computed tomography (MDCT). The key aim was to assess the role of MDCT in diagnosing mastoiditis and related pathologies and to correlate radiological findings with intraoperative surgical outcomes. This study primarily highlights the diagnostic capabilities of MDCT in assessing disease severity, identifying anatomical variations, and predicting intraoperative complications, thus serving as a critical tool in surgical planning and patient management.

One of the central objectives of this study was to evaluate how well MDCT findings correspond with intraoperative observations, particularly in identifying key pathologies such as mastoid sclerosis, ossicular erosion, cholesteatoma, facial canal dehiscence, and tympanic membrane perforations. The reliability of imaging as a surgical planning tool depends heavily on the degree of concordance between preoperative radiological assessments and actual intraoperative findings. In this study, we observed a strong correlation in several anatomical areas, while mild discrepancies were noted in regions with complex, minute structures - findings that echo conclusions in the existing literature.

Dermographics

The majority of patients were between the ages of 21 to 40 years, accounting for 66% of the total sample. The highest frequency was observed in the 31–40 age group (34%), followed closely by the 21–30 group (32%). Pediatric cases (0–10 years) were minimal at 2%, while elderly patients above 50 years constituted only 6%. A slight female preponderance was observed. Of the total participants, 54% were female (n=27), while 46% were male (n=23). Left side

Figure 3b

Figure 3a & 3b. 20 year old female with c/o bilateral ear discharge. HRCT coronal and axial images of temporal bone show soft tissue opacification in the bilateral middle ear, mastoid air cells and sinus tympani with mild mastoid sclerosis and focal erosion of the tegmen tympani on right side.

mastoid involvement seen in 56% of cases, right side involvement seen in 26 %, bilateral involvement is seen in 14 % cases. Clinically, most patients presented with symptoms like ear discharge and hearing loss, and PTA confirmed conductive hearing loss in 76% of the cases.

Mastoid air cells

Mastoid air cell pathology was evident in most patients, emphasizing the pivotal role of mastoid involvement in otologic infections. Sclerosed air cells with soft tissue opacification were the most frequent finding, seen in 58% of cases, indicating chronic or long-standing inflammation. Soft tissue opacification alone was observed in 30%, suggestive of acute or subacute infection. Only 12% of the cases exhibited normally aerated mastoid air cells. These findings reflect the progression of middle ear infections into the mastoid, where chronic cases often result in bony remodeling or sclerosis, while acute inflammation is characterized by soft tissue replacement of air content. High-resolution MDCT thus proves critical in identifying these stages and guiding therapeutic decisions.

MDCT findings were closely mirrored by intraoperative evaluations, confirming the accuracy of MDCT in assessing mastoid bone pneumatization. In our study, p value < 0.01 is seen in identifying mastoid air cell abnormality by using MDCT with surgical outcome correlation indicating it is statistically significant.

This aligns with findings by Munhoz L et al,^[7] who demonstrated that sclerotic mastoids, readily identified on CT, were often linked to chronic inflammatory disease and correlated well with surgical difficulty due to reduced mastoid air cell aeration. Moreover, the presence of mastoid sclerosis is critical for surgical decision-making, particularly when planning canal wall-up or canal wall-down mastoidectomy procedures.

External auditory canal

Soft tissue opacification noted in 12 % of the cases indicating that external ear involvement is not seen in many cases. The external auditory canal (EAC) appeared normal in 88% of the cases, indicating that the majority of mastoiditis cases do not extend into or originate from the external canal. EAC involvement may be attributable to coexistent otitis externa or post-inflammatory changes secondary to chronic discharge. The relative sparing of the EAC underscores its diagnostic value as a differentiating feature from primary external ear pathologies. In patients presenting with otologic complaints, a normal EAC on imaging raises clinical suspicion toward middle ear and mastoid origins. This observation aligns with Carcacia et al,^[8] who emphasized that external auditory canal involvement is not so common.

Middle ear cavity

A substantial majority of patients (84%) demonstrated soft tissue opacification in the middle ear cavity, indicating the role of middle ear pathology as a primary source of mastoiditis. Only 16% of patients exhibited normal middle ear cavity. Epitympanum is the most common site for soft tissue in the middle ear cavity seen in 40 % of cases. MDCT enables precise evaluation of middle ear cavity and helps in identifying coexisting complications such as ossicular involvement or tympanic membrane retraction and other associated findings such as Prussack's space involvement.

The correlation between middle ear cavity (MEC) opacification and intraoperative presence of pathological tissue—such as granulation tissue, cholesteatoma, or edematous mucosa—was also significant. CT revealed MEC soft tissue in 84% of patients, while surgical findings confirmed corresponding abnormal tissues in the all of these cases. This observation aligns with Carcacia et al,^[9] who emphasized the value of MDCT in detecting soft tissue pathology, fluid levels, and early signs of abscess formation, even before clinical signs become apparent within the middle ear that often requires surgical clearance to prevent recurrence. However, it is important to note that while CT can detect soft tissue density, it cannot always differentiate between granulation tissue, cholesteatoma, or effusion, necessitating intraoperative confirmation. Moreover, while MRI was reported to be superior in assessing soft tissue involvement and early intracranial extension, our study supports the view that CT remains the preferred initial modality, especially in assessing bony detail and surgical anatomy.

Ossicular erosion

Ossicular erosion is a frequent & clinically significant finding, present in 32% of the cases. Erosion of malleus and incus was the most common, seen in 18 %. These findings are alarming as they indicate potential for cholesteatoma. However, any erosion noted on CT must prompt urgent clinical attention. When analyzing ossicular chain erosion, ossicular damage observed in 32% of cases, CT identified 87.5

% cases of ossicular erosion, remaining cases with subtle erosion were detected during surgery. In our study, p value is < 0.03 indicating a strong correlation between CT and surgical findings. The malleus and incus being the most frequently affected and stapes is the last to get eroded. These imaging findings were largely validated during surgery. However, there were isolated cases where CT failed to detect subtle erosions, especially when only partial loss of ossicular continuity was present. The most common pattern was combined erosion of the malleus and incus, reflecting advanced disease with prolonged inflammation. While CT reliably identified most cases, minor ossicular defects, particularly those limited to the incus long process or head of malleus, were occasionally missed. The clinical implication is significant, as ossicular integrity influences postoperative hearing outcomes and may necessitate ossiculoplasty or prosthetic reconstruction. These findings highlight the complementary nature of CT and surgery, with CT serving as the guidepost and intraoperative assessment acting as the definitive evaluator.

Similar discrepancies were reported by Sudarshan,^[10] and Majeed and Reddy,^[11] who noted that while HRCT was excellent in detecting gross ossicular destruction, its sensitivity dropped in detecting early or partial erosions due to limitations in resolution and ossicle orientation. Therefore, while MDCT serves as a reliable preliminary tool, direct visualization during surgery remains essential for complete ossicular assessment.

Prussack's space

Prussack's space involvement was seen in 36% of the cases, represented by soft tissue density in this anatomically confined area. As one of the most common sites for cholesteatoma formation, changes here are highly suggestive of advanced disease and full evaluation should be done. Normal findings in 64% of cases may reflect early disease or infections not involving the attic. Visualization of Prussack's space on high-resolution CT is critical in surgical planning due to its proximity to the ossicles and facial nerve.

The involvement of Prussack's space often coincided with scutum erosion and ossicular damage. This space is clinically significant due to its limited surgical accessibility and its tendency to harbor residual disease if not adequately cleared. CT visualization of soft tissue in this region alerts the surgeon to potential hidden pockets of infection or cholesteatoma, requiring careful inspection during surgery. Our findings confirm the assertion by Carcacia et al,^[9] that CT, while unable to definitively distinguish cholesteatoma from granulation tissue, provides crucial spatial information to guide surgical navigation.

Scutum

In this study, 28% of the patients exhibited scutum abnormalities, with 16% showing blunting and 12% demonstrating erosion. The scutum, being a small, bony ridge adjacent to the epitympanum, is

commonly affected in chronic otitis media and cholesteatoma. Erosion is a strong radiological marker of aggressive disease and warrants surgical consideration. The finding that 72% had a normal scutum suggests either early-stage disease or involvement confined to other anatomical regions. Identification of scutum changes on MDCT is important in preoperative assessment and disease staging.

This supports the hypothesis that attic and epitympanic disease often precedes ossicular and mastoid involvement. The scutum's close proximity to Prussack's space—a key region for cholesteatoma origin—explains its frequent involvement. These observations align with the findings of Keskin et al. (2011), who noted CT sensitivity and specificity of 80% and 90.4%, respectively, for scutum erosion. Timely identification of scutum changes on CT not only aids in early cholesteatoma detection but also assists in deciding between conservative versus radical surgical approaches.

Cholesteatoma

Cholesteatoma in CT can be identified as soft tissue opacification involving middle ear cavity including prussack's space, sinus tympani, erosion of scutum and ossicular erosion.

One of the strongest radiologic-surgical correlations was observed in the detection of cholesteatoma, identified in 24% of surgical cases and consistently preceded by suspicious CT findings such as scutum erosion, Prussack's space soft tissue, and ossicular erosion involvement. These findings are consistent with observations by Sudarshan,^[11] and Majeed and Reddy,^[12] where CT was effective in preoperatively identifying cholesteatoma and helped in determining the need for more extensive surgical approaches even though it may sometimes be unable to differentiate granulation tissue from cholesteatoma without MRI. This is particularly important because cholesteatoma, if undiagnosed, can cause irreversible complications including intracranial extension, hearing loss, and facial palsy. Nonetheless, in resource-limited settings or where MRI is not feasible, CT findings provide sufficient evidence to justify surgical intervention.

Sinus tympani

Sinus tympani involvement was seen in 16% of patients as soft tissue opacification. This region is known to be a hidden recess where disease, particularly cholesteatoma, may persist postoperatively. The challenge in visualizing and accessing the sinus tympani surgically underscores the importance of preoperative imaging. Although sinus tympani involvement was not uniformly associated with complications in this cohort, its presence warrants careful consideration, especially in revision surgeries. As pointed out by Carcacia et al,^[9] imaging the depth and extent of disease in these hidden spaces significantly improves surgical clearance and reduces the risk of recurrence.

High riding jugular bulb

Another critical variant observed was high-riding jugular bulb, present in 18% of patients. This

anatomical variation is not pathological per se but has serious surgical implications. Its presence increases the risk of intraoperative hemorrhage, especially during canal wall procedures or posterior tympanotomy. CT identification of this variant preoperatively is thus vital in surgical planning. However, as with Keskin et al,^[13] and Sudarshan,^[11] our study also found that in some cases, high riding jugular bulb is present as an anatomical variant in some people.

Facial canal dehiscence

Facial canal dehiscence, indicative of bony erosion over the facial nerve, was found in 12% of patients. This poses significant surgical risk, particularly during mastoidectomy or tympanoplasty procedures. Identifying such dehiscence preoperatively is vital to avoid inadvertent nerve injury and resultant facial paralysis. In this study, 88% of patients had an intact canal; however, the identified erosions highlight the importance of routine facial nerve assessment on all temporal bone CT scans.

Facial canal dehiscence was another critical area where MDCT findings and intraoperative observations showed partial correlation. In this study, facial canal dehiscence was suspected in 12% of patients based on imaging and was surgically confirmed in several cases. However, in 1 patient, dehiscence was only discovered intraoperatively, despite a seemingly intact canal on MDCT. CT detected 85.7% of facial canal dehiscence cases and the rest were identified in surgery. This discrepancy can be attributed to the thin and variable anatomy of the facial canal, where minimal dehiscence or erosion may be below the resolution threshold of conventional CT scanners. Keskin et al,^[13] also reported similar limitations, citing lower sensitivity (66.6%) for detecting facial nerve canal abnormalities compared to other parameters such as scutum erosion or tympanosclerosis.

Similarly, in our study, cases identified preoperatively on CT were confirmed intraoperatively, though a few subtle defects were only detected during surgical dissection. These findings underscore the need for high suspicion and meticulous CT evaluation of the facial canal, especially when bony erosion or disease extension is noted in adjacent areas. The limitations in resolution or slice thickness may result in subtle erosions being overlooked. Despite these limitations, MDCT served as a strong predictive tool in alerting the surgical team to possible anatomical variations that required cautious dissection.

Bone erosion

Bone erosion was an infrequent but clinically significant finding, present in 8% of the cases. Tegmen tympani erosion was seen in 4% and tegmen mastoid erosion seen in 4%. These findings are alarming as they indicate potential for intracranial extension, such as meningitis or epidural abscess. The absence of bony erosion in 92% of patients suggests early diagnosis or effective management. However, any erosion noted on CT must prompt urgent clinical

attention due to the associated risks. As pointed out by Carcacia et al,^[9] bone erosion is not a frequent finding seen and if any subtle erosions are present, they have to be detected with caution as the risk of intracranial extension is high in cases of bone erosion.

Cochlea and semicircular canals

The inner ear structures, specifically the cochlea and semicircular canals (SCC), were normal in 96% of cases. Isolated abnormalities included dysplastic SCC in 4% of cases. These rare findings are clinically significant as they may present with vestibular symptoms or profound hearing loss. Infections extending to the inner ear require urgent intervention due to the risk of labyrinthitis and permanent sensory damage. CT imaging thus plays a vital role in screening for inner ear integrity in complicated mastoiditis. These findings are consistent with Sudharshan et al,^[11] who reported that the inner ear structures involvement is not a common finding.

Tympanic membrane

The present study also highlights the utility of CT in predicting the status of the tympanic membrane, where imaging clues like attic and marginal erosion suggested corresponding perforations that were confirmed surgically. For instance, attic perforation was observed in 30% of cases, closely aligning with the imaging patterns and consistent with Sudarshan et al,^[11] who reported attic perforation as a key indicator of underlying cholesteatoma.

Contralateral ear

In terms of identifying contralateral disease, our study found soft tissue opacification in 24% of asymptomatic contralateral ears. This subclinical involvement highlights the systemic or bilateral nature of chronic otologic disease. This is in line with recommendations made by Subbaiah et al,^[10] who advocated for bilateral imaging in patients with chronic or complicated otitis media to identify early-stage or subclinical disease on the opposite side. Early identification of such pathology may prevent recurrence or future surgical intervention. Our findings support this approach, suggesting that a single-symptom presentation does not preclude bilateral pathology. Studies like those by Kumar et al,^[14] and Musa et al,^[15] highlight the universal strengths of MDCT—thin-section imaging, multiplanar reconstruction, and rapid acquisition—which enable precise anatomical and pathological delineation in complex clinical scenarios.

The present study affirms the vital role of multidetector computed tomography (MDCT) in evaluating mastoiditis and its associated complications. Through detailed multiplanar reconstructions and high-resolution imaging, MDCT was able to detect a spectrum of disease manifestations — ranging from mastoid air cell sclerosis and soft tissue opacification to ossicular erosion, scutum involvement, facial canal dehiscence, and intracranial risk indicators.

One of the most prominent advantages of MDCT, as demonstrated in this study, is its ability to delineate bony architecture with precision. Structures such as

the scutum, ossicles, mastoid septae, tegmen tympani, and sigmoid plate were effectively visualized. The high accuracy of MDCT in detecting mastoid sclerosis, scutum erosion, and soft tissue opacification correlates closely with the findings of Keskin et al,^[13] who reported high sensitivity and specificity of CT in detecting scutum erosion (80% and 90.4%, respectively) and tympanosclerosis (84.6% and 88.3%). These results are similar in the current study, where mastoid sclerosis was noted in 66% of patients, with corresponding intraoperative confirmation in most cases. Similarly, attic and marginal erosions, indicative of scutum involvement, were consistently identified on imaging.

One of the significant strengths of multidetector computed tomography (MDCT) is its ability to detect not only primary pathological changes associated with mastoiditis but also the anatomical variations and complications that may influence the clinical course and surgical outcomes. In this study, MDCT enabled the identification of complications such as facial canal dehiscence, ossicular erosion, scutum erosion, and high-riding jugular bulb, as well as soft tissue extension into sinus tympani and Prussack's space—regions known for harboring residual cholesteatoma or disease recurrence if not completely excised during surgery.

CONCLUSION

The present study demonstrates that multidetector computed tomography (MDCT) is a highly effective imaging modality in the evaluation of mastoiditis and associated middle ear pathologies. MDCT accurately identified mastoid sclerosis, soft tissue opacification, ossicular erosion, cholesteatoma, and facial canal dehiscence, with strong radiological–surgical correlation. The modality proved valuable in differentiating acute and chronic disease patterns and in detecting important anatomical variations such as high-riding jugular bulb and contralateral mastoid involvement. Preoperative identification of these findings significantly aided surgical planning and reduced intraoperative uncertainty. Although MRI may provide superior soft tissue characterization, MDCT remains the primary imaging tool for assessing bony anatomy and disease extent. The study findings support the routine use of temporal bone MDCT in chronic and recurrent otologic disease. Overall, MDCT plays a crucial role in improving diagnostic accuracy, guiding operative management, and enhancing surgical safety and patient outcomes in mastoid pathology.

REFERENCES

1. Saat R, Laulajainen-Hongisto A, Mahmood G, Lempien L, Aarnisalo AA, Markkola A, et al. MR imaging features of acute mastoiditis and their clinical relevance. *AJNR Am J Neuroradiol*. 2015;36(2):361-367.
2. Sethi N, Rafferty A, Kayarkar R. How reliable is preoperative temporal bone CT in mastoid surgery? *J Otol Rhinol*. 2016;5(2):1-5.

3. Stähelin-Massik J, Podvinec M, Jakscha J, Rüst O, Greisser J, Moschopoulos M, et al. Mastoiditis in children: a prospective, observational study. *Eur J Pediatr.* 2008;167(5):541-548.
4. Arlis S, Defit S, Sumijan. Development of mastoid air cell system extraction method on temporal CT-scan image. *J RESTI.* 2022;6(2):245-252.
5. Kumar S. High resolution computed tomography evaluation of temporal bone in patients of chronic otitis media: a surgico-radiological correlation study [dissertation]. 2016.
6. Kumar P. A hospital based study of high resolution computed tomography and conventional radiography for evaluation of pathologies of temporal bone. *Perspect Med Res.* 2020;8(2):45-50.
7. Munhoz L, Iida CH, Abdala Júnior R, Fernandes KS, Rubira-Bullen IRF, Machado ACP. Mastoid air cell system: Hounsfield density by multislice computed tomography. *J Clin Diagn Res.* 2018;12(4):TC01-TC03.
8. Cassano P, Ciprandi G, Passali D. Acute mastoiditis in children. *Acta Biomed.* 2020;91(1-S):54-59.
9. Carcacia I, Prieto P, Rivera JC, et al. Acute mastoiditis and its complications: the role of imaging techniques, CT and MRI. *Radiologia.* 2011;53(6):504-510.
10. Subbaiah CV. Diagnostic and surgical treatment outcome of acute mastoiditis in pediatric age group [dissertation]. 2015.
11. Sudarshan R. Role of CT mastoids in the diagnosis and surgical management of chronic inflammatory ear disease [dissertation]. 2016.
12. Majeed J, Reddy LS. Role of CT mastoids in the diagnosis and surgical management of chronic inflammatory ear diseases. *Indian J Otolaryngol Head Neck Surg.* 2017;69(1):113-120.
13. Keskin S, Çetin H, Töre HG. The correlation of temporal bone CT with surgery findings in evaluation of chronic inflammatory diseases of the middle ear. *Eur J Gen Med.* 2011;8(1):24-30.
14. Kumar SR, Vudumula VP, Maghiben M. Role of HRCT temporal bone in diagnosis of chronic suppurative otitis media in correlation with intraoperative findings. *Med Leg Update.* 2020;20(2):250-255.
15. Musa RM, Hassan IA, Nabi M, Hassan H. Study of mastoid air cells diseases using spiral CT. *J Med Res.* 2013;2(4):115-120.