



## Original Research Article

# TO EVALUATE FUNCTIONAL AND RADIOLOGICAL OUTCOMES OF FIXATION OF DISPLACED DISTAL END RADIUS FRACTURES BY PERCUTANEOUS KIRSCHNER WIRES CONNECTED TOGETHER WITH JOSHI'S CLAMP: A PROSPECTIVE STUDY

Sonu<sup>1</sup>, Abhishek Garg<sup>2</sup>, Ashok Kumar<sup>3</sup>, Anubhav Chhabra<sup>2</sup>, Anurag Chhabra<sup>4</sup>, Suryansh Agnihotri<sup>1</sup>, Sahil<sup>1</sup>, Rakesh Kumar<sup>1</sup>, Anuj Kumar<sup>1</sup>, Lalit Kumar<sup>1</sup>, Gajender Yadav<sup>1</sup>

<sup>1</sup>Postgraduate, Department of Orthopaedics, MAMC Agroha, Hisar, India.

<sup>2</sup>Assistant Professor, Department of Orthopaedics, MAMC Agroha, Hisar, India.

<sup>3</sup>Professor, Department of Orthopaedics, MAMC Agroha, Hisar, India.

<sup>4</sup>Senior Professor and Head of Department, Department of Orthopaedics, MAMC Agroha, Hisar, India.

Received : 16/03/2026  
Received in revised form : 08/05/2026  
Accepted : 25/05/2026

#### Corresponding Author:

**Dr. Ashok Kumar**

Professor, Department of Orthopaedics,  
MAMC Agroha, Hisar, India.  
Email: drashokbagotia@gmail.com.

DOI:10.70034/ijmedph.2026.2.449

Source of Support: Nil,

Conflict of Interest: Nondeclared

Int J Med Pub Health  
2026; 16 (2); 2717-2723

#### ABSTRACT

**Background:** Distal end radius fractures are the most frequent upper limb fractures, often managed with various techniques ranging from casting to internal fixation. This study was performed to evaluate functional and radiological outcomes of fixation of displaced distal end radius fractures by percutaneous Kirschner wires connected together with Joshi's clamp.

**Materials and Methods:** In this prospective study 20 patients aged above 18 years of fracture distal end radius were treated with percutaneous Kirschner wires connected together with Joshi's clamp, followed by early mobilization post operatively. Patients were followed up regularly, radiological and functional assessment were done at 3 weeks, 6 weeks, 3 months and 6 months using Modified Mayo Wrist Score.

**Results:** Radiologically all patients had union at final follow up. On final follow up at 6 months 85% patients had excellent, 10% good and 5% showed fair results on Modified Mayo Wrist Score. No major complications were observed in the present study. Three patients developed superficial infection which was resolved with serial dressing and broad spectrum antibiotics. One patient developed stiffness at wrist.

**Conclusion:** Percutaneous Kirschner wire fixation augmented with Joshi's clamp is an effective, safe, and economical treatment option for displaced distal end radius fractures that are amenable to closed reduction. The technique provides satisfactory functional recovery, maintains acceptable radiological alignment, ensures reliable fracture union, and is associated with a low incidence of manageable complications.

**Keywords:** Fractures of distal end radius, percutaneous pinning, Joshi's clamp, Modified Mayo Wrist Score.

## INTRODUCTION

The most frequent fractures of the upper limb are distal end radius fractures, which account for around 18% of all fractures in clinical practice.<sup>[1,2]</sup> Fractures of the distal end radius can be managed by different treatment techniques in which closed reduction and casting has been mainstay of treatment. It has been observed that closed reduction and cast

immobilization often leads to loss of reduction and collapse of distal radius resulting in unsatisfactory anatomical and functional results with varying degree of deformity and disability.<sup>[3]</sup>

Other different treatment modalities have their own complications like ORIF with plating technique leads to scar, wound infections, tendon rupture. Fixation by external fixators may lead to pin tract

infections, neuro-vascular injuries, post traumatic arthrosis.

Fixation by Kirschner wires is comparatively less invasive and cosmetically better technique but wire loosening and loss of reduction is major issue in this mode of treatment.<sup>[4,5]</sup>

Percutaneous Kirschner wire fixation has emerged as a minimally invasive alternative that offers several advantages over more invasive surgical techniques. Joshi's clamp allowed stronger stability and mobility at joint which reduces chances of loosening of Kirschner wires from fracture. As this procedure does not require stabilization by cast/slab post operatively which leads to early mobilisation at wrist joint reduces the risk of joint stiffness. As there are very few studies about Joshi's clamp augmentation of k- wire in distal end radius fractures, we aimed to evaluate the functional and radiological outcomes of fixation of displaced distal end radius fractures by percutaneous Kirschner wires connected together with Joshi's clamp.

## MATERIALS AND METHODS

The present prospective observational study was carried out in the Department of Orthopaedics at Maharaja Agrasen Medical College, Agroha (Hisar), from March 2024 to September 2025. A minimum of 20 patients aged 18 years and above with distal end radius fractures were enrolled in the study. Patients presenting to the Emergency Department and Orthopaedics Outpatient Department with extra-articular distal end radius fractures and undisplaced intra-articular distal end radius fractures were recruited sequentially and conveniently after satisfying the inclusion criteria.

### Inclusion and exclusion criteria

Inclusion criteria included patients with extra-articular distal end radius fractures and undisplaced intra-articular distal end radius fractures age above 18 years, healthy skin at the k- wire insertion site, stable hemodynamic status, general condition of the patient and patient willing to give informed consent. Exclusion criteria were pathological fractures, open or compound fractures with neurovascular injury, presence of other fractures in ipsilateral upper limb, poor skin condition at wire insertion site, any medical contraindication to surgery. All patients fulfilling the inclusion criteria underwent a comprehensive pre-operative evaluation, which included detailed history taking, thorough general and local clinical examination, routine haematological, biochemical and radiological investigations. Fractures were classified according to Frykman's classification system.

**Surgical technique:** All surgical procedures were performed in the operation theatre under general or regional anaesthesia. Patients were positioned supine on the operating table, with the affected limb placed on a side table. After thorough scrubbing of the forearm, wrist, and hand with povidine-iodine

solution, sterile draping was done. Closed reduction of the fracture was achieved by traction and manipulation, and the adequacy of reduction was confirmed under C-arm fluoroscopy. The first Kirschner wire was inserted intramedullary from the radial styloid with a bent tip, passing between the first and second extensor compartments. The second Kirschner wire was inserted at the ulnar corner of the distal radius using the intrafocal (Kapandji) technique between the fourth and fifth extensor compartments, ensuring protection of the extensor pollicis longus tendon. A third Kirschner wire was introduced either intrafocally as a dorsal buttress or bicortically between the third and fourth extensor compartments to provide additional stability. In all procedures, 1.8mm or 2.0mm K-wires were used. After insertion, all Kirschner wires were bent and converged externally just above the wrist, where they were locked together using Joshi's external clamp. No postoperative slab or cast was applied as adequate stability was achieved with the fixation construct.

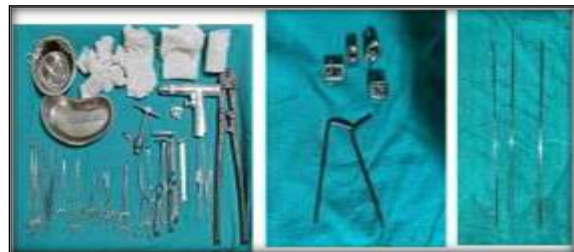

Figure 1: Instruments with Joshi's clamp, allen key and long K-wires

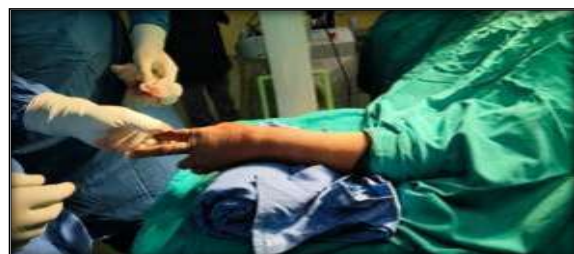

Figure 2: Closed reduction under C-arm

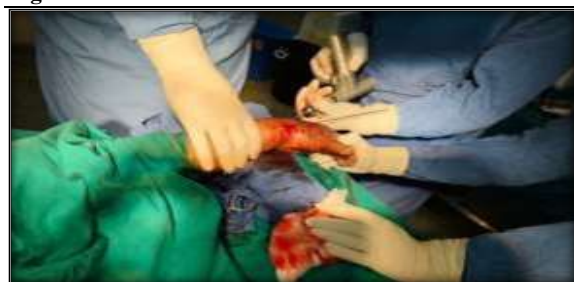
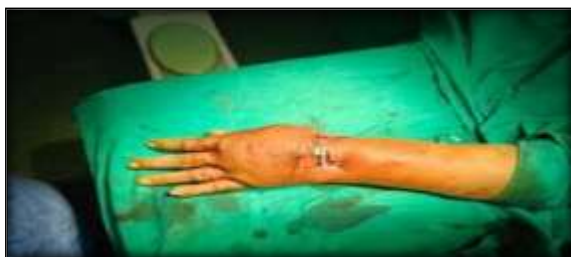
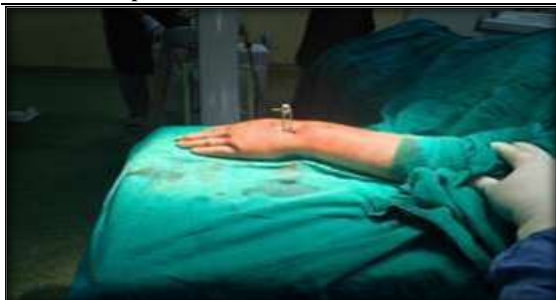Figure 3: K-wire insertion



**Figure 4: Superior view after connecting K-wires with Joshi's clamp**



**Figure 5: Lateral view after connecting K-wires with Joshi's clamp**

**Post operative follow up:** Postoperative pain and inflammation were managed with analgesics, anti-inflammatory medications, and limb elevation. All patients received intravenous cefotaxime 1 g twice daily for two days, followed by oral cefixime 200 mg twice daily for five days. Active wrist movements along with shoulder, elbow, and finger exercises were initiated from the first postoperative day, as immobilization was not required. Patients were followed up at 3 weeks, 6 weeks, 12 weeks, and at 6 months postoperatively. Clinical and radiological assessments were performed at each visit to evaluate fracture union, functional recovery, and complications. Kirschner wires and Joshi's

clamp were removed in the outpatient department at 6–8 weeks once clinical fracture union was confirmed (no tenderness, no crepitus). Radiological assessment included evaluation of volar tilt (degrees), radial inclination (degrees), and radial height (millimetres). Final functional outcomes were assessed using the Modified Mayo Wrist Score.

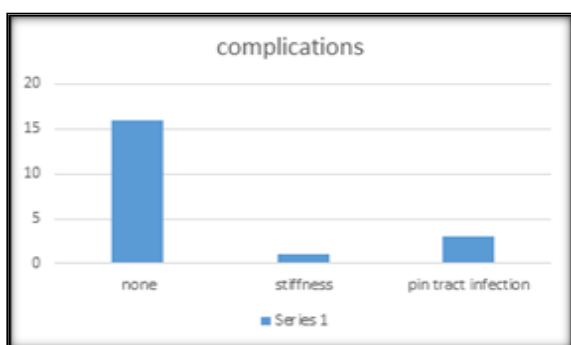
## RESULTS

The study was started in March 2024 and completed in September 2025. Most of the patients in the study belonged to 31 to 60 years age group (75%). There were 13 male patients (65%) and 7 female patients (35%). Slip and fall, fall from height and fall from bike was observed to be the most common mode of injury accounting for 70% of the cases whereas moderate velocity trauma such as physical assault accounted for 20% and road traffic accidents accounted for 10% of cases. Out of total patients, 12 patients had involvement of left side while 8 patients had involvement of right side. All patients had right handed dominance.

According to Frykman's classification Type I fractures were the most common (45%), followed by Type II (40%), Type III (10%) and type IV (5.0%) fractures. Out of 20 patients, 12 (60%) had no associated comorbidities. Hypertension was present in 4 patients (20%), diabetes mellitus in 4 patients (20%). The majority of patients (75%) were treated using 1.8 mm Kirschner wires, while 25% required 2.0 mm wires for additional stability. Delayed complications were observed in 4 patients (20%), including stiffness (5%) and superficial pin tract infection (15%). No major neurovascular or implant-related complications were reported.

**Table 1: Distribution of complication**

Complication	Number (n)	Percentage (%)
None	16	80
Stiffness	1	5
Superficial Pin tract infection	3	15



**Graph 1: Distribution of complication**

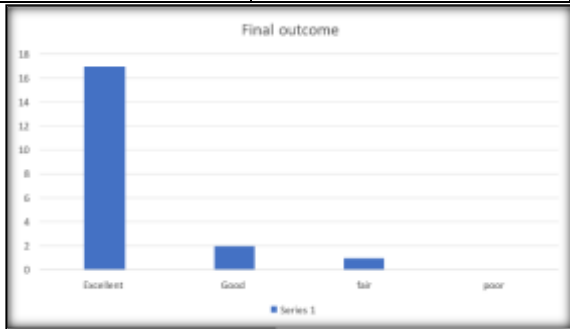
Radiological union progressed sequentially. At 3 weeks, none had union. At 6 weeks, all showed clinical union. By 12 weeks, 65% achieved radiological union and by 6 months 100% union

(radiologically consolidated) was observed. Radiographs in the postoperative period showed a mean radial height of  $9.80 \pm 0.77$ , mean radial inclination of  $19.65 \pm 1.62$  degrees, and mean volar tilt of  $12.15 \pm 1.79$  degrees at 6 months of final follow up.

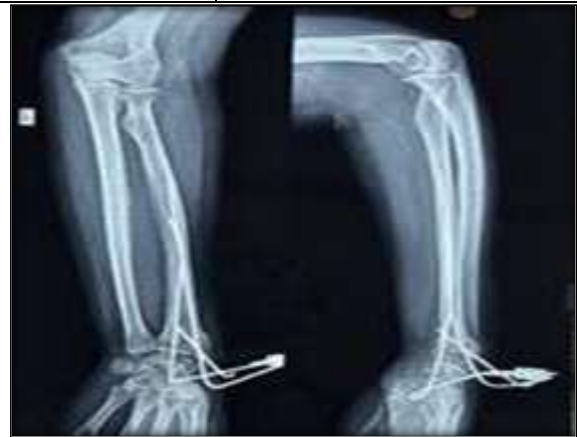In the present study, out of 20 patients, 17 patients had final score between 91 to 100, 2 patients had score between 81 to 90 and 1 patients had score between 61 to 80 according to the Modified MAYO Wrist Scoring system. As a final outcome out of 20 patients, 17 patients (85%) had excellent outcome, 2 patients (10%) had good outcome, 1 patients (5%) had fair outcome and none of the patients had poor outcome.

**Table 2: Final Outcome (Modified MAYO Wrist Score)**

S. No.	Final Outcome	No. of Cases	Percentage
1	Excellent	17	85%
2	Good	2	10%
3	Fair	1	5%
4	Poor	0	0
	Total	20	100

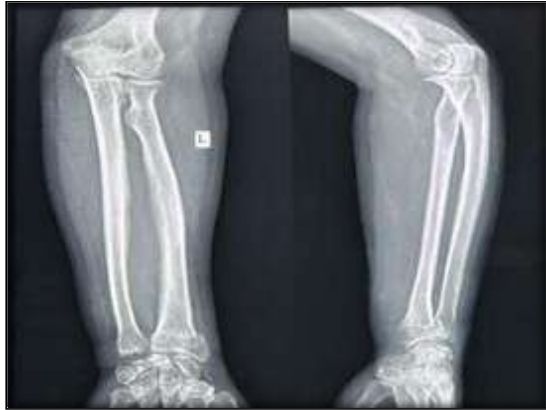

**Graph 2: Final Outcome (Modified MAYO Wrist Score)**

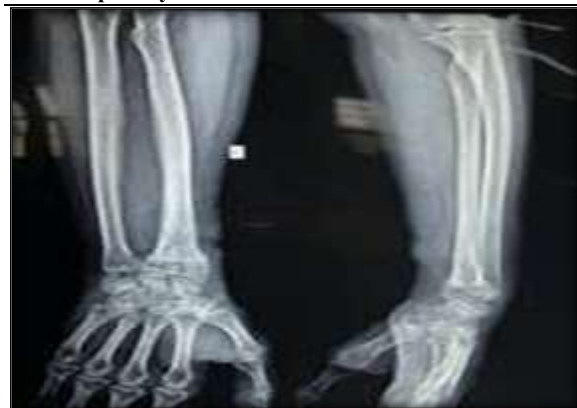

**Follow up x-ray at 6 weeks**

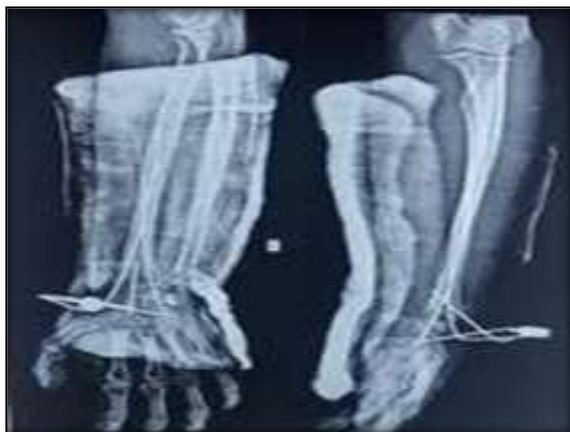**Case 1**



**Pre-op x-ray**



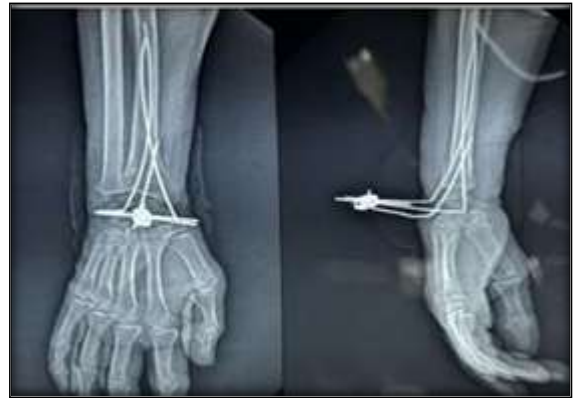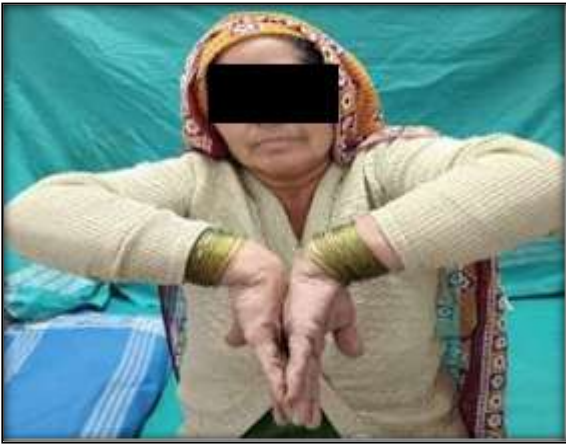**Follow up x-ray at 6 months**



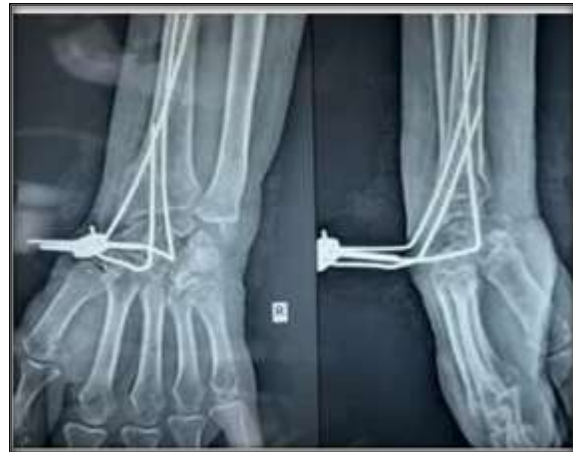**Post-op x-ray**

**Functional outcome case 1**

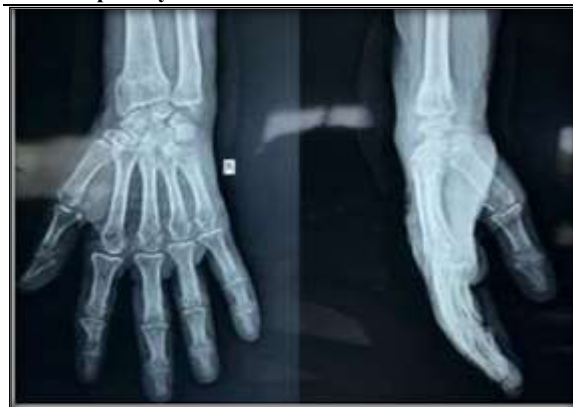



Post-op x-ray

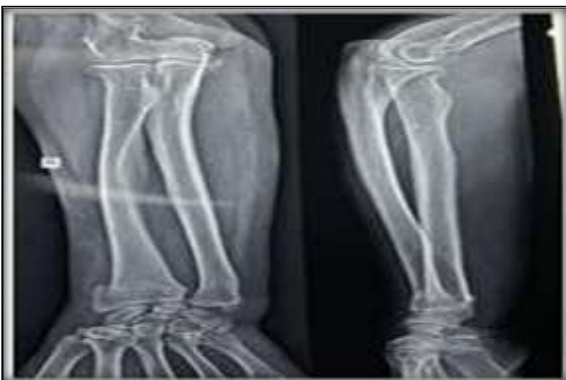

Follow up x-ray at 6 weeks



Follow up x-ray at 6 months

Case 9



Pre-op x-ray

Functional outcome case 9





## DISCUSSION

Percutaneous Kirschner wire fixation augmented with Joshi's clamp represents a minimally invasive technique that combines the principles of ligamentotaxis and external stabilization without extensive soft tissue disruption. The significance of this study lies in providing prospective evidence on the effectiveness and safety of this method in achieving satisfactory functional recovery, maintaining anatomical alignment, and ensuring reliable fracture union.

In the present study, males constituted 65% of the study population, while females accounted for 35%, demonstrating a clear male predominance in

displaced distal radius fractures managed with percutaneous K-wire fixation and Joshi's clamp. Similar male predominance has been consistently reported in the literature. Kandel et al. observed that 65% of their study cohort were males, closely mirroring the sex distribution in the present study.<sup>[6]</sup> Michael et al. also reported a higher proportion of male patients in their evaluation of JESS fixation, attributing this trend to increased trauma exposure among males in the working-age group.<sup>[7]</sup> Slip and fall was the most common cause of displaced distal radius fractures, accounting for 35% of cases. This was followed by physical assault (20%), fall from bike (20%), fall from height (15%), and road traffic accidents (10%). Ali et al. observed fall on outstretched hand as most common mechanism of injury (18%) in his study.<sup>[8]</sup> Left sided fractures predominated the present study with 60%. Singh et al. observed right side as most affected in his study.<sup>[9]</sup> In the present study, mean volar tilt was well maintained at  $12.15^\circ \pm 1.79$  at 6 months. Mustafa IA et al. observed mean volar tilt as  $10.95 \pm 1.83$  at final follow up.<sup>[10]</sup> Radial inclination remained remarkably stable across all follow-up intervals, with a mean value of  $19.65^\circ \pm 1.62$  at 6 months. Kristian et al. observed mean radial inclination of 18.6 in his study.<sup>[11]</sup> In the present study, complications were observed in 4 patients (20%), with stiffness occurring in 1 patients (5%) and superficial pin tract infection in 3 patient (15%). Joshi et al. documented a higher incidence of superficial pin tract infections (25.5%), though these were largely self-limiting following wire removal.<sup>[12]</sup>

In the present study, 75% of patients were treated using 1.8-mm Kirschner wires, while 25% required 2.0-mm wires for fixation. The selection of wire diameter was individualized based on fracture stability, bone quality, and patient factors such as body mass and degree of comminution. Dmour et al. demonstrated that larger diameter K-wires provide superior axial stiffness and load-bearing capacity, with 2.0-mm inter-fragmentary wires outperforming 1.6-mm wires significantly.<sup>[13]</sup>

In the present study 100% union was observed in all 20 patients. Raza et al. reported a union rate of 96% in patients treated with percutaneous K-wire fixation.<sup>[14]</sup> Kandel et al. reported high union rates with 84.4% good-to-excellent functional outcomes at six months.<sup>[6]</sup>

Functional recovery in the present study, assessed using the Modified Mayo Wrist Score, demonstrated progressive and statistically significant improvement over time. The mean score increased from  $60.85 \pm 6.71$  at 3 weeks to  $71.00 \pm 6.24$  at 6 weeks,  $80.55 \pm 5.34$  at 12 weeks, and  $86.70 \pm 5.09$  at 6 months. Kandel et al. reported 84.4% good-to-excellent functional outcomes at 6 months using percutaneous K-wire fixation, which closely aligns with the high mean Modified Mayo scores observed in the present study.<sup>[6]</sup>

Michael et al. reported good-to-excellent outcomes in 68.7% of patients at 6 months, improving to 78.1% at one year following JESS fixation.<sup>[7]</sup>

## CONCLUSION

The findings of this study demonstrate that this minimally invasive technique provides reliable fracture stabilization, preserves anatomical alignment, and facilitates progressive functional recovery with an acceptable complication profile. The functional outcomes achieved in this study were encouraging, with a statistically significant and clinically meaningful improvement in Modified Mayo Wrist Scores from the early postoperative period to six months. The complication rate was acceptable and largely limited to minor issues such as stiffness and superficial pin tract infection, both of which were manageable with conservative measures. The absence of major complications such as neurovascular injury, tendon damage, implant failure, or non-union further supports the safety of the technique.

In conclusion, percutaneous Kirschner wire fixation augmented with Joshi's clamp is an effective, safe, and economical treatment option for displaced distal end radius fractures that are amenable to closed reduction. The technique provides satisfactory functional recovery, maintains acceptable radiological alignment, ensures reliable fracture union, and is associated with a low incidence of manageable complications. With careful patient selection, meticulous surgical technique, and appropriate postoperative rehabilitation, this method represents a valuable addition to the armamentarium of distal radius fracture management, particularly in high-volume and resource-constrained orthopaedic practice.

## REFERENCES

1. Nellans KW, Kowalski E, Chung KC. The epidemiology of distal radius fractures. *Hand Clin.* 2012 May;28(2):113-25.
2. Awasthi A, Jadhav S, Taywade S, Salwan A, Khan K, Awasthi AA, et al. Outcome analysis of distal end radius fractures managed with antegrade intramedullary K-wire fixation. *Cureus.* 2022 Oct 20;14(10):e30421
3. Das AK, Sundaram N, Prasad TG, Thanjavelu SK. Percutaneous pinning for non-comminuted extra-articular fractures of distal radius. *Indian J Orthop.* 2011 Oct;45(5):422-6.
4. Chung KC, Spilson SV. The frequency and epidemiology of hand and forearm fractures in the United States. *J Hand Surg Am.* 2001 Sep;26(5):908-15.
5. Handoll HH, Madhok R. Conservative interventions for treating distal radial fractures in adults. *Cochrane Database Syst Rev.* 2003;(2):CD000314.
6. Kandel R, Shrestha B. Assessment of functional outcome of distal radius fracture treated with Kirschner's wire. *Journal of Nepalgunj Medical College.* 2023;21(1):1-6.
7. Michael J, George M. Functional outcome of Joshi's external stabilization system fixation in distal radius fractures. *Cureus.* 2022;14(7):e24215.
8. Ali H, Hamdy M. Treatment of distal radius fracture using external fixator with Kirschner wires augmentation versus locked volar plate. *International Journal of Health Sciences.* 2022;6(S5):1-8.
9. Dr. Surender Singh, Dr. Anurag Chhabra, Dr. Ashok Kumar, Dr. Shekhar Tank and Dr. Vivek Kumar Sahu. Functional and radiological outcomes of volar locking compression plate in surgical management of fractures of distal end radius. *Int. J. Orthop. Sci.* 2019;5(2):50-54.
10. Mostafa IA, El-Sebaey IM, Ahmed AA, Zayed EM, Elbeshbeshy A, Algarni AD. Functional outcomes of percutaneous pinning augmented by Joshi's clamp in displaced extra-articular distal radius fractures. *Saudi Journal of Sports Medicine.* 2018 Jan 1; 18(1):32-5
11. Kristian A, Asmara R. Functional outcome and range of motion between internal plate fixation versus Kirschner wire for management of distal radius fracture: a meta-analysis. *International Journal of Research and Review.* 2024;11(1):142.
12. Joshi A, Desai M. Prospective study on outcome in management of distal radius fracture by closed reduction and percutaneous 5 K-wire fixation. *International Journal of Orthopaedics Sciences.* 2021;7(3):h2803
13. Dmour T, Toma H. Comparative biomechanical analysis of Kirschner wire fixation in dorsally displaced distal radius fractures. *Life (Basel).* 2024;14(12):1684.
14. Raza S, Saleem M. Radiological and functional outcome of distal radius fracture treated conservatively versus percutaneous K-wire fixation. *Pakistan Journal of Medical and Health Sciences.* 2021;15(8):1842-6.