



Original Research Article

CLINICORADIOLOGICAL AND CYTOLOGICAL EVALUATION OF VARIOUS BREAST LUMPS

Vidhi Modi¹, Rashika Gupta², Sharmilli Kalaimani³

¹MD, Senior Resident, Department of Pathology, GMERS Medical College Dharpur, Gujarat, India.

²2nd Year Resident, Department of Pathology, GMERS Medical College Dharpur, Gujarat, India.

³2nd Year Resident, Department of Pathology, GMERS Medical College Dharpur, Gujarat, India.

Received : 28/02/2026
Received in revised form : 19/04/2026
Accepted : 03/05/2026

Corresponding Author:

Dr. Vidhi Modi,
MD, Senior Resident, Department of
Pathology, GMERS Medical College
Dharpur, Gujarat, India.
Email: vidhimodi156@gmail.com

DOI: 10.70034/ijmedph.2026.2.380

Source of Support: Nil,
Conflict of Interest: None declared

Int J Med Pub Health
2026; 16 (2); 2280-2285

ABSTRACT

Background: Breast lumps represent one of the most frequent clinical concerns among women and pose a diagnostic challenge in distinguishing benign from malignant conditions. Accurate and early diagnosis is essential for appropriate management and prognosis. The triple assessment approach—comprising clinical examination, radiological imaging, and cytological evaluation—has significantly improved diagnostic precision. Standardized reporting systems such as the Breast Imaging Reporting and Data System (BI-RADS) and the International Academy of Cytology (IAC) Yokohama system have further streamlined diagnostic interpretation and clinical decision-making. The objective is to analyze the clinicoradiological and cytomorphological features of breast lumps and to determine the correlation between ultrasonographic findings categorized by BI-RADS and cytological diagnoses reported using the IAC Yokohama system.

Materials and Methods: This prospective observational study was carried out over a period of 18 months at a tertiary care center and included 76 female patients presenting with palpable breast lumps. All participants underwent detailed clinical evaluation, ultrasonography, and fine-needle aspiration cytology (FNAC). Radiological findings were classified according to BI-RADS categories, while cytological results were interpreted using the IAC Yokohama reporting system. The concordance between radiological and cytological findings was statistically analyzed.

Results: The majority of patients belonged to the 20–39 years age group, with benign lesions being the most common presentation. BI-RADS category 2 was the predominant radiological finding (65.79%), while cytological evaluation revealed that 67% of cases were classified as benign (C2 category). Malignant lesions were more commonly observed in older age groups. The overall concordance between BI-RADS and FNAC findings was 72.36%, with the highest agreement observed in benign categories (84.31%) and relatively lower agreement in atypical or suspicious categories.

Conclusion: The combined application of ultrasonography and FNAC serves as an effective, minimally invasive, and economical diagnostic approach for the evaluation of breast lumps. This integrated method enhances diagnostic accuracy, minimizes unnecessary surgical procedures in benign cases, and facilitates early detection and timely management of malignant lesions.

Keywords: Breast lumps, FNAC, BI-RADS, IAC Yokohama system, ultrasonography, cytology.

INTRODUCTION

Breast lumps are among the most frequently encountered clinical presentations in women and

account for a substantial proportion of visits to surgical and oncology clinics. Breast lumps can range from benign, self-limiting illnesses to potentially fatal cancers. Even though most palpable breast tumors are benign, the biggest obstacle for physicians

is correctly differentiating benign from malignant lesions at an early stage because this directly affects treatment results and survival rates.^[1] In addition to reducing patient anxiety, an early and accurate diagnosis helps prevent needless intrusive treatments. Currently, breast cancer is the most frequent disease diagnosed in women globally, and it poses a serious threat to public health. Global cancer data show that 2.3 million new instances of breast cancer were recorded in 2020, making up a sizable share of women's cancer-related morbidity and mortality.^[2] The prevalence of breast cancer has been rising gradually in developing nations like India, and it is currently the most common cancer among women, surpassing cervical cancer.^[3] Numerous variables, including as urbanization, delayed childbirth, decreased nursing habits, lifestyle changes, and higher knowledge resulting to improved diagnosis rates, have been linked to this rising occurrence. Effective screening and early diagnosis techniques are crucial since late presentation is still a widespread problem in many areas despite advancements in diagnostic and treatment technologies.

The "triple assessment," which combines clinical examination, radiographic imaging, and pathological investigation, is a thorough and methodical technique needed for the evaluation of breast tumors. Concordance across the three modalities offers a high degree of diagnostic confidence, and this combination method has been demonstrated to greatly improve diagnostic accuracy.^[4] Clinical examination offers preliminary details on the lump's size, consistency, movement, and related characteristics, but it is not detailed enough to consistently distinguish benign from malignant tumors. As a result, imaging and cytological or histological evaluation must be included.^[5]

Ultrasonography is one of the most important imaging methods, especially for younger women with thick breast tissue, where mammography may have limits. In many therapeutic settings, ultrasonography is the best first-line imaging modality since it is non-invasive, readily accessible, and radiation-free.^[6] The American College of Radiology created the Breast Imaging Reporting and Data System (BI-RADS), which offers a standardized vocabulary and classification system for reporting breast imaging results. In addition to facilitating consistent communication between medical professionals, BI-RADS assists in classifying lesions according to their probability of becoming malignant, which directs subsequent treatment.^[7]

Another crucial part of the triple evaluation is fine needle aspiration cytology (FNAC), which is a quick, economical, and minimally invasive diagnostic method for assessing breast masses. Because of its price and ease of use, it is especially useful in environments with limited resources. In addition to having a high sensitivity and specificity for distinguishing benign from malignant tumors, FNAC frequently offers an instant preliminary diagnosis, facilitating timely clinical decision-making.^[8]

However, uniformity has typically been hampered by differences in reporting and interpretation.

The IAC Yokohama System for Reporting Breast Cytology was developed by the International Academy of Cytology to solve these problems. It divides FNAC results into five different categories, ranging from inadequate material to malignant tumors. The uniformity of diagnostic and treatment approaches is improved, and pathologists and clinicians can communicate more clearly thanks to this standardized reporting method.^[9] The use of such standardized methods has improved the clinical usefulness and repeatability of cytological findings. There is significant clinical significance in the relationship between radiological evaluation using BI-RADS and cytological examination utilizing the IAC Yokohama system. Particularly in benign situations, concordance between various modalities lowers the necessity for more invasive procedures like excisional biopsy and improves diagnostic reliability. Numerous studies have shown that combining cytology and imaging greatly increases diagnostic precision and guarantees early cancer identification, which enables prompt action.^[10] However, differences between radiological and cytological results may arise, particularly in unusual or borderline tumors, requiring further assessment and correlation.

In this regard, the current study uses the IAC Yokohama system in a tertiary care environment to evaluate the clinicoradiological and cytomorphological features of breast lumps and to determine the interaction between BI-RADS categories and FNAC results. It is anticipated that such a study would lead to better patient management techniques and offer insightful information on the efficacy of integrated diagnostic modalities.

Aim and Objective

Aim: To evaluate the clinicoradiological and cytomorphological characteristics of breast lumps and to determine the correlation between ultrasonographic findings categorized by the Breast Imaging Reporting and Data System (BI-RADS) and cytological diagnosis using the International Academy of Cytology Yokohama System.

Objectives

1. To study the clinical profile of patients presenting with palpable breast lumps.
2. To analyze the radiological features of breast lumps using ultrasonography and classify them according to BI-RADS.
3. To evaluate the cytomorphological features of breast lesions using Fine Needle Aspiration Cytology and categorize them according to the IAC Yokohama system.
4. To assess the correlation between radiological (BI-RADS) and cytological (IAC Yokohama) findings.
5. To determine the diagnostic utility of combined clinicoradiological and cytological evaluation in differentiating benign and malignant breast lesions.

MATERIALS AND METHODS

Study Design and Setting: This prospective observational study was conducted over a period of 18 months in the Department of Pathology at a tertiary care teaching hospital.

Study Population: A total of 76 female patients presenting with palpable breast lumps were included in the study after obtaining informed written consent.

Inclusion Criteria:

- Female patients with palpable breast lumps
- Patients willing to participate and provide informed consent
- Patients undergoing clinical, radiological, and cytological evaluation

Exclusion Criteria:

- Male patients with breast lesions
- Cases of recurrent breast malignancy
- Patients with a history of or currently receiving chemotherapy
- Patients unwilling to participate in the study

Clinical Evaluation: A detailed clinical history including age, presenting complaints, duration of symptoms, pain, nipple discharge, and family history was recorded. This was followed by general physical and local breast examination using a structured proforma.

Radiological Assessment: All patients underwent ultrasonography, and findings were categorized

according to the Breast Imaging Reporting and Data System (BI-RADS).

Cytological Procedure: Fine Needle Aspiration Cytology (FNAC) was performed under aseptic precautions using a 23-gauge needle attached to a 5–10 mL syringe. Smears were prepared, air-dried slides were stained with Field stain, and alcohol-fixed slides were stained with hematoxylin and eosin.

Cytological Classification and Correlation: Cytological findings were categorized using the International Academy of Cytology Yokohama System into five categories (C1–C5). These findings were correlated with BI-RADS categories to assess concordance.

Statistical Analysis: Data were entered into Microsoft Excel and analyzed using SPSS version 21. Descriptive statistics were expressed as frequencies and percentages. The Chi-square test was used to assess associations, with a p-value <0.05 considered statistically significant.

RESULTS

A total of 76 female patients with palpable breast lumps were evaluated using clinical examination, ultrasonography, and FNAC. The findings were analyzed with respect to age distribution, clinical presentation, radiological classification, cytological diagnosis, and their correlation.

Table 1: Age-wise Distribution with Cytological Diagnosis

Age Group (Years)	Benign (C2)	Atypical (C3)	Suspicious (C4)	Malignant (C5)	Total	%
0–19	6	0	0	0	6	7.9
20–39	39	7	2	1	49	64.5
40–59	6	3	3	4	16	21.1
60–69	1	1	0	3	5	6.6
Total	52	11	5	8	76	100

The majority of patients were in the 20–39 years age group (64.5%), indicating higher prevalence of breast lumps in younger women. In all age categories, benign lesions (C2) were more common, particularly in younger individuals. A statistically significant

tendency of increased malignancy with age was shown by the higher frequency of malignant lesions (C5) in later age groups (40 years and above) ($p < 0.05$).

Table 2: Pain vs Cytological Diagnosis

Pain Status	Benign (C2)	Atypical (C3)	Suspicious (C4)	Malignant (C5)	Total
Painful	10	0	1	3	14
Painless	42	11	4	5	62
Total	52	11	5	8	76

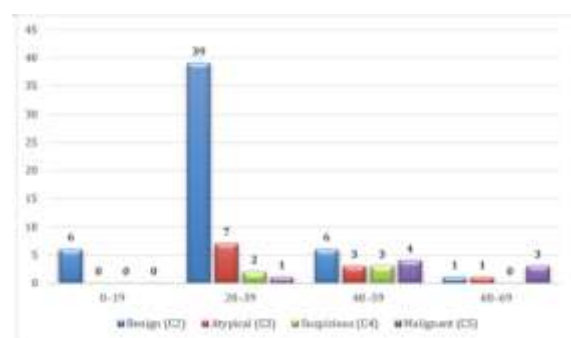


Figure 1: Age-wise Distribution with Cytological Diagnosis

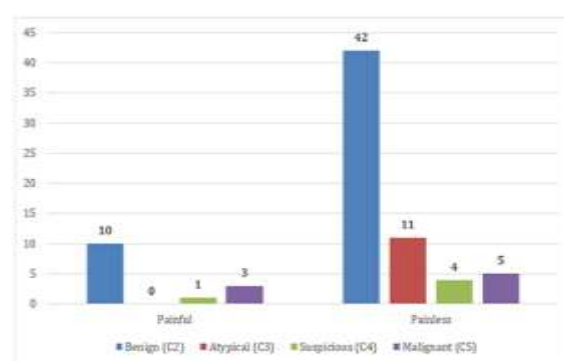


Figure 2: Pain vs Cytological Diagnosis.

Most patients presented with painless breast lumps (81.6%). Benign lesions were more commonly associated with painless presentation, whereas malignant lesions were relatively more frequent

among painful lumps. However, this association was not statistically significant ($p > 0.05$), indicating that pain alone is not a reliable predictor of malignancy.

Table 3: Radiological Findings (BI-RADS Classification)

BI-RADS Category	Interpretation	No. of Patients	%
BI-RADS 2	Benign	50	65.79
BI-RADS 3	Probably benign	12	15.79
BI-RADS 4	Suspicious for malignancy	9	11.84
BI-RADS 5	Highly suggestive of malignancy	5	6.58
Total		76	100

BI-RADS category 2 lesions constituted the majority (65.79%), indicating a predominance of benign findings on ultrasonography. Higher BI-RADS

categories (4 and 5), suggestive of malignancy, accounted for 18.42% of cases, highlighting the importance of imaging in risk stratification.

Table 4: Cytomorphological Diagnosis (IAC Yokohama System)

IAC Category	Diagnosis	No. of Patients	%
C2	Benign	52	68.4
C3	Atypical / Probably benign	11	14.5
C4	Suspicious for malignancy	5	6.6
C5	Malignant	8	10.5
Total		76	100

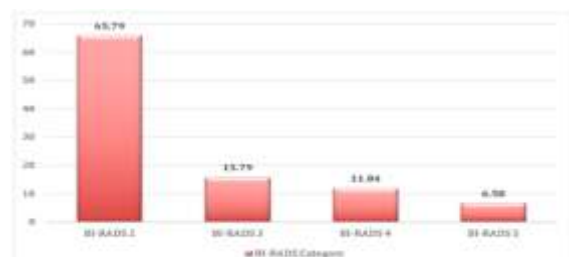


Figure 3: Radiological Findings (BI-RADS Classification)

Benign lesions (C2) were the most common cytological diagnosis (68.4%). Malignant lesions (C5) constituted 10.5% of cases. The atypical and suspicious categories together formed a smaller

proportion but are clinically significant due to their diagnostic uncertainty and need for further evaluation.

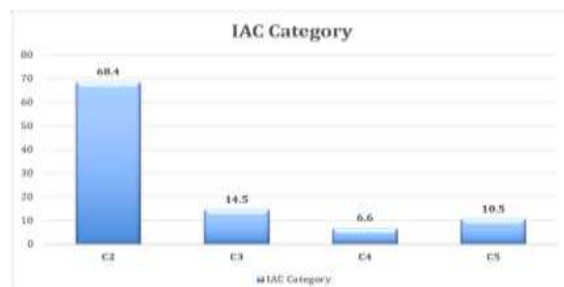


Figure 4: Cytomorphological Diagnosis (IAC Yokohama System).

Table 5: Correlation between BI-RADS and IAC Categories

IAC Category	Corresponding BI-RADS	Correlated Cases	Total Cases	Correlation (%)
C2	BI-RADS 2	43	52	82.69%
C3	BI-RADS 3	4	11	36.36%
C4	BI-RADS 4	4	5	80.00%
C5	BI-RADS 5	4	8	50.00%
Total	—	55	76	72.36%

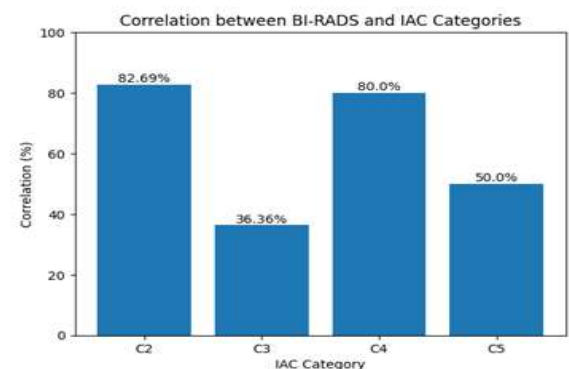


Figure 5: Correlation between BI-RADS and IAC Categories

The overall concordance between radiological (BI-RADS) and cytological (IAC) findings was 72.36%. Benign lesions (C2-BI-RADS 2) showed the best agreement, followed by suspicious lesions. Atypical (C3) and malignant (C5) categories showed lower concordance, indicating difficulties in diagnosing borderline patients. The reliability of integrated diagnostic modalities was highlighted by the statistically substantial ($p < 0.05$) correlation between BI-RADS and cytological categories.

DISCUSSION

The present study evaluated 76 female patients with palpable breast lumps using a triple assessment

approach comprising clinical examination, ultrasonography, and FNAC. The results emphasize how crucial it is to combine cytological and clinicoradiological factors for precise breast lesion identification and treatment. According to [Table 1], the majority of patients in the current research were between the ages of 20 and 39 (64.5%), with younger women more likely to have benign lesions. This finding is in line with earlier research showing that malignant tumors are usually seen in older women, whereas benign breast disorders like fibroadenoma are more frequent in younger age groups.^[1,11] This study's higher incidence of malignant lesions in individuals over 40 confirms the documented link between growing older and an increased risk of breast cancer. Donegan and colleagues have shown similar age-related changes, highlighting the necessity of increased clinical suspicion in older patients.^[12]

In terms of clinical presentation, Table 2 shows that the majority of patients (81.6%) had breast lumps that were painless. This result is consistent with previous research showing that breast lumps are frequently painless, especially when they are benign.^[13] In this analysis, pain was linked to a slightly greater percentage of malignant cases; however, this connection was not statistically significant ($p > 0.05$). This supports the idea—which has also been emphasized in other reports—that pain cannot accurately distinguish between benign and malignant breast tumors.^[14]

Most lesions were classified as BI-RADS 2 (65.79%), suggesting benign results, according to radiological examination using BI-RADS classification [Table 3]. This prevalence of benign radiological categories is similar to earlier research where the majority of breast lump examinations are benign lesions.^[7] Nonetheless, a significant percentage of cases (18.42%) fit into BI-RADS categories 4 and 5, which are indicative of cancer. The BI-RADS system is well known for its ability to standardize imaging interpretation and direct clinical treatment choices.

Benign lesions (C2) made up 68.4% of cases, while malignant lesions (C5) made up 10.5%, according to cytological examination utilizing the IAC Yokohama method [Table 4]. These results are in line with research by Field et al., which showed that most FNAC samples are benign, with a lesser but clinically relevant percentage of malignant cases.^[15] The existence of suspicious (C4) and atypical (C3) categories draws attention to the intrinsic limits of cytology in some borderline instances, requiring further histopathological confirmation.

One important component of this study is the relationship between BI-RADS and IAC categories. Table 5 illustrates that the total concordance rate was 72.36%, with benign lesions exhibiting the highest level of agreement (82.69%). This excellent concordance in benign categories is consistent with earlier research that found a substantial association between cytology and imaging in tumors that were obviously benign.^[16] Similarly, 80% of suspect

categories showed strong agreement, suggesting that both modalities are useful in detecting lesions with a higher propensity for malignancy.

However, the atypical (36.36%) and malignant (50%) groups showed worse concordance. This heterogeneity might be explained by discrepancies in interpretation, sample mistakes, or overlapping cytological characteristics. These differences, which have been documented in past research, highlight the need of a multidisciplinary approach that includes histological validation when required.^[16] The reliability of integrating these diagnostic modalities is further validated by the study's statistically significant relationship ($p < 0.05$) between BI-RADS and cytological results. Overall, the study's results highlight how well the triple assessment method works for evaluating breast masses.

Combining clinical examination, imaging, and cytology improves diagnostic precision, minimizes needless surgery in benign patients, and makes early cancer identification easier. These findings are consistent with the body of research that supports the use of both radiographic and cytological examination in the assessment of breast lesions.^[14,15] In summary, the current study shows that effective diagnosis and treatment of breast tumors depend heavily on clinicoradiological and cytological connection. The combined technique is nevertheless a dependable, economical, and minimally intrusive method, especially in settings with limited resources, despite certain drawbacks in unusual and borderline categories.

CONCLUSION

The present study highlights the importance of a combined clinicoradiological and cytological approach in the evaluation of breast lumps. Malignant lesions were more common in older age groups, while benign lesions accounted for the majority of cases in our research, especially among younger women. With the majority of lesions classified as benign, ultrasonography utilizing the Breast Imaging Reporting and Data System (BI-RADS) proven to be an efficient method for initial risk assessment. The International Academy of Cytology Yokohama System, when used to interpret fine needle aspiration cytology, showed great value in differentiating benign from malignant lesions. The reliability of the triple evaluation technique was reinforced by the strong general congruence between radiological and cytological results, especially in benign and questionable categories. Lower agreement in the malignant and atypical groups, however, suggests that further histological confirmation and careful interpretation are necessary in these situations. The study highlights how combining clinical examination, imaging, and cytology enhances diagnostic precision, minimizes needless surgical procedures in benign patients, and promotes early cancer diagnosis and treatment. This

method's low cost and minimum invasiveness make it particularly useful in environments with limited resources.

Limitations of the study

The study has certain limitations that must be considered. The sample size was relatively small (76 cases), which may limit the generalizability of the findings. Being a single-center study, the results may not reflect the broader population. Histopathological confirmation was not available for all cases, particularly benign lesions, which could affect the accuracy of correlation analysis. Additionally, interobserver variability in both radiological and cytological interpretation may have influenced the results. The lower concordance observed in atypical and suspicious categories also highlights inherent limitations of FNAC, including sampling errors and overlapping cytological features. Further large-scale, multicentric studies with histopathological correlation are recommended to validate and strengthen these findings.

REFERENCES

1. Malherbe F, Nel D, Molabe H, Cairncross L, Roodt L. Palpable breast lumps: An age-based approach to evaluation and diagnosis. *S Afr Fam Pract* (2004). 2022 Sep 23;64(1):e1-e5. doi: 10.4102/safp.v64i1.5571. PMID: 36226953; PMCID: PMC9575372.
2. Loud JT, Murphy J. Cancer Screening and Early Detection in the 21st Century. *Semin Oncol Nurs*. 2017 May;33(2):121-128. doi: 10.1016/j.soncn.2017.02.002. Epub 2017 Mar 23. PMID: 28343835; PMCID: PMC5467686.
3. Freihat O, Sipos D, Kovacs A. Global burden and projections of breast cancer incidence and mortality to 2050: a comprehensive analysis of GLOBOCAN data. *Front Public Health*. 2025 Oct 30;13:1622954. doi: 10.3389/fpubh.2025.1622954. PMID: 41246094; PMCID: PMC12611818.
4. Karim MO, Khan KA, Khan AJ, Javed A, Fazid S, Aslam MI. Triple Assessment of Breast Lump: Should We Perform Core Biopsy for Every Patient? *Cureus*. 2020 Mar 30;12(3):e7479. doi: 10.7759/cureus.7479. PMID: 32351857; PMCID: PMC7188022.
5. Ademola SA, Michael AI, Takure AO, Lawal TA. A LUMP MODEL FOR MEDICAL STUDENTS' CLINICAL EVALUATION. *Ann Ib Postgrad Med*. 2024 Apr 30;22(1):29-33. PMID: 38939885; PMCID: PMC11205707.
6. Appleton DC, Hackney L, Narayanan S. Ultrasonography alone for diagnosis of breast cancer in women under 40. *Ann R Coll Surg Engl*. 2014 Apr;96(3):202-6. doi: 10.1308/003588414X13824511649896. PMID: 24780784; PMCID: PMC4474049.
7. Merjane V, Perin DMP, Bacha PMGE, Miranda BMM, Bitencourt AGV, Iared W. Breast Imaging Reporting and Data System (BI-RADS®): a success history and particularities of its use in Brazil. *Rev Bras Ginecol Obstet*. 2024 Mar 15;46:e-rbgo6. doi: 10.61622/rbgo/2024AR06. PMID: 38765508; PMCID: PMC11075429.
8. Ogbuanya AU, Anyanwu SN, Iyare EF, Nwigwe CG. The Role of Fine Needle Aspiration Cytology in Triple Assessment of Patients with Malignant Breast Lumps. *Niger J Surg*. 2020 Jan-Jun;26(1):35-41. doi: 10.4103/njs.NJS_50_19. Epub 2020 Feb 10. PMID: 32165834; PMCID: PMC7041348.
9. Sah K, Kharel B, Prasad Sah N. Standardized reporting of breast FNAC using the International Academy of Cytology Yokohama system and its comparison with histopathology: a cross-sectional study. *Ann Med Surg (Lond)*. 2025 Apr 22;87(6):3189-3193. doi: 10.1097/MS9.0000000000003322. PMID: 40486572; PMCID: PMC12140665.
10. Hussain S, Mubeen I, Ullah N, Shah SSUD, Khan BA, Zahoor M, Ullah R, Khan FA, Sultan MA. Modern Diagnostic Imaging Technique Applications and Risk Factors in the Medical Field: A Review. *Biomed Res Int*. 2022 Jun 6;2022:5164970. doi: 10.1155/2022/5164970. PMID: 35707373; PMCID: PMC9192206.
11. Itteera MR, Gutierrez M, Patel KH. Addisonian Crisis in a 39-Year-Old Woman With Primary Adrenal Insufficiency. *Cureus*. 2026 Feb 14;18(2):e103607. doi: 10.7759/cureus.103607. PMID: 41853409; PMCID: PMC12991911.
12. Cao W, Chen HD, Yu YW, Li N, Chen WQ. Changing profiles of cancer burden worldwide and in China: a secondary analysis of the global cancer statistics 2020. *Chin Med J (Engl)*. 2021 Mar 17;134(7):783-791. doi: 10.1097/CM9.0000000000001474. PMID: 33734139; PMCID: PMC8104205.
13. Dixon JM, Mansel RE. ABC of breast diseases. Symptoms assessment and guidelines for referral. *BMJ*. 1994 Sep 17;309(6956):722-6. doi: 10.1136/bmj.309.6956.722. PMID: 7950527; PMCID: PMC2540826.
14. Thill M. Benign Breast Diseases. *Breast Care (Basel)*. 2018 Dec;13(6):400-401. doi: 10.1159/000495918. Epub 2018 Dec 12. PMID: 30800033; PMCID: PMC6381924.
15. Field AS, Raymond WA, Rickard M, et al. IAC Yokohama System. *Acta Cytol*. 2019;63:257-273.
16. Sharma AD, Ojha K, N NB. Diagnostic Utility of Fine-Needle Aspiration Cytology (FNAC) and Frozen Section Against Histopathology in Evaluating Benign and Malignant Breast Lesions. *Cureus*. 2024 Jan 28;16(1):e53108. doi: 10.7759/cureus.53108. PMID: 38414704; PMCID: PMC10897751.