



## Original Research Article

# SENSITIVITY AND SPECIFICITY OF MRI IN DIAGNOSING THE ETIOLOGY OF VERTEBRAL COMPRESSION FRACTURE

Sandeep Kumar<sup>1</sup>, Pankaj kumar<sup>2</sup>, Ravikanti Satyaprasad<sup>3</sup>, Chiranji Lal Goel<sup>4</sup>, Anu Sharma<sup>5</sup>

<sup>1</sup>Consultant Radiologist, Department of Radiodiagnosis, Queen Elizabeth hospital, Lewisham and Greenwich NHS trust, London United Kingdom

<sup>2</sup>Consultant radiologist, Department of Radiodiagnosis, O P Jindal Institute of Cancer and Cardiac Research, Model Town, Hisar, Haryana, India.

<sup>3</sup>HOD Senior Consultant Radiologist, Department of Radiodiagnosis, Apollo Hospital Jubilee hills Hyderabad India

<sup>4</sup>Consultant radiologist, Department of Radiodiagnosis, O P Jindal Institute of Cancer and Cardiac Research, Model Town, Hisar, Haryana, India.

<sup>5</sup>Consultant radiologist, Department of Radiodiagnosis, O P Jindal Institute of Cancer and Cardiac Research, Model Town, Hisar, Haryana, India.

Received : 17/12/2024  
Received in revised form : 11/02/2025  
Accepted : 26/02/2025

### Corresponding Author:

**Dr. Anu Sharma**

Consultant radiologist, Dept of Radiodiagnosis, O P Jindal Institute of Cancer and Cardiac Research, Model Town, Hisar, Haryana, India  
Email: dr.vashistanu72@gmail.com

DOI: 10.70034/ijmedph.2025.2.23

Source of Support: Nil,

Conflict of Interest: None declared

**Int J Med Pub Health**

2025; 15 (2); 118-125

### ABSTRACT

**Background:** Vertebral compression fractures (VCFs) are common in aging populations and can result from osteoporosis, trauma, malignancy, or infection. Differentiating between benign and malignant causes is critical for appropriate treatment. MRI is a key diagnostic tool, but its sensitivity and specificity in identifying the etiology of VCFs require further evaluation. This study aims to assess the diagnostic accuracy of MRI in distinguishing different causes of vertebral compression fractures.

**Materials and Methods:** This prospective study was conducted at Apollo Hospital, Hyderabad, including 49 patients with vertebral collapse who underwent MRI. Patients were categorized based on the etiology of VCFs: osteoporotic, traumatic, malignant, or infectious. Various MRI features such as pedicle involvement, posterior element destruction, epidural mass, and paraspinal soft tissue involvement were analyzed for their sensitivity and specificity in diagnosing VCF causes. Histopathology and clinical follow-up were used as reference standards.

**Results:** Among 49 patients, 53% were male and 47% female, with the majority (67%) having dorsal vertebral involvement. Osteoporotic fractures accounted for 35%, malignant 27%, traumatic 20%, and infectious 18%. MRI features such as pedicle involvement (92% sensitivity, 91% specificity), convex posterior border (53% sensitivity, 94% specificity), and epidural mass had high specificity for malignancy. Contiguous vertebral involvement and endplate disruption were more indicative of benign fractures. A combination of MRI features significantly improved diagnostic accuracy.

**Conclusion:** MRI is a highly specific tool for differentiating malignant from benign VCFs, particularly when multiple significant features are present. Pedicle involvement and convex posterior border are among the most reliable indicators of malignancy. Early and accurate MRI-based diagnosis is essential for guiding appropriate clinical management.

**Keywords:** Vertebral compression fracture, MRI, malignancy, osteoporosis, pedicle involvement, diagnostic accuracy, spinal imaging.

### INTRODUCTION

Vertebral fractures are uncommon in younger years, although their incidence increases considerably in

later years with increasing prevalence of low bone mass as a result of osteoporosis. Because osteopenia is much more common than osteoporosis, almost half of all vertebral fractures tend to occur in subjects with

osteopenia rather than with osteoporosis, as assessed by T score.<sup>[1,2]</sup> Nevertheless, the occurrence of a less-traumatic or nontraumatic vertebral fracture in an otherwise healthy individual is indisputable evidence of reduced bone strength, and, in this respect, osteoporosis, irrespective of T-score measurement. Vertebral fractures provide a significant warning of subsequent osteoporotic fracture, as they tend to occur more frequently and earlier than other osteoporosis-related fractures of the proximal femur, distal radius, and other sites.<sup>[3]</sup>

Vertebral fractures are associated with a poorer quality of life because of limitation in physical mobility and impaired social function, an effect particularly noticeable in patients with more severe fractures, multiple fractures, and lumbar fractures.<sup>[4,5]</sup> As well as increased morbidity, increased mortality is also associated with vertebral fracture.<sup>[6,7]</sup> A clinical scenario therefore exists of patients sustaining an isolated vertebral fracture and going on to develop several new fractures over the ensuing years. This process, referred to as the vertebral fracture cascade, is likely to be multifactorial in origin, related in part to poor bone quality, disordered spine biomechanics, and neuromuscular dysfunction.<sup>[8]</sup>

A vertebral fracture cascade leads to deteriorating physical and psychosocial function, which progressively declines with each new vertebral fracture. The World Health Organization has recognized the clinical importance of vertebral fracture, although defining “severe osteoporosis” as a T score of 2.5 and the presence of an osteoporotic fracture. Recognition is important because subjects with a vertebral fracture and a T score of less than 2.5 appear to be those most likely to benefit from timely antiosteoporotic drug therapy. Yet, despite the clear undisputed clinical relevance of vertebral fractures, these remain sorely underdiagnosed in everyday practice.<sup>[9-11]</sup> Two main reasons account for this inadequacy. First, vertebral fractures frequently do not present as a clinically recognizable event. Typical symptoms of vertebral fracture are back pain and limitation of movement. Both of these symptoms are common in elderly subjects.<sup>[11,12]</sup> Second, many radiologically apparent vertebral fractures go unreported.

Although the radiologic diagnosis of a moderate to-severe vertebral body fracture is straight forward, radiologic assessment of a mild vertebral fracture remains contentious. First, mild anterior or posterior wedging is a normal feature of thoracic and lumbar vertebral bodies. Second, short vertebral height is a feature of aging and spinal degeneration in the absence of detectable osteoporosis fracture as well as a feature of other spinal disorders such as Scheuermann disease.<sup>[13]</sup> Third, as opposed to the more “all or none” presentation of appendicular fracture, vertebral fractures vary considerably in severity, are often incremental in progression, are often not associated with any discernible radiographic cortical disruption, and often occur in

the absence of significant trauma or pain.<sup>[14]</sup> Fourth, developmental or degenerative scoliosis may lead to radiographic obliquity and side-to-side discrepancy in vertebral body height. The current best standard for clinical practice and cross-sectional studies is to use a semiquantitative method of fracture analysis by an experienced reader using standardized radiographs or morphometric x-ray absorptiometry supported by radiographic assessment.

The purpose of this study is to review all recent magnetic resonance (MR) imaging aspects of differentiating osteoporotic, traumatic, malignant and infectious vertebral collapse. Magnetic resonance (MR) imaging is a well-known useful method in valuating disease of bone and bone marrow. Several MR imaging findings have been published as useful measures for differentiating benign and malignant compression fracture. Therefore, in the present study, we also tried to explore whether the previously published MR conducted imaging features are applicable in differentiating a malignant compression fracture from a benign process in the presented population.

## MATERIALS AND METHODS

This study is a prospective study conducted at Apollo Hospital, Jubilee Hills, Hyderabad, from December 1, 2013, to June 30, 2015. The study population included all cases of vertebral collapse referred to the radiology department for MRI evaluation. The sample size consisted of 49 patients, selected after screening approximately 102 cases, with exclusions based on the study criteria. Some patients were not included due to the unavailability of histopathology reports, while others were excluded as they did not meet the study's inclusion criteria. No patients refused to participate in the study.

The inclusion criteria included patients of all age groups and both sexes with vertebral collapse, whether solitary or multiple. Exclusion criteria involved patients with benign or malignant spinal involvement without associated collapse, those who had undergone previous spine surgery, and patients who were not MR-compatible.

### Study Protocol and Procedure

#### Screening and Patient Inclusion:

All patients referred to the radiology department of Apollo Hospital, Jubilee Hills, Hyderabad, were screened, and those meeting the inclusion and exclusion criteria were informed about the study, its purpose, and the reason for participation. Informed consent was obtained (Appendix II). A structured study proforma (Appendix I) was completed for each included patient, capturing basic demographic data such as age and clinical history. Each patient then underwent MRI examination. The MRI scans were reviewed by the study's primary investigator and confirmed by a senior consultant radiologist. The findings were recorded in the study proforma (Appendix I). Each patient's medical records were

reviewed, and the histopathology of the vertebral lesion was determined and used as the gold standard for the final diagnosis. In cases where vertebral body biopsy was not feasible, other imaging modalities such as DEXA, vitamin D levels, and X-ray were considered to establish a specific diagnosis.

#### Study Equipment

The study was conducted using a Philips Achieva 1.5 Tesla MRI machine with a body surface coil and non-ionic contrast medium when required.

#### Study Imaging Protocol

##### Patient Screening:

As with all MRI procedures, proper screening was conducted before imaging the spine. Special attention was given to detecting ferromagnetic intraocular foreign bodies, aneurysm clips, pacemakers, and any previous spinal surgeries (such as fusions or wirings, which could be ferromagnetic).

##### Special Considerations for Patients with Spinal Cord Injuries:

Patients undergoing MRI for suspected spinal cord compression were handled with caution, as improper movement could lead to complete spinal cord injury. Earplugs were provided to minimize acoustic damage, and premedication and physiological monitoring were conducted for patients experiencing severe pain.

##### Coil Selection and Positioning:

Patients were positioned supine, centered to the spine coil. Phased array spine coils were preferred for complete spine imaging.

- **Longitudinal Landmarking:** Mid-sagittal plane along the sternal notch, xiphoid process, or belly button, depending on the portion of the spine being imaged.
- **Coronal Landmarking:** Middle of the neck (cervical spine), thorax (thoracic spine), or abdomen (lumbar spine).
- **Axial Landmarking:**
  - Cervical spine: C3 – C4
  - Thoracic spine: At the level of the manubrium or nipple line
  - Lumbar spine: At the level of the iliac crest, approximately at the navel

#### MRI Characteristics Evaluated for Differentiating Benign and Malignant Vertebral Collapse

The following MRI features were analyzed:

- Signal intensity of the collapsed vertebrae on T1- and T2-weighted images
- Homogeneous or heterogeneous marrow replacement and areas of normal marrow sparing
- Pedicle or posterior element involvement
- Convex posterior border
- Presence of an epidural or paravertebral mass lesion
- Retropulsion of posterior bony fragments
- Intravertebral fluid sign, seen as focal, linear, or triangular areas of high signal intensity adjacent

to vertebral endplates on T2-weighted and STIR images

- Endplate disruption
- Disc involvement, indicated by abnormal signal intensity (hypointense on T1-weighted images, hyperintense on T2-weighted images, and post-contrast enhancement with reduced disc height)
- Paravertebral soft tissue collection, differentiating abscesses from soft-tissue masses (abscesses show low signal intensity on T1-weighted images, high intensity on T2-weighted images, and ring enhancement with contrast, whereas soft-tissue masses show solid enhancement with contrast)
- Contiguous vertebral involvement

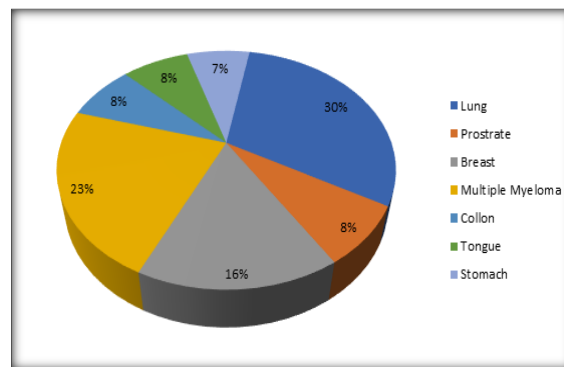
#### Study Analysis

All study data from the proforma sheets were entered into an electronic spreadsheet. A descriptive characterization of all patients was performed, followed by classification into benign and malignant cases. Benign cases were further classified as traumatic, infective, or osteoporotic. The sensitivity, specificity, positive predictive value (PPV), and negative predictive value (NPV) for each MRI feature were calculated to differentiate between benign and malignant vertebral collapse. Statistical analysis was conducted using the following methods: Calculation of Sensitivity and Specificity, Descriptive Statistics, Chi-Square Test. A p-value of <0.05 was considered statistically significant. Due to the small sample size in this study, Fisher's exact test was used instead of the Chi-square test for statistical validation.

## RESULTS

The present study was conducted in the Department of Radiodiagnosis, Apollo Hospital, Jubilee hills Hyderabad (Telangana) in 49 patients with vertebral collapse.

Of these 49 cases with vertebral collapse, 22 were confirmed with biopsy and the remaining 27 cases were confirmed either by further imaging studies or a clinical follow-up.



**Figure 1: Distribution of metastatic vertebral collapse on the basis of primary site of origin**

**Table 1: Age Distribution**

Age (in years)	Total
10-Jan	0
20-Nov	1
21-30	2
31-40	3
41-50	5
51-60	15
61-70	15
71-80	8
Total	49(100%)

- In our study mean age of the patient's was 58 years
- Maximum patient were in age group 51-60 and 61 to 70 (31% each)

**Table 2: Shows Sex Distribution**

Age (in years)	Males	Females
10-Jan	0	0
20-Nov	0	1
21-30	1	1
31-40	2	1
41-50	3	2
51-60	7	8
61-70	10	5
71-80	3	5
Total	26 (53%)	23(47%)

**Table 3: Shows Distribution of Lesions as Per Anatomic Site of Origin**

S.no	Anatomic site	No. of fracture's	Percentage
1.	Cervical spine	6	7%
2.	Dorsal spine	52	67%
3.	Lumbar	20	26%
Total		78	100%

\*Note-one patient may have multiple fractures

- The Dorsal spine followed by Lumbar spine were the most common sites involved amounting to 67% and 26% of total vertebral collapsed respectively.
- Most of the cases showed simultaneous involvement of dorsal and lumbar spine.

**Table 4: Spectrum of Various Etiologies of Vertebral Collapse**

S.no	LESION	No. of Cases
1	Osteoporotic	17
2	Traumatic	10
3	Infective	9
4	Malignant	13
6	Total	49

- Among 49 cases seventeen (35%) presented with osteoporotic vertebral collapse
- Ten cases (20%) had history of previous trauma
- Thirteen cases (27%) out of 49 patients neoplastic etiology in our study.
- Infective etiology was seen in nine (18%) cases which included tuberculosis as the major cause

**Table 5: Distribution of Lesions According to Number of Vertebrae**

Etiology	Solitary	Multiple
Osteoporotic	7	10
Traumatic	7	3
Infective	4	5
Malignant	7	6
Total	25	24

- Among 49 cases, twenty-five (51%) showed solitary vertebral collapse, seven each owing to osteoporotic, traumatic, malignant etiology and four due to infective etiology.
- Twenty-four cases (49%) showed multiple vertebral collapses, Ten of them were osteoporotic in nature, three traumatic.
- Diffuse involvement of all was not seen in any cases.

**Table 6: MRI Feature's of Etiology of Vertebral Collapse**

MRI FEATURE'S	osteoporotic	Malignant	Infective	Traumatic
1 .Convex posterior vertebral border	2(11%)	7(54%)	0	0
2. Pedicle involvement	2(11%)	12(92%)	1(11%)	0
3 .Posterior elements involvement	0	5(38%)	1(11%)	0

4. Epidural mass	0	4(30%)	0	0
5. Paraspinal mass	0	5(38%)	0	0
6. Other spinal metastases	0	6(46%)	0	0
7. Retropulsion of posterior bony fragment	10(59%)	3(23%)	2(22%)	5(50%)
8. Low signal intensity band	8(47%)	1(7%)	0	7(70%)
9. Intravertebral fluid sign	4(23%)	1(7%)	0	0
10. Contiguous vertebral involvement	3(18%)	4(30%)	0	0
11. End plate disruption	7(41%)	2(5%)	7(78%)	0
12. Disc involvement	1(5%)	0	6(67%)	0
13. Paravertebral soft tissue collection	1(5%)	0	6(67%)	3(30%)
14. Sparing normal marrow signal intensity	13(76%)	4(30%)	2(22%)	7(70%)
15. Cord compression	6(35%)	8(61%)	4(44%)	4(40%)

**Table 7: Vertebral collapse associated with cord compression leading to paraparesis**

S. No	Lesion	No. of cases
1	Osteoporotic	6
2	Traumatic	4
3	Infection	4
4	Malignant	8
	Total	22

- 45% of the total cases of vertebral collapse presented with symptoms of cord compression.
- Malignant etiology was most commonly associated with cord compression comprising 8 cases out of 22
- Osteoporotic as the second most common cause comprising 6 cases.

**Table 8: Summary of MRI feature's of malignant and benign vertebral collapse**

MRI FINDING	BENIGN	MALIGNANT	SENSITIVITY	SPECIFICITY	PPV	NPV	P value
Convex posterior vertebral border	2	7	53.80%	94.44%	77.78%	85%	0.0005
Pedicle involvement	3	12	92.31%	91.67%	80%	97%	<0.0001
Posterior elements involvement	1	5	38.46%	97.22%	83.33%	81.40%	0.0034
Epidural mass	0	4	30.77%	100%	100%	80%	0.0034
Paraspinal mass	0	5	38.46%	100%	100%	81.82%	0.0007
Other spinal metastases	0	6	46.15%	100%	100%	83.72%	0.0001
Retropulsion of posterior bony fragment	17	3	23.08%	52.78%	15.00%	65.52%	0.1912
Low signal intensity band	15	1	7.69%	58.32%	6.25%	63.64%	0.0374
Intravertebral fluid sign	6	1	7.69%	83.33%	14.29%	71.43%	0.6577
Contiguous vertebral involvement	3	4	30.77%	91.67%	57.14%	78.57%	0.0696
End plate disruption	14	2	15.38%	61.11%	12.50%	66.67%	0.1741
Disc involvement	7	0	0%	80.56%	0%	69.05%	0.1668
Paravertebral soft tissue collection	10	0	0%	72.22%	0%	66.67%	0.0448
Sparing normal marrow signal intensity	22	43	30.77%	38.89%	15.38%	60.87%	0.1038
Cord compression	14	8	61.54%	61.11%	36.36%	81.48%	0.2022

## DISCUSSIONS

Vertebral collapse is one of the most common clinical problems faced, especially in the elderly.<sup>[15]</sup> Vertebral collapse has fascinated radiologists for long and it has been always challenging to arrive at a definitive diagnosis based on the imaging data. While diagnosing acute, benign traumatic types is usually not complicated, difficulties arise in determining the etiology of vertebral collapse when there is no history of significant trauma, especially in older populations.<sup>[16]</sup> MRI is a well validated method in

evaluating disease of bone and bone marrow. Several MR imaging findings have been published as useful measures for differentiating among various etiologies of vertebral collapse. Hence the present study was conducted to explore the role of MRI in evaluating vertebral collapse and whether the previously published MR imaging features are applicable in differentiating a malignant compression fracture from a benign process in the presented population. In our study, pedicle involvement came out to be the most consistent finding with sensitivity and specificity reaching up to 92.3% and 91.67%



respectively. It was followed by convex posterior border as the most reliable individual finding with sensitivity 53.8% and specificity 94.44%. Among 36 cases with non-metastatic vertebral collapse, pedicle involvement was seen in just 2 cases making it an individual finding with high negative predictive value i.e. 97% and positive predictive value of 80%. This finding is plausible because in most cases of malignant compression fractures, tumoral cell has already spread to the pedicles and neural arch before it collapses, whereas the reactive bone marrow changes usually spare the pedicles in osteoporotic compression fractures.<sup>[17,18]</sup> **Pongpornsup et al** (46) had reported that MR imaging features suggestive of malignant vertebral compression fracture were convex posterior border of the vertebral body, involvement of pedicle or posterior element, epidural or paraspinal mass and destruction of bony cortex.<sup>[17]</sup> Among these, involvement of pedicle or posterior element was the most reliable finding for malignant collapse with sensitivity and specificity reaching upto 91.4% and 82.6% respectively.

**ME Abdel-Wanis et al.**<sup>[19]</sup> reported MRI features of malignant vertebral collapse convex posterior border was 71% sensitive and 99% specific, pedicle involvement 95% sensitive and 70% specific, posterior element involvement was 72% sensitive and 87% specific. Similarly **Jung et al.**<sup>[20]</sup> also found out that these MRI features are highly sensitive and specific

**Loige et al.**<sup>[21]</sup> emphasized tuberculosis as an important entity, besides neoplasms, in the differential diagnosis of pathologies involving a single vertebral body. Though we did not encounter any case with tubercular solitary vertebral collapse in our study. Among 25 cases with solitary vertebral collapse, post traumatic, osteoporotic and neoplastic etiology were equally found, however we also found 4 cases of solitary vertebral collapse with infective etiology.

**Shih TT et al, Fu TS et al and Tehranzadeh et al.**<sup>[15,22,23]</sup> used various MRI characteristics as criteria to differentiate benign and malignant vertebral collapse. They used various MRI characteristics, including signal intensity, gadolinium enhancement, epidural compression, multiple compression fractures, associated paraspinal soft tissue mass, pedicle involvement, and posterior element involvement. They tested the predictive value of each MRI characteristic for distinguishing malignant from benign osteoporotic vertebral fractures by statistical analysis.

**Tehranzadeh et al.**<sup>[22]</sup> also stressed on the importance of restoration of normal fatty marrow and restoration of normal signal intensity on T2 weighted images as features of osteoporotic benign collapse which again reinforces the importance of follow up examination in doubtful cases. They also demonstrated intense enhancement of disc, end plates and adjacent marrow with intense enhancement of paraspinal and/or epidural soft tissue as highly predictive findings of infectious vertebral collapse. In

our study, gadolinium contrast study could not be performed in appreciable number of cases because most of the times patient is unable to afford the cost of contrast. However, destruction of adjacent end plates with decreased vertebral height, marrow oedema and disk hyperintensity on STIR images, paraspinal and epidural soft tissue collection with hyperintense signals on T2 weighted and STIR sequences were highly predictive of infectious vertebral collapse in our study. Out of 9 cases with infective vertebral collapse, 6(67%) cases had paravertebral and epidural soft tissue collection with cord compression in 44 percent of them.

**Jung HS et al discriminated.**<sup>[20]</sup> metastatic from acute osteoporotic compression fractures on the basis of MR imaging findings and computed the differences. They deduced the following imaging findings suggestive of acute osteoporotic compression fractures: a low signal intensity band on T1 and T2 weighted images, Sparing normal bone marrow signal intensity of the vertebral body, retropulsion of a posterior bone fragment, and multiple compression fractures.<sup>[18]</sup> We found normal bone marrow signal intensity in most of the cases, however linear intravertebral hyperintense signal on sagittal STIR sequences was seen in 4 cases of 17 osteoporotic collapse. Multiple vertebrae involvement in lumbar region and acute Schmorl's node displaying hyperintense signal on T2 weighted and STIR sequences were associated findings. Presence of Schmorl's node and fluid sign in collapsed vertebrae showed high specificity and negative predictive values for malignancy. However as malignancy and osteoporosis, both are diseases of aged, simultaneous presence of both may be seen in few cases. Vertebral collapse in an old patient with known primary is not due to metastasis always, and may be due to osteoporosis.<sup>[15,16]</sup> Careful study of above mentioned findings in such patients may lead to the correct diagnosis, however histopathological examination or follow up is mandatory for confirmation.

**Yuh WTC et al.**<sup>[24]</sup> also highlighted several facts about fluid sign in osteoporotic fractures and their mechanism. The explanation for the presence of fluid sign in osteoporotic fractures is based on the arterial supply pattern to the vertebral system. The area surrounding the end plate is a linear strip of bone marrow that has sparse blood supply and is therefore susceptible to ischemic injury.<sup>[25]</sup> When compared with well vascularized metastatic bone marrow, the aged osteoporotic bone is characterized by increased fatty infiltration of the overall bone and has poor vascular supply and hence more prone to ischemic injury. In addition, malignant fracture usually occurs after most or all of the bone marrow cavity is infiltrated with tumor, and the region surrounding the end plate is usually the first site for metastatic seeding. The blood supply may thus actually be increased in region of end plate in metastatic vertebral involvement and thus more resistance to ischemic injury. Thus it is unlikely to see fluid sign

in metastatic vertebral collapse which is a sign of intravertebral avascular necrosis.<sup>[26]</sup> The pathogenesis of osteonecrosis in vertebral body is two fold; the first mechanism is that of avascular necrosis, known as Kummel disease. The second mechanism is focal bone weakness in patients with osteoporosis in conjunction with minor trauma or even because of tumor infiltrate in metastatic disease. (66) Findings in our study was in accordance with the above mentioned mechanism with the high overall sensitivity and positive predictive value of fluid sign for osteoporotic collapse.

Metastatic disease and osteoporosis may have diffuse involvement and present with multiple lesions of the spine.<sup>[27,28]</sup> In our study, both malignant and osteoporotic compression fractures showed their propensity towards thoracolumbar vertebrae.

We also studied the distribution of metastatic vertebral collapse on the basis of primary site of origin, lung cancer came out to be the most common primary site followed by multiple myeloma, breast and prostate. Dorsal vertebrae were seen to be most commonly involved in patients with lung cancer, however cervical and lumbar vertebral segments too were not unaffected. This explains the haematogenous route as the primary route of metastasis than paravertebral venous system and lymphatics.<sup>[29-31]</sup> In our study, dorsal spine was involved in 40 cases, out of which ten were due to metastatic involvement, however it does not lead the observer to any conclusion as rest other pathologies showed similar propensity towards the involvement of dorsal vertebral segments.

The early detection of spinal metastasis by plain radiograph is difficult as most tumours are not apparent on plain film until more than 30% of the vertebral body has been destroyed.<sup>[32]</sup> However, MRI can detect early vertebral and pedicle destruction. In our study, 3 benign cases had pedicle involvement and on the other hand, 7 malignant cases had pedicle destruction with expansile soft tissue. This finding is significant in predicting malignancy.

**Rupp et al,**<sup>[33]</sup> concluded that posterior vertebral expansion help in the differentiation of osteoporotic from tumour compression fractures.<sup>[32]</sup> This is in accordance to our results. Most metastatic tumours of the spine spread to the vertebral body first and then later invade the pedicles and posterior elements. However, benign compression fractures are often confined to the anterior element. This characteristic is significant in the differentiation of benign from malignant vertebral fractures. Most of malignant compression fracture in the present study had hyposignal intensity on T1-weighted, mixed signal intensity on T2-weighted, no disc involvement, where as benign cause showed iso to hyposignal intensity on T1-weighted, varying signal on T2-weighted and disc involvement with hyperintense signals on sagittal STIR sequences.

## CONCLUSION

In this study of 49 patients with vertebral body collapse, 53% were male and 47% were female, with the majority (67%) having dorsal vertebral involvement. Solitary and multiple collapses were nearly equal (51% vs. 49%), with no cases of diffuse involvement. The most common etiology was osteoporosis (35%), followed by neoplastic (27%), traumatic (20%), and infective (18%) causes. MRI findings such as convex posterior border, pedicle involvement, epidural and paraspinal masses were statistically significant for malignancy, exhibiting high specificity but moderate sensitivity. Features like intravertebral fluid sign, contiguous vertebral involvement, and endplate disruption were not statistically significant. A combination of two or more MRI features greatly improved diagnostic accuracy, with pedicle involvement showing the highest sensitivity (92%) and specificity (91%) among malignant fractures, while contiguous vertebral involvement was the most specific (91%) for benign fractures.

## REFERENCES

1. Siris ES, Miller PD, Barrett-Connor E. Identification and fracture outcomes of undiagnosed low bone mineral density in postmenopausal women: results from the National Osteoporosis Risk Assessment. *JAMA* 2001; 286:2815–22.
2. Sanders KM, Nicholson GC, Watts JJ. Half the burden of fragility fractures in the community occur in women without osteoporosis. When is fracture prevention cost-effective? *Bone* 2006; 38:694–700.
3. Meunier PJ, Delmas PD, Eastell R. Diagnosis and management of osteoporosis in postmenopausal women: clinical guidelines. International Committee for Osteoporosis Clinical Guidelines. *Clin Ther* 1999;21(6):1025–44.
4. Lips P, van Schoor NM. Quality of life in patients with osteoporosis. *Osteoporos Int* 2005;16(5):447–55.
5. Fechtenbaum J, Cropet C, Kolta S. The severity of vertebral fractures and health-related quality of life in osteoporotic postmenopausal women. *Osteoporos Int* 2005;16(12):2175–9.
6. Kado DM, Browner WS, Palermo L. Vertebral fractures and mortality in older women: a prospective study. Study of Osteoporotic Fractures Research Group. *Arch Intern Med* 1999;159(11):1215–20.
7. Kado DM, Duong T, Stone KL. Incident vertebral fractures and mortality in older women: a prospective study. *Osteoporos Int* 2003;14(7):589–94.
8. Briggs AM, Greig AM, Wark JD. The vertebral fracture cascade in osteoporosis: a review of aetiopathogenesis. *Osteoporos Int* 2007;18(5):575–84.
9. Delmas PD, van de Langerijt L, Watts NB. Underdiagnosis of vertebral fractures is a worldwide problem: the IMPACT study. *J Bone Miner Res* 2005; 20(4):557–63.
10. Lenchik L, Rogers LF, Delmas PD. Diagnosis of osteoporotic vertebral fractures: importance of recognition and description by radiologists. *AJR Am J Roentgenol* 2004;183(4):949–58.
11. Grigoryan M, Guermazi A, Roemer FW. Recognizing and reporting osteoporotic vertebral fractures. *Eur Spine J* 2003;12(2):S104–12.
12. Cooper C, Atkinson EJ, O’Fallon WM. Incidence of clinically diagnosed vertebral fractures: a population-based study in Rochester, Minnesota, 1985–1989. *J Bone Miner Res* 1992;7(2):221–7.
13. Ferrar L, Jiang G, Armbrecht G, et al. Is short vertebral

- height always an osteoporotic fracture? The Osteoporosis and Ultrasound Study (OPUS). *Bone* 2007;41(1):5-12.
13. Grados F, Roux C, de Vernejoul MC. Comparison of four morphometric definitions and a semiquantitative consensus reading for assessing prevalent vertebral fractures. *Osteoporos Int* 2001; 12(9):716-22.
  14. Fu TS, Chen LH, Liao JC, Lai PL, Niu CC, Chen WJ. Magnetic Resonance Imaging Characteristics of Benign and Malignant Vertebral Fractures. *Chang Gung Med J* 2004; 27:808-15.
  15. Vaccaro AR, Shah SH, Schweitzer ME. MRI description of vertebral osteomyelitis, neoplasm, and compression fracture. *Orthopedics*.1999; 22:67-73.
  16. Pongpornsup S, Wajanawichakorn P, Danchaivijitr N. Benign Versus Malignant Compression Fracture: A Diagnostic Accuracy of Magnetic Resonance Imaging. *J Med Assoc Thai* 2009; 92 (1): 64-72
  17. An HS, Andreshak TG, Nguyen C, William A, Diniels D. Can we distinguish between benign versus malignant compression fractures of the spine by magnetic resonance imaging? *Spine* 1995; 20:1776-82.
  18. Abdel-Wanis ME, Solyman MT, Hasan NM. Sensitivity, specificity and accuracy of magnetic resonance imaging for differentiating vertebral compression fractures caused by malignancy, osteoporosis, and infections. *J Orthop Surg (Hong Kong)*. 2011 Aug;19(2):145-50.
  19. Jung HS, Jee WH, McCauley TR, Ha KY, Choi KH. Discrimination of metastatic from acute osteoporotic compression spinal fractures with MR imaging. *Radiographics* 2003; 23:179-87.
  20. Lolge S, Maheshwari M, Shah J, Patkar D, Chawla A. Isolated solitary vertebral body tuberculosis--study of seven cases. *Clin Radiol*. 2003 Jul; 58(7):545-50
  21. Tehranzadeh J, Tao C. Advances in MR imaging of vertebral collapse. *Semin Ultrasound CT MR* 2004; 25: 440-60
  22. Shih TT, Huang KM, Li YW. Solitary vertebral collapse: distinction between benign and malignant causes using MR patterns. *J Magn Reso Imaging*1999; 9:635-42
  23. Yuh WT, Zachar CK, Barloon TJ, Sato Y, Sickels WJ, Hawes DR. Vertebral compression fractures: distinction between benign and malignant causes with MR imaging. *Radiology* 1989; 172:215-8
  24. Mouloupoulos LA, Yoshimitsu K, Johnston DA, Leeds NE, Libshitz HI. MR prediction of benign and malignant vertebral compression fractures. *J Magn Reso Imaging* 1996; 6:667-74.
  25. Hsu CY, Yu CW, Wu MZ, Chen BB, Huang KM, Shih TT. Unusual manifestations of vertebral osteomyelitis: intraosseous lesions mimicking metastases. *AJNR Am J Neuroradiol*. 2008 Jun; 29(6):1104-10.
  26. Jee WH, Choe BY, Ha KY, Song HH, Choi KH, Shinn KS. Acute Benign versus Malignant Vertebral Compression Fractures: Distinction with Fast Spin-Echo and Gadolinium-enhanced MR Imaging. *Radiographics* 2003; 23:179-187.
  27. Shen BX, Zhou SK, Zhang KJ. MRI analysis of non-traumatic multiple vertebral collapse in aged people. *Hunan Yi Ke Da Xue Xue Bao*. 2001 Jun 28; 26(3):235-8.
  28. Chan JH, Peh WC, Tsui EY. Acute vertebral body compression fractures: discrimination between benign and malignant causes using apparent diffusion coefficients. *Br J Radiol* 2002; 75(891):207-14.
  29. Bhugaloo AA, Abdullah BJJ, Siow YS, Ng KH. Diffusion weighted MR imaging in acute vertebral compression fractures: differentiation between malignant and benign causes. *Biomed Imaging Interv J* 2006; 2(2):e12.
  30. Castillo M. Diffusion-Weighted Imaging of the Spine: Is It Reliable? *AJNR Am J Neuroradiol* June/July 2003; 24:1251-1253.
  31. Baker LL, Goodman SB, Perkas I, Lane B, Enzmann DR. Benign versus pathologic compression fractures of vertebral bodies: assessment with conventional spin-echo, chemical-shift, and STIR MR imaging. *Radiology* 1990; 174:495-502
  32. Rupp RE, Ebraheini NA, Coombs RJ. Magnetic resonance imaging differentiation of compression spinal fractures or vertebral lesions caused by osteoporosis or tumor. *Spine* 1995;20:2499-504.