

## Original Research Article

## ASSESSMENT OF ACCURACY OF ULTRASOUND IN THE DEEP MARGIN STATUS OF RESECTION OF TONGUE MALIGNANCY

Nagendra Parvataneni<sup>1</sup>, Kiran Kumar Devarakonda<sup>2</sup>, Ishfaq Ahmad Gilkar<sup>3</sup>, Ulhas Paga<sup>4</sup>, Amulya.C<sup>5</sup>, Susmitha P<sup>6</sup>, Mahesh Kumar Raju Chejerla<sup>7</sup>, Reshma Sree Gopiseti<sup>8</sup>, Seema M. gafurjiwala<sup>9</sup>

<sup>1</sup>Professor & HOD, Department of Surgical Oncology, Krishna Institute of Medical Sciences, Secunderabad, India.

<sup>2</sup>Senior Resident, Department of Surgical Oncology, Krishna Institute of Medical Sciences, Secunderabad, India.

<sup>3</sup>Senior Resident, Department of Surgical Oncology, Krishna Institute of Medical Sciences, Secunderabad, India.

<sup>4</sup>Consultant, Department of Surgical Oncology, Krishna Institute of Medical Sciences, Secunderabad, India.

<sup>5</sup>Consultant, Department of Surgical Oncology, Krishna Institute of Medical Sciences, Secunderabad, India.

<sup>6</sup>Head and Neck Fellow, Department of Surgical Oncology, Krishna Institute of Medical Sciences, Secunderabad, India.

<sup>7</sup>Resident, Department of Surgical Oncology, Krishna Institute of Medical Sciences, Secunderabad, India.

<sup>8</sup>Resident, Department of Surgical Oncology, Krishna Institute of Medical Sciences, Secunderabad, India.

<sup>9</sup>Statistician, Krishna Institute of Medical Sciences, Secunderabad, India.

Received : 10/02/2025

Received in revised form : 15/03/2025

Accepted : 01/04/2025

### Corresponding Author:

**Dr. Ishfaq Ahmad Gilkar,**

Senior Resident, Department of Surgical Oncology, Krishna Institute of Medical Sciences, Secunderabad, India.

Email: drishfaqahmadgilkar@gmail.com

DOI: 10.70034/ijmedph.2025.2.15

Source of Support: Nil,

Conflict of Interest: None declared

Int J Med Pub Health

2025; 15 (2); 77-82

### ABSTRACT

**Background:** Oral squamous cell carcinoma (OSCC) is the most common type of oral cavity malignancy, with the tongue being one of the most commonly affected sites. It can also cause dysphagia (difficulty swallowing), dysarthria (difficulty speaking), and paresthesia (numbness) of the tongue or mouth. The use of tobacco products, excessive alcohol consumption, HPV infection, a weak immune system, genetics, and oral irritation are the main factors that cause tongue cancer. Surgical excision with negative margins is the primary goal. Obtaining clear margin especially deep margin is difficult due to complex anatomy and poor assessment of spread of tumour.

**Aims and objectives:** The study aims to identify whether USG-guided assisted resection of primary tongue lesions will help in the resection of adequate margins when compared with final histopathology.

**Materials and Methods:** A total of 91 patients with diagnosed tongue malignancies were observed at Krishna Institute of Medical Sciences' surgical oncology department from 2020 to 2023, after obtaining written consent. Cases studied prospectively without randomization. A single pathologist reviewed the pathology specimen. The primary goal of this study is to delve into the potential impact of ultrasound-guided assistance during the resection of primary tongue lesions.

**Results:** A total of 91 patients were included in the study. Most of the patients in our study are in the T2 stage, 36/91 i.e., 39.5%. Deep margin as an outcome measure. The mean deep margin assessed by USG in our study was 0.901cm +/- 5.2 mm (mean +/- SD), and the mean deep margin assessed by the frozen section is 0.762 cm +/- 4.8 mm. Higher stage T3 and T4 were strong predictors for inadequate deep margin but they were assessed correctly by USG assessment and allowed us to revise the margins to prevent close and positive margins.

**Conclusion:** Ultrasound-guided surgery for tongue cancer resection is a technique that increases the chances of achieving clear margins and reduces the likelihood of positive margins compared to standard methods. Performing ex-vivo ultrasound on the resected specimen enables the assurance of extra clear margins. However, it's important to maintain consistent orientation of the specimen during both surgery and histopathological evaluation.

**Keywords:** Ultrasonography, tongue, squamous cell carcinoma.

## INTRODUCTION

Oral squamous cell carcinoma (OSCC) is the most common type of oral cavity malignancy, with the tongue being one of the most commonly affected sites. The squamous cell carcinoma presents as lesions, tumours, or patches on the tongue or in the oral cavity.<sup>[1]</sup> It can also cause dysphagia (difficulty swallowing), dysarthria (difficulty speaking), and paresthesia (numbness) of the tongue or mouth. The use of tobacco products, excessive alcohol consumption, HPV infection, a weak immune system, genetics, and oral irritation are the main factors that cause tongue cancer.<sup>[2]</sup> The stage and location of the tumour will determine the course of treatment for tongue cancer. Surgery is the main form of treatment for tongue cancers, with the goal of completely removing the tumour while maintaining both functional and aesthetically pleasing results.<sup>[3]</sup> The evaluation of the margin status is a crucial part of surgical excision because insufficient clearing of the tumour margins raises the likelihood of local recurrence and has a negative impact on the prognosis of the patient. Due to the complex anatomy of the oral cavity and the probable proximity of the tumour to important structures, obtaining a clear margin is particularly difficult in cases with tongue cancers.<sup>[4]</sup>

It is the 16th most prevalent cancer worldwide and affects men more often than women.<sup>[5]</sup> With an annual incidence rate of 4.0 per 100,000 people and a global mortality rate of 2.7 per 100,000, oral cancer is one of the most prevalent malignancies globally. According to the World Health Organisation, tongue cancer is expected to cause 177,384 new cases and 97,795 fatalities globally in 2020. South-East Asia, Eastern Europe, and South America have greater incidence and fatality rates than other regions.<sup>[6]</sup> The fourth most prevalent cancer in men and the seventh most common in women in India is tongue cancer. It is more prevalent in the central and northeastern states and accounts for about 30% of all oral cancers in the nation. In India, there are expected to be 60,669 instances of tongue cancer in men by the year 2020.<sup>[7]</sup> The stage of diagnosis determines the tongue cancer survival rate, which is typically low in low- and middle-income countries due to late discovery and insufficient therapy.<sup>[8]</sup>

During tongue cancer surgery in oncology, it is crucial to maintain a precise balance between removing tumours and preserving the healthy operation of surrounding tissue. A crucial element directly affecting patients' prognoses, recurrence rates, and overall treatment results, securing clear and accurate resection margins is at the heart of this surgical problem. The development of novel methods for improving surgical accuracy and margin assessment accuracy is of utmost importance in the oncological field.<sup>[9]</sup>

The use of ultrasonic imaging in this setting stands out as a viable option. Ultrasound has drawn attention for its potential to aid surgical decision-making since it provides real-time visualisation capabilities and a non-invasive method.<sup>[10]</sup> The main goal of this study is to contribute to better surgical results and patient care by exploring the use of ultrasound to evaluate the deep margin status during the excision of tongue cancers.

The primary goal of this study is to delve into the potential impact of ultrasound-guided assistance during the resection of primary tongue lesions. Specifically, the study seeks to ascertain whether such guidance facilitates the attainment of precise and adequate surgical margins in comparison to conventional techniques. This investigation hinges on the meticulous analysis of the concordance between ultrasound-guided resection margins and the ultimate histopathological assessment, thereby fostering a symbiotic relationship between intraoperative imaging and postoperative pathology. By examining the synergy between ultrasound imaging and surgical interventions, the study aims to uncover this innovative approach's inherent advantages and limitations. The results are anticipated to illuminate not only the technical aspects but also the broader implications for surgical protocols, thus potentially revolutionizing the management of tongue malignancies.<sup>[11]</sup> The integration of ultrasound imaging within the surgical workflow could usher in a new era of enhanced precision, bridging the gap between real-time visualization and critical postoperative pathological evaluation.<sup>[12]</sup>

The significance of this research transcends the confines of the operating theatre. Through a comprehensive evaluation of ultrasound's role in resection, the study aspires to offer insights that extend to optimizing patient care pathways and treatment strategies. The potential implications for clinical practice are profound, as refining surgical techniques and ensuring accurate margin assessment hold the promise of reducing recurrence rates, enhancing quality of life, and ultimately elevating patient outcomes.<sup>[13]</sup> By unravelling the multifaceted relationship between ultrasound guidance and the accurate assessment of resection margins, this study aspires to contribute to the burgeoning body of knowledge surrounding oncological surgery.<sup>[14]</sup> The findings may catalyze a paradigm shift in how surgical procedures are planned and executed, fostering an environment of innovation and excellence in patient care.

### Aims and objectives

The study aims to identify whether USG-guided assisted resection of primary tongue lesions will help in the resection of adequate margins when compared with final histopathology.

## MATERIALS AND METHODS

A total of 91 patients with diagnosed tongue malignancies were observed at Krishna Institute of Medical Sciences' surgical oncology department from 2020 to 2023, after obtaining written consent. The same surgeon treated all patients. Cases studied prospectively without randomization. A single pathologist reviewed the pathology specimen.

### Inclusion Criteria

Biopsy-verified tongue cancer

### Exclusion Criteria

- Former surgery in the oral cavity
- The floor of the mouth cancer is not available for ultrasound investigation
- The floor of the mouth cancer extends to the gingiva
- Patients not suitable for surgery
- T4 tumors according to the TNM stage 8th edition
- Age < 18
- Patients declining to participate.

## RESULTS

A total of 91 patients were analysed, including 63 men (69%) and 28 women (31%), as shown in Fig. 1, with a mean age of  $53.2 \pm 12.4$  years. Most patients were in the age group between 41-60 yrs (43 [47.2%]) followed by >60 yrs age group (31[34.1%]) as shown in Fig. 2.

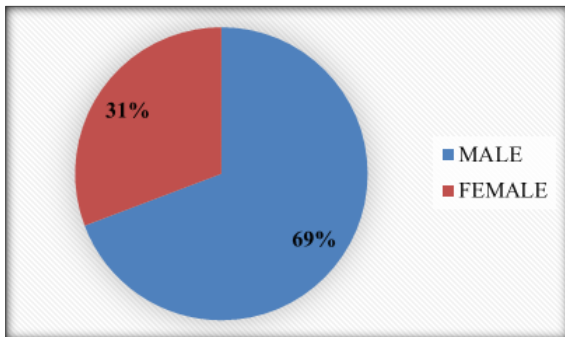


Figure 1: Gender-wise Distribution

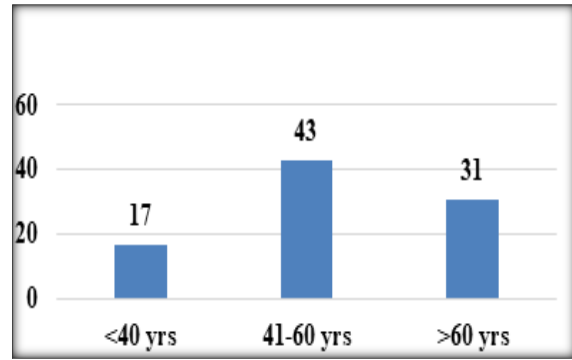


Figure 2: Age-wise distribution

In our study, carcinoma in the left and right lateral tongue had a greater impact on diagnosis. Patients with T1 disease numbered 29, with 36 in T2 and 26 in T3. T4 tumours were excluded as they caused reduced mouth opening and impeded USG examination, as shown in Figure 3.

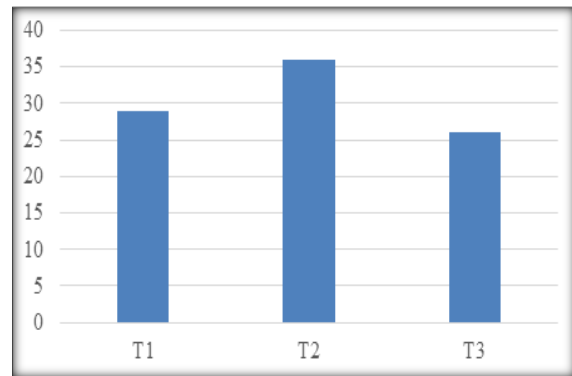


Figure 3: Showing Tumor Stage Distribution

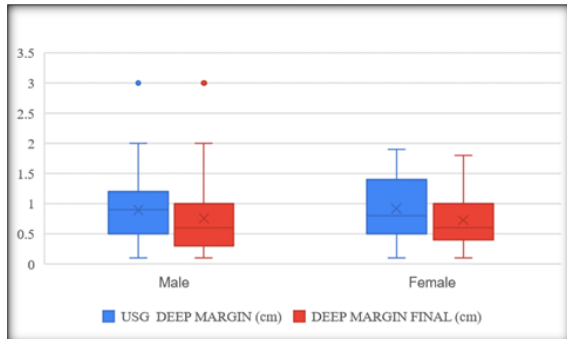
Data is collected and recorded on a proforma to assess margins. Deep margin assessment is the main objective, comparing USG values to the final histopathological examination. The data of the study showed a positive skew in USG assessment of deep margin components as shown in the Box-and-Whisker plot in Fig. 4. The mean deep margin from final histology is 0.748 cm, and statistical analysis is performed with results shown in Table 1.

Table 1: Summary stastics of Deep margin assessed by USG and Final HPE

		USG	Final HPE
N	Valid Samples	91	91
	Missing Values	0	0
Mean		0.9	0.7
Std.Deviation		0.522	0.5
Minimum		0.1	0.1
Maximum		3	3
Percentiles	25	0.5	0.4
	50	0.8	0.6
	75	1.3	1
Median (IQR)		0.8(0.5,1.3)	0.6(0.4,1)

**Table 2: Shows the correlation and p-value between USG deep margin and frozen and final deep margins**

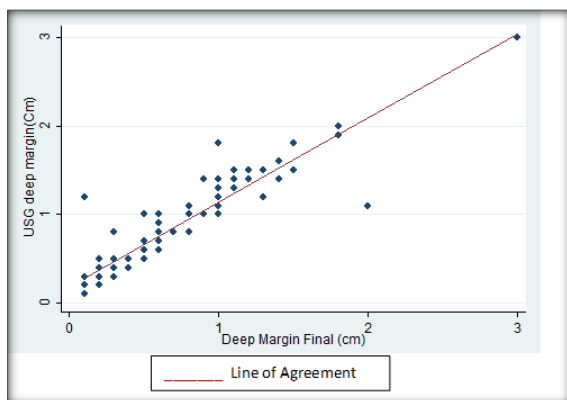
Paired Sample Statistics				
	N	Correlation	Significance	
			One-Sided P	Two-Sided P
USG Deep Margin (Cm) & Deep Margin Final(Cm)	91	0.91	<0.001	<0.001



**Figure 4:**

Table 2 shows the correlation and p-value between USG deep margin and frozen and final deep margins.

Correlation with one-sided and two-sided P-values has been derived as shown in Table 2. There is a statistically significant correlation between close margin status and a decrease in positive margin in USG assessment (p-value < 0.001). Scatter plots in Fig. 5 show a positive correlation of the USG deep margin assessment with the final HPE assessment, with a higher frequency of free margins in the USG assessment (R2=0.91).



**Figure 5: Scatter plot analysis of USG deep margin assessment as compared to final HPE assessment**

## DISCUSSION

For better recurrence-free, disease-free, and overall survival, a radical resection with good margins is necessary.<sup>[15]</sup> Currently, inadequate resection margins in oral tongue carcinoma range from 30% to 80%.<sup>[16]</sup> Resection margins with tumor cells less than 1mm are considered a positive margin, less than 5mm is considered a close margin and more than 5mm is considered a free margin.<sup>[17]</sup>

The most common margin that is usually close or positive is the deep margin.<sup>[17]</sup> Most of the patients with inadequate resections with close and positive margins require adjuvant therapy in the form of radiation and chemoradiation, which are associated with increased morbidity and decreased quality of life and additional increased financial burden.<sup>[18]</sup>

Margin assessment after tumor resection is critical and it's the only prognostic factor in the surgeon's hands and is very challenging. Many methods are followed from gross examination, palpation, frozen section, image-guided surgery like Ultrasound, spectroscopy, fluorescence imaging, and final histopathological examination.<sup>[19]</sup> The most ideal technique for guidance is that which provides a direct and quick response of the complete mucosal and deep margins with microscopic accuracy during resection. Kerwala et al showed an error of 12mm for the relocation of the sample site.<sup>[19]</sup> After resection, by the time the specimen reaches the pathologist, tissue is subjected to shrinkage, leading to close margins. So, an ideal technique to assess deep margins or mucosal margins should be easy, cheap, widely available, fast and should be done in the operating room. Fluorescence imaging and other optical techniques like Spectroscopy, hyperspectral imaging, optical coherence tomography, and narrowband imaging are costly and are in evolving stages and may be promising in the future.<sup>[19,20]</sup> In the literature, data on deep resection margin is scarce; previous studies have indicated that USG is a promising technique in assessing the deep margin which is fast and reliable when compared to conventional methods.<sup>[20]</sup> With this real-time USG guidance, surgeons can be reassured or alerted to modify their resection margins, which is critical for a small but highly functional organ like the tongue. So, in the present study, we tried to assess the deep margin post-tongue resection to avoid close and positive margins.

A total of 91 patients were included in the study which is a higher number when compared to the previous studies in the literature, B.C. Yoon et al in 2020 (N = 36), De Koning et al in 2020 (N = 31), and Olof Nilsson et al (N = 34). In the present study, we found that most of the patients were in the age group > 41 years of age. Similar findings were observed by Olof Nilsson et al, where the minimum and maximum age groups in USG-assisted surgery and the conventional group were 34-86 and 27-88 years, respectively. Most of the patients in our study are in the T2 stage, 36/91, i.e., 39.5%. As the Baek et al group, we used the mean deep margin as an outcome measure 0.901cm +/- 5.2 mm (mean +/- SD) as the outcome measure. The mean deep margin

assessed by USG in our study was 0.901cm $\pm$  5.2 mm (mean  $\pm$  SD) and the mean deep margin assessed by the frozen section is 0.762 cm  $\pm$  4.8 mm. Higher stage T3 and T4 were strong predictors for inadequate deep margin but they were assessed correctly by USG assessment and allowed us to revise the margins to prevent close and positive margins. On statistical analysis, a strong correlation was observed between USG guided resection mean deep margin and histopathological deep margin.

USG-guided surgery for early-stage carcinoma tongue is an accessible and inexpensive technique and provides a good overview of deep and submucosal margins. Moreover, pre-excisional USG for carcinoma tongue gives us an insight into the depth of invasion, tumor extent, and presence of lingual nodes without any adverse events. In this study, we have shown that USG has good accuracy in assessing the deep margin in carcinoma tongue patients, ensuring that it is a reliable method for surgical guidance. No substantial increase in operative time was observed in the study showing that USG assessment is a fast and reliable technique. We did not encounter any lingual nodes in our study, as it was a rare entity of around 2% with few case reports. Lingual nodes are an inconstant lymph node group that cannot be implied for every tongue cancer patient. Anatomically-obtained incidences of LLN range from 8.6% to 30.2%.<sup>[21]</sup>

Intraoperative USG has been shown to be useful in guiding tumor resection in various parts of the body, like Tongue and liver resection. Real-time sonography performed immediately before and during surgery surgeon can be reassured that the resection trajectory is adequate and optimal or can be altered to the need to modify the resection trajectory which is quick and reliable to balance the need for adequate tumor margins and preservation of the maximal amount of native tongue which is more important for normal function.

Although there is no long-term follow-up data about Quality of life and survival, we assume that the current results will lead to more favourable outcomes in preventing adjuvant Radiation and chemotherapy in turn minimizing the morbidity. This can be addressed in future well-planned study designs with a control group and by analysing the chance of avoiding radiation therapy and progression-free and overall survival. One of the limitations of USG is that its variability in image acquisition is operator dependent and should be performed without compression with a lot of transducer gel to avoid distortion and inaccurate measurements. There is no control group in this study. Although there are no long-term follow-up data in this study yet, we assume that the current results and achievement of clear margins in USG-guided resection will lead to favourable patient outcomes.

## CONCLUSION

Ultrasound-guided surgery for tongue cancer resection is a technique that increases the chances of achieving clear margins and reduces the likelihood of positive margins compared to standard methods. Performing ex vivo ultrasound on the resected specimen enables the evidence of extra clear margins. However, it's important to maintain consistent orientation of the specimen during both surgery and histopathological evaluation. The study's results suggest that this approach may enhance disease-specific survival and quality of life, however, more research is needed in this regard

## REFERENCES

1. Abati S, Bramati C, Bondi S, Lissoni A, Trimarchi M. Oral Cancer and Precancer: A Narrative Review on the Relevance of Early Diagnosis. *Int J Environ Res Public Health*. 2020 Dec 8;17(24):9160.
2. Johnson DE, Burtneess B, Leemans CR, Lui VWY, Bauman JE, Grandis JR. Head and neck squamous cell carcinoma. *Nat Rev Dis Primers*. 2020 Nov 26;6(1):92.
3. Al-Qahtani K, Rieger J, Harris JR, Mlynarek A, Williams D, Islam T, et al. Treatment of base of tongue cancer, stage III and stage IV with primary surgery: survival and functional outcomes. *European Archives of Oto-Rhino-Laryngology*. 2015 Aug 25;272(8):2027–33.
4. Wong T, Wiesenfeld D. Oral Cancer. *Aust Dent J*. 2018 Mar;63: S91–9.
5. Miranda-Filho A, Bray F. Global patterns and trends in cancers of the lip, tongue and mouth. *Oral Oncol*. 2020 Mar; 102:104551.
6. Mathur P, Sathishkumar K, Chaturvedi M, Das P, Sudarshan KL, Santhappan S, et al. Cancer Statistics, 2020: Report from National Cancer Registry Programme, India. *JCO Glob Oncol*. 2020 Jul; 6:1063–75.
7. Coelho KR. Challenges of the oral cancer burden in India. *J Cancer Epidemiol*. 2012; 2012:701932.
8. Tagliabue M, De Berardinis R, Belloni P, Gandini S, Scaglione D, Maffini F, et al. Oral tongue carcinoma: prognostic changes according to the updated 2020 version of the AJCC/UICC TNM staging system. *Acta Otorhinolaryngol Ital*. 2022 Apr;42(2):140–9.
9. De Berardinis R, Tagliabue M, Belloni P, Gandini S, Scaglione D, Maffini F, et al. Tongue cancer treatment and oncological outcomes: The role of glossectomy classification. *Surg Oncol*. 2022 Jun; 42:101751.
10. Wang X, Yang M. The Application of Ultrasound Image in Cancer Diagnosis. *J Healthc Eng*. 2021; 2021:8619251.
11. Tan A, Rajakulasingam R, Saifuddin A. Diagnostic concordance between ultrasound-guided core needle biopsy and surgical resection specimens for histological grading of extremity and trunk soft tissue sarcoma. *Skeletal Radiol*. 2021 Jan 8;50(1):43–50.
12. Tarabichi O, Kanumuri V, Juliano AF, Faquin WC, Cunnane ME, Varvares MA. Intraoperative Ultrasound in Oral Tongue Cancer Resection: Feasibility Study and Early Outcomes. *Otolaryngol Head Neck Surg*. 2018 Apr;158(4):645–8.
13. Noorlag R, Klein Nulent TJW, Delwel VEJ, Pameijer FA, Willems SM, de Bree R, et al. Assessment of tumour depth in early tongue cancer: Accuracy of MRI and intraoral ultrasound. *Oral Oncol*. 2020 Nov; 110:104895.
14. Noorlag R, Klein Nulent TJW, Delwel VEJ, Pameijer FA, Willems SM, de Bree R, et al. Assessment of tumour depth in early tongue cancer: Accuracy of MRI and intraoral ultrasound. *Oral Oncol*. 2020 Nov; 110:104895.
15. Jain P V., Sharan R, Manikantan K, Clark GM, Chatterjee S, Mallick I, et al. Redefining adequate margins in oral squamous cell carcinoma: outcomes from close and positive

- margins. *European Archives of Oto-Rhino-Laryngology*. 2020 Apr 2;277(4):1155–65.
16. Smits RWH, Koljenović S, Hardillo JA, ten Hove I, Meeuwis CA, Sewnaik A, et al. Resection margins in oral cancer surgery: Room for improvement. *Head Neck*. 2016 Apr;38(S1):E2197–203.
  17. Sutton DN, Brown JS, Rogers SN, Vaughan ED, Woolgar JA. The prognostic implications of the surgical margin in oral squamous cell carcinoma. *Int J Oral Maxillofac Surg*. 2003 Feb;32(1):30–4.
  18. Jehn P, Stier R, Tavassol F, Dittmann J, Zimmerer R, Gellrich NC, et al. Physical and Psychological Impairments Associated with Mucositis after Oral Cancer Treatment and Their Impact on Quality of Life. *Oncol Res Treat*. 2019;42(6):342–9.
  19. Brouwer de Koning SG, Schaeffers AWMA, Schats W, van den Brekel MWM, Ruers TJM, Karakullukcu MB. Assessment of the deep resection margin during oral cancer surgery: A systematic review. *European Journal of Surgical Oncology*. 2021 Sep;47(9):2220–32.
  20. Nilsson O, Knutsson J, Landström FJ, Magnuson A, von Beckerath M. Ultrasound-assisted resection of oral tongue cancer. *Acta Otolaryngol*. 2022 Dec 2;142(9–12):743–8.
  21. Nishio N, Fujimoto Y, Hiramatsu M, Yamamoto Y, Sone M. Sonographic detection of a lingual node metastasis from early squamous cell cancer of the tongue. *Journal of Clinical Ultrasound*. 2018 Jan;46(1):69–72.