

## Original Research Article

# ROLE OF MRI IN DIAGNOSIS OF KNEE INJURIES: AN OBSERVATIONAL STUDY

Nishi Choudhary<sup>1</sup>, Amlendu Nagar<sup>2</sup>, Sheetal Singh<sup>3</sup>, Bhushita Lakhar Guru<sup>4</sup>

<sup>1</sup>Junior Resident, Department of Radiology, Index Medical College Hospital and Research Centre, Indore, India.

<sup>2</sup>Professor & HOD, Department of Radiology, Index Medical College Hospital and Research Centre, Indore, India.

<sup>3</sup>Professor, Department of Radiology, Index Medical College Hospital and Research Centre, Indore, India.

<sup>4</sup>Professor, Department of Radiology, Index Medical College Hospital and Research Centre, Indore, India.

Received : 01/11/2024  
Received in revised form : 14/12/2024  
Accepted : 31/12/2024

### Corresponding Author:

**Dr. Nishi Choudhary,**  
Junior Resident, Department of  
Radiology, Index Medical College  
Hospital and Research Centre, Indore,  
India.  
Email: nishi.studios@gmail.com

DOI: 10.70034/ijmedph.2025.1.8

Source of Support: Nil,  
Conflict of Interest: None declared

Int J Med Pub Health  
2025; 15 (1); 43-48

### ABSTRACT

**Background:** Knee injuries are a common clinical concern, particularly in active and young individuals. Magnetic Resonance Imaging (MRI) has emerged as a valuable, non-invasive diagnostic modality for detecting soft tissue injuries in the knee joint, complementing and sometimes substituting for diagnostic arthroscopy, the gold standard. This study aims to assess the burden of knee injuries and determine the prevalence of specific soft tissue injuries using MRI. **Material and Methods:** This observational study included 100 patients with recent knee joint trauma presenting to a tertiary healthcare center. MRI findings were analyzed to identify and quantify ligament, meniscal, and other soft tissue injuries. Descriptive statistics were used to summarize the findings.

**Results:** Among the 100 patients, males predominated (76%) with a male-to-female ratio of 2.6:1. The most common age group affected was 21-30 years (32%). Right knee injuries (56%) were more common than left knee injuries (44%). Anterior cruciate ligament (ACL) tears were the most frequently observed injury (64%), followed by medial meniscus tears (32%), medial collateral ligament injuries (25%), and medial patellofemoral ligament injuries (20%). Posterior cruciate ligament (PCL) injuries were less common (9%), with PCL avulsion being the predominant subtype. These findings are consistent with previous studies, including those by Radhakrishnan et al. and Chowdhary et al., which reported similar trends.

**Conclusion:** MRI plays a pivotal role in diagnosing knee joint injuries, providing accurate visualization of ligament and meniscal tears, particularly ACL injuries, which were the most prevalent in this study. The findings reaffirm MRI as an indispensable diagnostic tool for knee trauma management, enabling precise treatment planning and minimizing unnecessary surgical interventions. However, further large-scale, multi-center studies are warranted to enhance the generalizability of the results.

**Key Words:** Knee injuries, MRI, ACL tear, PCL injury, meniscal injuries, soft tissue trauma.

## INTRODUCTION

Knee injuries are a common clinical concern, particularly among athletes and physically active individuals, often resulting from trauma, sports, or accidents.<sup>[1,2]</sup> Knee injuries represent roughly 6% of all acute injuries treated at Emergency Department and between 27% and 48% of these have been reported to be sports-related.<sup>[3]</sup>

Accurate diagnosis is essential for appropriate management, as untreated or misdiagnosed injuries

can lead to chronic pain, functional impairment, or long-term disability. Magnetic Resonance Imaging (MRI) has emerged as the gold standard for evaluating internal derangements of the knee joint due to its non-invasive nature and ability to provide detailed soft tissue imaging.<sup>[2]</sup>

The knee joint, being a complex structure comprising ligaments, menisci, cartilage, and tendons, is prone to injuries such as anterior cruciate ligament (ACL) tears, posterior cruciate ligament (PCL) tears, medial meniscus (MM) and lateral meniscus (LM) injuries,

and other associated conditions.<sup>[4-6]</sup> Radiological imaging modalities like X-rays and computed tomography (CT) have limited capacity in detecting soft tissue injuries, whereas MRI provides superior contrast resolution for the accurate visualization of these structures.<sup>[2]</sup>

Studies have demonstrated high diagnostic accuracy of MRI in assessing knee injuries. For instance, MRI has a reported sensitivity of 94-98% and specificity of 80-100% for detecting ACL tears, as validated by arthroscopy, the gold standard for knee joint evaluation.<sup>[7,8]</sup> Fast spin echo (FSE) and fat suppression MRI techniques have extended the sensitivity and specificity of MRI in detection of meniscal and cruciate ligament injuries.<sup>[9]</sup> Meniscal tears, while more challenging to diagnose, exhibit MRI sensitivity and specificity ranging from 68-86% depending on the study, patient population, and imaging protocols.<sup>[10]</sup>

The role of MRI extends beyond diagnosis, aiding in preoperative planning and the monitoring of postoperative recovery. Its ability to differentiate between partial and complete ligament tears or subtle meniscal injuries makes it indispensable in clinical decision-making, particularly in athletes requiring expedited rehabilitation. Despite its advantages, MRI may occasionally show false positives due to imaging artifacts, suboptimal imaging planes, or partial volume averaging effects.

Therefore, this observational study aims to evaluate the role of MRI in diagnosing various knee injuries by comparing MRI findings with arthroscopic results, providing insights into its diagnostic accuracy, reliability, and clinical utility.

## **MATERIALS AND METHODS**

After approval from the institutional ethics committee, this observational cross-sectional study was carried out in the Department of Radiodiagnosis at Index Medical College Hospital and Research Centre, Indore. The study included 50 patients of all age groups irrespective of gender, who presented with knee injury referred from OPD (outpatient department) and IPD (inpatient department) for MRI imaging the period of study. A written informed consent was obtained from all patients after explaining the study protocol and enrolment was done.

### **Inclusion Criteria**

- Patients of all age group, either male or female, referred from OPD or IPD with recent history of traumatic knee joint injury within 7 days duration, were included in the study.

### **Exclusion Criteria**

- Patients who did not give their consent for the study;
- Patients who had past history of knee joint operation or any procedure related to knee joint; and

- Patients who had any chronic knee joint pathology; and
- Patients with cardiac pacemaker, metallic implants in the body and those with history of claustrophobia or any contraindication to MRI were excluded.

### **Methodology**

Patient findings were systematically documented using a structured proforma. MRI scans were conducted using a 1.5 Tesla magnet (GE Company) with dedicated knee coil systems. T1-weighted (T1WI) and T2-weighted (T2WI) pulse sequences were primarily employed. To optimize imaging, patients were positioned supine with the knee placed in an HD transmit/receive knee array coil. The knee was externally rotated approximately 15–20° to ensure comprehensive visualization of the anterior cruciate ligament (ACL) on sagittal images.

Initial axial acquisitions across the patellofemoral joint served as localizers for obtaining subsequent sagittal and coronal plane images. Imaging was performed in three standard planes—sagittal, axial, and coronal—with the following parameters: field of view (FOV) 16 × 16 cm, matrix size 320 × 224, and slice thickness of 3 mm. The imaging protocol included T1-weighted, T2-weighted, fat-suppressed proton density (PD) sequences in sagittal planes, along with short tau inversion recovery (STIR), gradient-recalled echo (GRE), and 3D proton density cube sequences across multiple planes for comprehensive evaluation.

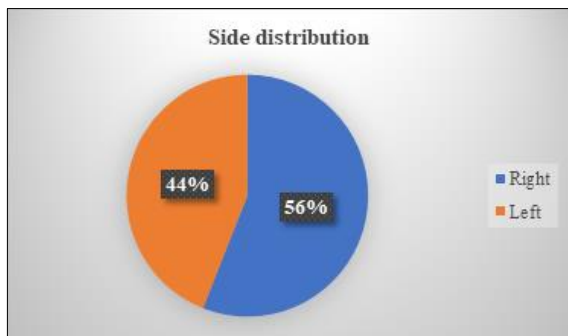
This protocol ensured optimal image quality for detecting ligamentous, meniscal, and soft tissue injuries while minimizing patient discomfort during the procedure.

### **Statistical Analysis**

The data were organized and recorded in Microsoft Excel 10.0 for initial management and storage. Statistical analysis was performed using IBM SPSS version 22.0. A master chart was created to compile all relevant findings, which were interpreted and presented using various graphical and tabular methods, such as tables, columns, bar charts, pie charts, and line diagrams. Microsoft Word was used to generate these visual representations for clarity. Categorical data were analyzed and expressed as rates, ratios, proportions, and percentages, enabling effective comparison and interpretation of key variables.

## **RESULTS**

In this study, a total of 100 patients were assessed using MRI to evaluate knee joint injuries. The sample included 72% males and 28% females, yielding a male-to-female ratio of 2.6:1. The age distribution of the participants is detailed in [Table 1]. Regarding the affected knee, 56% of the patients exhibited right knee joint trauma, while 44% had trauma in the left knee joint, as illustrated in. [Graph 1]



**Graph 1: Side based distribution of study participants**

Among the soft tissue injuries, the anterior cruciate ligament (ACL) tear was the most frequently observed, affecting 33 patients (66%). The second most common injury identified was meniscal damage, which was seen in 24 patients (48%). [Table 2]

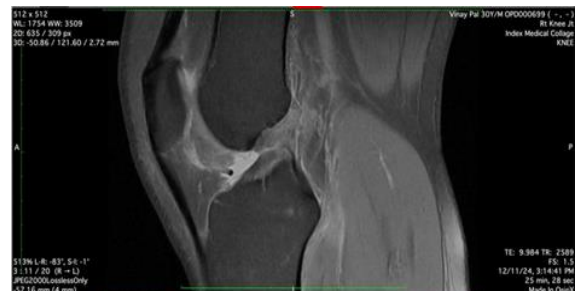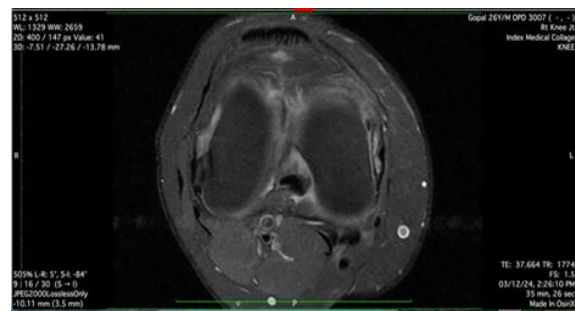
Among patients with ACL tears (n = 33, 66%), the majority were diagnosed with a complete or grade 3 tear, which was observed in 22 patients (66.7%). This was followed by partial or grade 2 tears and cases of avulsion fractures at the tibial attachment, each noted in 5 patients (15.1%) as summarized in. [Table 3]

Among patients with PCL tears (n = 5, 10%), the majority presented with PCL avulsion fractures, observed in 2 patients (40%). It was noted that PCL tears were less common overall compared to ACL tears in this study. [Table 4]

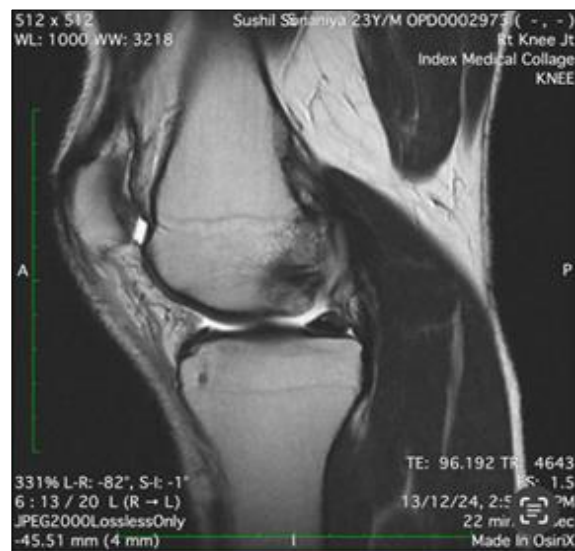In this study, meniscal injury was observed as the second most common soft tissue injury in knee joint trauma, with 24 patients (48%) showing some form of meniscal injury. Among these, the medial meniscus was the most frequently affected, observed in 16 patients (32%). In contrast, lateral meniscus tears were less common, found in only 8 patients (16%). [Table 5]

In our study, patella-related injuries were found in 7 patients (14%), which included patellar subluxation or dislocation in 4% of the cases. Additionally, patellar articular cartilage injuries were identified, which were classified according to the modified Outerbridge grading system for chondromalacia patellae. [Table 6]

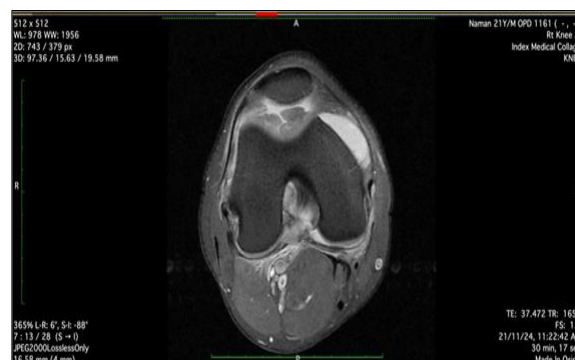
In this study, bone fractures were observed in several patients, with the lateral tibial condyle fracture being the most common, accounting for 14% of the total cases. The distribution of fractures in the knee joint, in decreasing order of frequency, is as follows: lateral tibial condyle fracture (14%), lateral femoral condyle fracture (6%), medial tibial condyle fracture (4%), head of fibula fracture (4%), intercondylar tibial notch fracture (1%), and comminuted tibial condyle fracture (1%). In addition to these fractures, bony contusion edema was observed in the affected areas, manifesting as discrete or confluent patches of T2/FS high signal intensity lesions on MRI. The extent and location of the bone contusion edema varied between patients, depending on the site of injury. [Table 7]



**Figure 1: Sag pd fat sat, axial pd fat sat showing ACL complete tear**



**Figure 2: Sag T2 showing hyperintensity in posterior horn of medial meniscus**



**Figure 3: Axial pd fat sat showing joint effusion**

**Table 1: Age based distribution of study participants**

Age Group	No of Patients (Male)	No of Patients (Female)	Total (%)
≤10	0	0	0 (0%)
11-20	4	2	6 (12%)
21-30	11	5	16 (32%)
31-40	10	4	14 (28%)
41-50	6	3	9 (18%)
51-60	3	0	3 (6%)
>60	2	0	2 (4%)
<b>Total</b>	<b>36</b>	<b>14</b>	<b>50 (100%)</b>

**Table 2: Distribution of patients according to structural injury on MRI**

Structural injury on MRI	No of Patients (%)
ACL	33 (66%)
PCL	5 (10%)
MCL	12 (24%)
LCL	7 (14%)
MM	16 (32%)
LM	8 (16%)
MPR and medial PFL	10 (20%)
LPR and lateral PFL	3 (6%)
Bone fracture with contusion	14 (28%)
Bone contusion only	11 (22%)
Patellar injury	7 (14%)
Joint effusion only	39 (78%)
Joint effusion with lipohaemarthrosis	6 (12%)

**Table 3: Distribution of patients according to MRI finding of ACL involvement**

MRI Finding of ACL involvement	No of Patients (%) N=33
Complete or grade III ACL tear	22 (66.7%)
• Near femoral attachment	9 (27.3%)
• Mid fiber tear	13 (39.4%)
Near tibial attachment	0 (0%)
Partial or grade II ACL tear -surface fiber	4 (12.1%)
Grade I ACL tear -interstitial fiber	2 (6.1%)
Avulsion fracture -tibial attachment	5 (15.1%)

**Table 4: Distribution of patients according to MRI finding of PCL involvement**

MRI Finding of PCL involvement	No of Patients (%) N=5
Interstitial tear/sprain or Grade-I PCL injury	1
Partial surface tear or Grade-II PCL injury	1
Complete PCL tear or Grade-III PCL injury	1
	Proximal fiber
	Middle fiber
	Distal fiber
Grade-IV PCL injury	0
PCL avulsion fracture	2
	Tibial attachment
	Femoral attachment

**Table 5: Distribution of patients according to various grades of Meniscal tear**

Grading	MM	LM	Total
Grade I	4	0	4 (16.7%)
Grade II	2	1	3 (12.5%)
Grade III	10	7	17 (70.8%)
<b>Total</b>	<b>16</b>	<b>8</b>	<b>24 (100%)</b>

**Table 6: Distribution of patients according to MRI finding of Patellar injury**

Patellar injury	No of Patients (%) N=7
Lateral Subluxation	2 (28.6%)
Patellar cartilage tear / Chondromalacia patella	3 (42.8%)
	Grade I
	Grade II
	Grade III
	Grade IV
<b>Total</b>	<b>7 (100%)</b>

**Table 7: Bone fracture distributions according to bony involvement**

Bony involvement	Lateral condyle	Medial condyle	Other	Total
Tibia	7	2	Notch-1 Comu. #1	11
Femur	3	0		3
Fibular head	2			2

## DISCUSSION

Magnetic Resonance Imaging (MRI) has emerged as a reliable diagnostic tool for musculoskeletal disorders, particularly knee joint injuries. The knee is highly prone to trauma caused by accidents, sports injuries, falls, and twisting movements. MRI is effective for identifying soft tissue injuries such as damage to ligaments, menisci, tendons, and articular cartilage. Being a non-invasive technique, MRI can guide appropriate treatment while reducing the need for unnecessary arthroscopy, thereby avoiding potential complications. However, arthroscopy is still regarded as the "gold standard" for diagnosing intra-articular knee injuries.<sup>[2]</sup>

In this study, 100 patients with a history of recent knee joint trauma were included. The majority of participants were males (76%), resulting in a male-to-female ratio of 2.6:1. The 21-30 years age group was the most frequently affected, accounting for 32% of cases for both males and females. Similar trends have been observed in previous studies. For instance, Radhakrishnan A et al,<sup>[11]</sup> conducted a study at Shri Sathya Sai Medical College and Research Institute, Tamil Nadu, in 2019, where 70% of the participants were males, and the most common age group was 31-40 years. Comparable results were also reported by Chowdhary AS et al,<sup>[12]</sup> in a 2018 study on MRI evaluation of internal knee derangements and by Chaudhari NHS et al,<sup>[13]</sup> in a 2017 study on MR imaging of ACL injuries. Additionally, Yadav K et al,<sup>[2]</sup> found that 78% of participants with knee injuries were males, with the 21-30 years age group comprising 33% of cases.

In this study, among the 100 patients examined, 56% presented with right knee joint trauma, while 44% had left knee joint trauma. These results align with findings reported by Chowdhary AS et al,<sup>[12]</sup> and Yadav K et al,<sup>[2]</sup> who observed similar patterns in knee injuries.

The most frequently injured soft tissue was the anterior cruciate ligament (ACL), which was affected in 33 (66%) of patients. Collateral ligament injuries were the next most common, seen in 19 (38%) of cases. Other injuries included medial meniscus (MM) tears 16 (32%), medial collateral ligament (MCL) injuries 12(24%), medial patellofemoral or medial patellar retinaculum tears 10(20%), lateral meniscus tears 8 (16%), lateral collateral ligament (LCL) injuries 7 (14%), posterior cruciate ligament (PCL) tears 5 (10%), and lateral patellofemoral ligament injuries 3 (6%). These findings are consistent with multiple previous studies. Umap R et al,<sup>[14]</sup> reported ACL injuries as the most prevalent, occurring in 76% of patients, followed by medial meniscus tears at 38%. Similarly, Gupta K et al,<sup>[8]</sup> observed ACL

injuries in 72% of cases, with medial meniscus tears in 36%. Chowdhary AS et al,<sup>[12]</sup> also highlighted ACL tears as the most frequent injury, accounting for 83.3% of cases, followed by medial meniscus tears (53.6%) and collateral ligament injuries (28.7%). Additionally, Radhakrishnan A et al,<sup>[11]</sup> noted that ACL injuries were the most common, reported in 62% of their study participants. These consistent observations reinforce the prevalence of ACL injuries as a primary concern in knee joint trauma cases.

Posterior cruciate ligament (PCL) injuries were less common in this study, observed in 10% of cases. The most frequent type of PCL injury was PCL avulsion with a chip fracture at the tibial attachment site, accompanied by proximal migration. Comparable results were reported by Umap R et al,<sup>[14]</sup> who found PCL injuries in 15% of cases, with mid-substance and avulsion tears being the most common types, accounting for 33.33% of complete PCL tears. Similarly, Radhakrishnan A et al,<sup>[11]</sup> reported a lower incidence of PCL tears, noted in only 2% of cases, whereas Chowdhary AS et al,<sup>[12]</sup> identified PCL tears in 14.8% of their study participants.

The study's limitations include its relatively small sample size of 100 patients, which may limit the statistical significance and generalizability of the findings. Additionally, inter-observer variability in the interpretation of MRI imaging results could introduce bias, and the single-center nature of the study restricts its applicability to broader populations.

## CONCLUSION

Knee joint injury is common in patients presenting with history of road traffic accident, outdoor sports players, twisting of knee and fall on ground. For the diagnosis of soft tissue injury in patients of traumatic knee trauma, clinical examination along with radiographs, CT scan and ultrasound is not enough to diagnose soft tissue injury. Arthroscopy is considered as the gold standard for diagnosis of traumatic intra-articular knee lesions, but it also has limitations due to invasiveness and complications associated with surgical procedure.

From this study, it can be concluded that MRI is safe, non-invasive, radiation free diagnostic imaging modality to evaluate soft tissue injury associated with the knee joint trauma. It can clearly and accurately delineate injury of the soft tissues like ligaments, cartilage, tendon, and menisci, associated with knee joint trauma. It reduces unnecessary surgical, aesthetic and arthroscopic interventions as well as expenditure. Magnetic Resonance Imaging is a multiplanar imaging technique with excellent soft

tissue contrast resolution and high efficacy and can be considered as best way to rapidly evaluate traumatic knee joint injuries.

## REFERENCES

1. Pawal S, Badhe PV, Arkar R, Varrior R et al. Role of MRI in knee joint injuries in Correlation with arthroscopy. *Int J Acad Med Pharm* 2023; 5(3); 2125-2130.
2. Yadav K, Patidar A, Sharma R, Dave PK. Role of MRI in evaluation of knee joint trauma - an observational crosssectional study. *Int J Acad Med Pharm* 2022; 4 (5); 842-846
3. Sowmya V, Seetha Pramila V.V. Role of MRI in the Diagnosis of Meniscal and Ligament Injuries of Knee Joint: A Retrospective Study. *International Journal of Contemporary Medicine Surgery and Radiology*. 2019;4(4): D103-D106.
4. Prakash P, Shrishail A, Pramod S, Amol B, Snehil K. A Cross Sectional Study to Evaluate Role of Magnetic Resonance Imaging in Ligaments Injuries of Knee Joint in a Tertiary Healthcare Institute; *International Journal of Contemporary Medical Research*; Volume-5, Issue -8, August 2018;111-114.
5. Bagale, NavidShattari; Evaluation of Traumatic Knee Joint Injuries with MRI; *International Journal of Contemporary Medicine Surgery and Radiology*; Volume 3, Issue 3, July-September 2018;77-81. DOI: 10.21276/ijcmsr.2018.3.3.17
6. SanchesVaz CE, Pires De Camargo O, Jose De Santana P, Valezi AC; Accuracy of magnetic resonance in identifying traumatic intraarticular knee lesions; *Clinics*; 2005; 60 (6); 445-450.
7. T Sundara Rajan, A Jamal Mohamed; Evaluation of Role of Magnetic Resonance Imaging in Knee Joint Injuries in Correlation with Arthroscopy; *International Journal of Scientific Study*; Volume 5, issue 6;1-6. DOI: 10.17354/ijss/2017/442
8. De Smet AA, Tuite MJ, Norris MA, Swan JS; MR diagnosis of meniscal tears; Analysis of causes of errors; *Am J Roentgenol* 1994; 163:1419-23.
9. Gupta K, Sandhu P, Galhotra R, Guleria M; Correlation of clinical, MRI and arthroscopic findings in diagnosing meniscus and ligament injuries at knee joint: A prospective study; *Journal of Orthop Allied Sci {Internet}*2013; 1 (1) :2
10. Madurwar AU, Ramya M, Kumar S et al. Evaluation of role of MRI in knee joint injuries in correlation with arthroscopy. *International Journal of Research and Review*. 2017; 4(7):40-46.
11. Arjun Radhakrishnan, I. Gurubharath. A study on MRI of internal derangements of knee. *IAIM*, 2019; 6(6): 32-35.
12. Chowdhary AS, Soki N, Kumar RD, et al. MRI evaluation of internal derangement of knee. *J. Evid. Based Med. Healthc*. 2018; 5(4), 296-302.
13. Chaudhari NH, Bagga RR, Patni ZM. MR imaging of anterior cruciate ligament injuries. *Int J Res Med Sci* 2017; 5:4980-7
14. Umap R, Anurag B, Bagale S, Shattari N. Evaluation of traumatic knee joint injuries with MRI. *International Journal of Contemporary Medicine Surgery and Radiology*. 2018;3(3):C77-C81.