



## Original Research Article

# A PROSPECTIVE EVALUATION OF CLINICAL PROFILE OF PATIENTS WITH PALMOPLANTAR DERMATOSES AT A TERTIARY CARE HOSPITAL

Preeti Ishwar Sitlani<sup>1</sup>, Som Jitendra Lakhani<sup>2</sup>, Krunal Bhartkumar Tralsawala<sup>3</sup>, Ajay Ninama<sup>4</sup>

<sup>1</sup>PG Resident, Department of Dermatology, Parul Institute of Medical Sciences and Research, Vadodara, Gujarat, India.

<sup>2</sup>Professor and HOD, Department of Dermatology, Parul Institute of Medical Sciences and Research, Vadodara, Gujarat, India.

<sup>3</sup>Professor, Department of Dermatology, Parul Institute of Medical Sciences and Research, Vadodara, Gujarat, India.

<sup>4</sup>PG Resident, Department of Dermatology, Medical College Baroda & SSGH Hospital, Vadodara, Gujarat, India.

Received : 15/10/2024  
Received in revised form : 06/11/2024  
Accepted : 27/11/2024

### Corresponding Author:

Dr. Ajay Ninama,  
PG Resident, Department of  
Dermatology, Medical College Baroda  
& SSGH Hospital, Vadodara, Gujarat,  
India.  
Email: ajaydninama50@gmail.com

DOI: 10.70034/ijmedph.2025.1.169

Source of Support: Nil,  
Conflict of Interest: None declared

Int J Med Pub Health  
2025; 15 (1); 906-909

### ABSTRACT

**Background:** Dermatoses affecting the palms and soles often occur in conjunction with other skin regions, encompassing a wide range of conditions. These include hyperhidrosis, keratinizing disorders, eczema, and infections caused by viral, fungal, or bacterial pathogens. Additionally, drug reactions and various other conditions can also manifest in this manner, highlighting the complexity and diversity of palmoplantar dermatoses.

**Materials and Methods:** The study comprised of 100 subjects with palmoplantar dermatoses. The procedure of the study had been explained to all the subjects and they were asked to give written consent. The clinical profile of all the subjects had been evaluated and the findings were tabulated. Statistical analysis was conducted using SPSS software.

**Results:** A study of 100 subjects with skin conditions found itching to be the primary complaint, accompanied by varying durations and treatments. The study also reported the prevalence of conditions like psoriasis, eczema, and infections.

**Conclusion:** In this study, the clinical profile of the subjects of palmoplantar dermatoses included pain, redness, irritation, peeling of skin, oedema, burning sensation and itching. The aggravation factors for this condition in the subjects of this study were seasonal variations, trauma, drugs and allergens.

**Keywords:** Palmoplantar Dermatoses, Psoriasis, Eczema, Infections.

## INTRODUCTION

Palms and soles are the readily visible areas of the body that are affected in various dermatoses. This may have considerable concern to the patient and can cause diagnostic dilemma at times. Moreover, palmoplantar dermatoses also limit our day to day activities, and thereby have a significant impact on the quality of life. Previous studies have focused on some specific palmoplantar dermatoses,<sup>1,2</sup> and none has performed a comprehensive study on dermatoses involving both the palms and soles. Palmoplantar dermatoses encompass a variety of skin disorders that specifically affect the palms and soles.

In contrast, dermatoses that involve these areas in conjunction with other regions of the body include a diverse array of conditions, such as hyperhidrosis,

keratinizing disorders, pigmentary disorders, eczema, and infections caused by viral, fungal, or bacterial agents, as well as drug reactions, among others. While many dermatological conditions are not life-threatening, they can significantly diminish a patient's quality of life due to the disfiguring effects of skin pathology. This can adversely affect body image and social functioning, often irrespective of the clinical severity of the condition, including those that specifically target the palms and soles.<sup>3-5</sup> This present prospective study conducted to evaluate clinical profile of patients with palmoplantar dermatoses.

## MATERIALS AND METHODS

This study was conducted on a sample of 100 subjects diagnosed with palmoplantar dermatoses, a

group of skin conditions affecting the palms of the hands and soles of the feet. To ensure transparency and adherence to ethical standards, the research procedure was thoroughly explained to each participant. Following this, written informed consent was obtained from all subjects, confirming their voluntary participation in the study.

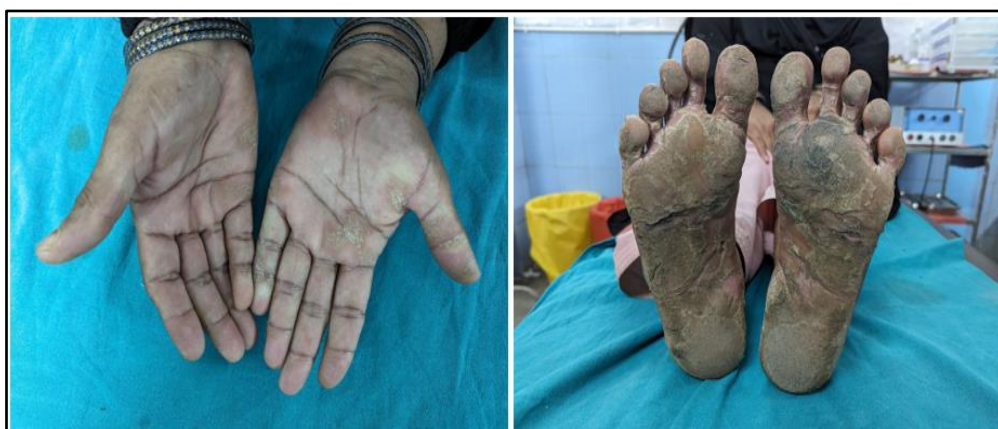A comprehensive clinical evaluation was performed on each subject to gather detailed information about their condition. This included a thorough examination of the affected skin areas, as well as a review of their medical history. The findings from these evaluations were systematically tabulated to facilitate data analysis.

To identify patterns, trends, and correlations within the data, statistical analysis was conducted using the Statistical Package for the Social Sciences (SPSS) software.

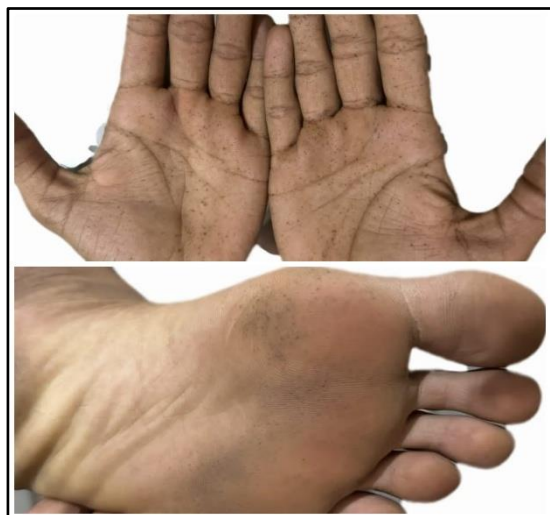## RESULTS

Itching was the chief complaint of 55 subjects. Redness and pain were observed in 16 and 12 subjects, respectively. Peeling of the skin was evident in 8 subjects, oedema was evident in 6 subjects and burning sensation was evident in 3 subjects. The duration of the condition was less than 1 month in 36 subjects, 1-3 months in 45 patients, 3-12 months in 11 patients and over 1 year in 8 subjects. 72 topical and 18 topical and systemic treatment was taken by all 100 subjects.

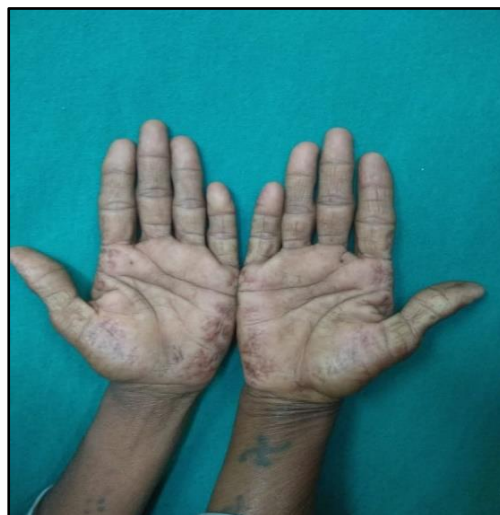Palmoplantar psoriasis was evident in 43 males and 28 females. 38 males and 32 females had eczema. Trophic ulcer was evident in 23 males and 37 females. Drug reactions were seen in 39 males and 23 females. 45 males and 21 females had viral infection. Fungal infection was seen in 52 males and 24 females.



**Fig 1: Palmoplantar psoriasis**



**Fig 2: Reticulate acropigmentation of Kitamura**



**Fig 3: Acrokeratoelastoidosis of Costa**

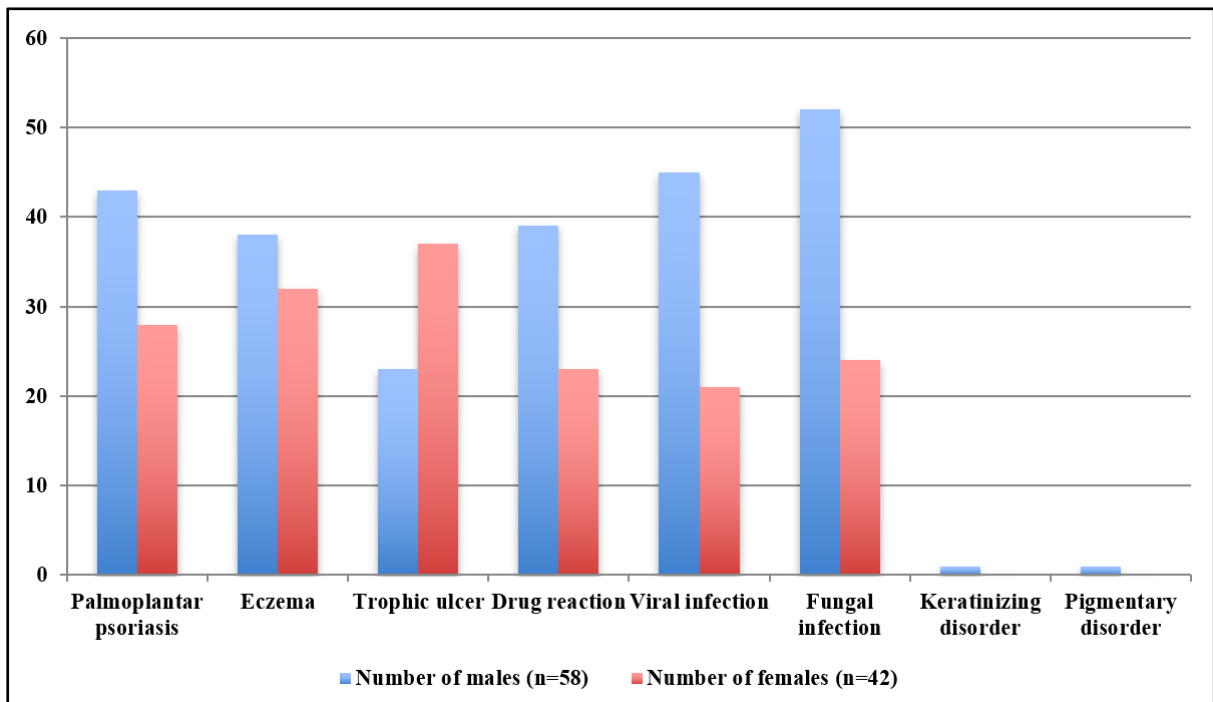
**Table 1: Clinical profile of the subjects with palmoplantar dermatoses**

Parameters	Number	Percentage
<b>Complaint</b>		
Itching	55	55
Redness	16	16
Pain	12	12
Peeling of skin	08	08
Oedema	06	06
Burning sensation	03	03

<b>Duration</b>		
<1 month	36	36
1-3 months	45	45
3-12 months	11	11
>1 year	08	08
<b>Aggravating factor</b>		
Seasonal variation	23	23
Trauma	54	54
Drugs	10	10
Contact with any irritant	13	13
<b>Treatment taken</b>		
Topical only	72	72
Topical and systemic	18	18

**Table 2: Distribution of palmoplantar dermatoses based on gender**

<b>Diagnosis</b>	<b>Number of males (n=58)</b>	<b>Number of females (n=42)</b>
<b>Palmoplantar psoriasis</b>	43	28
<b>Eczema</b>	38	32
<b>Trophic ulcer</b>	23	37
<b>Drug reaction</b>	39	23
<b>Viral infection</b>	45	21
<b>Fungal infection</b>	52	24
<b>Keratinizing disorder</b>	1	0
<b>Pigmentary disorder</b>	1	0



**Graph 1: Distribution based on gender**

## DISCUSSION

Palmoplantar dermatoses refer to skin disorders that specifically impact the palms of the hands and the soles of the feet. These conditions are frequently encountered in dermatological practice. Due to their location, they can lead to significant discomfort and social embarrassment for affected individuals, as they often disrupt routine daily activities.<sup>6</sup> The demographic affected by palmoplantar dermatoses is diverse, encompassing individuals from various occupational backgrounds, including those who work without gloves in slaughterhouses and healthcare professionals who don gloves in surgical settings. Identifying the underlying cause of these

dermatoses necessitates thorough patient history and engagement.<sup>7</sup>

The distinctive diagnostic characteristics of various skin conditions, such as psoriasis, dermatophytosis, and eczema, which may be evident on other body parts, are often altered or obscured on the palms and soles. Typically, hyperkeratosis is the predominant morphological feature observed in these regions, followed by papulovesicular eruptions, which occur with lesser frequency.<sup>8</sup>

In this study, itching was the chief complaint of 55 subjects. Redness and pain were observed in 16 and 12 subjects, respectively. Peeling of the skin was evident in 8 subjects, oedema was evident in 6 subjects and burning sensation was evident in 3

subjects. The duration of the condition was less than 1 month in 36 subjects, 1-3 months in 45 patients, 3-12 months in 11 patients and over 1 year in 8 subjects. 72 topical and 18 topical and systemic treatment was taken by all 100 subjects.

Palmoplantar psoriasis was evident in 43 males and 28 females. 38 males and 32 females had eczema. Trophic ulcer was evident in 23 males and 37 females. Drug reactions were seen in 39 males and 23 females. 45 males and 21 females had viral infection. Fungal infection was seen in 52 males and 24 females.

Nair PA et al<sup>9</sup> studied the clinical profile of patients suffering from palmoplantar dermatoses at a tertiary care centre. A prospective observational study was carried out from June 2014 to May 2015 in the Department of Dermatology, Venerology and Leprosy at a rural tertiary care centre after taking approval from the institutional ethical committee. In total, 202 cases were enrolled. The study was analyzed using Chi-square test. A total of 202 patients were enrolled, among which 53.46% were males. The most common age group affected was 17-40 years (42.57%). Duration of less than 1 month was seen in 31.7% cases whereas 29.7% showed seasonal variation. The most common chief complaint was itching (69.8%). Palmoplantar psoriasis was the most common dermatosis with 28.22% cases, followed by keratinizing disorders with 26.72% cases. Palms were involved in 66.34% cases, soles in 69.30%, and both palms and soles in 37.12% cases. Other body parts were involved in 15.34% of the cases. Diabetes and hypertension were common comorbid conditions seen in 11.4% of the cases each. Palmoplantar psoriasis was the most common disorder affecting palms and soles followed by palmoplantar keratoderma.

P VS et al<sup>10</sup> conducted a study that endeavoured to classify palmoplantar dermatoses based on their morphology and the clinical distribution pattern. A total number of 80 patients having palmoplantar dermatoses who met the study inclusion criteria were included. After taking proper informed consent, data were collected from patients on a fixed proforma sheet. The study comprised 44 (55%) male and 36 (45%) female patients. The mean duration of palmoplantar dermatoses was 2.92 years. Itching and painful fissures are the most common symptoms patients complained of, and psoriasis is the most common clinical type seen in 32 (40%) patients

followed by eczemas in 30 (37.5%) patients and fungal infections in 10 (12.5%) patients. The term palmoplantar dermatoses include a heterogeneous group of skin disorders, but no exact classification is present and classes differ based on the diseases to be kept in a group. Physicians should be well aware of the clinical features of these dermatoses and diagnosis is very important for early intervention and correct management, thereby helping improve patients' quality of life.

## CONCLUSION

In this study, the clinical profile of the subjects of palmoplantar dermatoses included pain, redness, irritation, peeling of skin, oedema, burning sensation and itching. The aggravation factors for this condition in the subjects of this study were seasonal variations, trauma, drugs and allergens.

## REFERENCES

1. Kumar B, Saraswat A, Kaur I. Palmoplantar lesions in psoriasis: A study of 3065 patients. *Acta Derm Venereol.* 2002; 82:192-5.
2. Valia RG. Eczema. In: Valia RG, Valia AR, editors. *IADVL Text Book of dermatology.* 3rd edition. India: Bhalani Publishing house; 2008. pp. 490-526.
3. Kang BS, Lee JD, Cho SH. A Clinicopathological Study of Palmoplantar Dermatoses. *Korean J Dermatology.* 2006; 44:714-20.
4. Mahajan PM, Gharpuray MB, Kulkarni V. Clinical and histopathological study of palmoplantar keratoderma. *Indian J Dermatol Venereol Leprol.* 1994; 60:258-61.
5. Kodali S. A Clinico-Histopathological Study of Acquired Palmoplantar Keratoderma in a Rural-Based Tertiary Hospital. *J Evolution Med Dent Sci.* 2014; 30:8500-5.
6. Valia RG. eczema. 3rd edition. Vol. 1. New Delhi, India: Bhalani Publishing House; 2008. Indian Association of Dermatologists, Venereologists and Leprologists. *Textbook of Dermatology;* pp. 503-509.
7. Palmoplantar dermatoses- a clinical study of 300 cases. Hongal AA, Rajashekhar N, Gejje S. *J Clin Diagn Res.* 2016;10:0-7.
8. A prospective study of clinical profile in patients of palmoplantar dermatoses. Nair PA, Diwan NG, Singhal R, Vora RV. *Indian Dermatol Online J.* 2017;8:331-335.
9. Nair PA, Diwan NG, Singhal R, Vora RV. A Prospective Study of Clinical Profile in Patients of Palmoplantar Dermatoses. *Indian Dermatol Online J.* 2017 Sep-Oct;8(5):331-335.
10. P VS, Prasad KN, Reddy DS, Boppani PK. Descriptive Study of the Clinical and Etiological Profiles of Palmoplantar Dermatoses in Patients Attending a Tertiary Care Hospital in Southern India. *Cureus.* 2021 Dec 8;13(12): e20268.