

## Case Report

## RARE CASE OF HIGH FLOW AV MALFORMATION IN MANDIBLE

Ashfaque Ansari<sup>1</sup>, Shivaji Pole<sup>2</sup>, Daanish Shaikh<sup>3</sup>

<sup>1</sup>Professor & HOD, Department of ENT, MGM Medical College & Hospital, Aurangabad, India.

<sup>2</sup>Associate Professor, Interventional Radiology, MGM Medical College & Hospital, Aurangabad, India.

<sup>3</sup>Junior Resident, Department of ENT, MGM Medical College & Hospital, Aurangabad, India.

Received : 05/12/2024  
Received in revised form : 31/01/2025  
Accepted : 15/02/2025

**Corresponding Author:**

**Dr. Daanish Shaikh**

Junior Resident, Department of ENT,  
MGM Medical College & Hospital,  
Aurangabad, India.  
Email: daanish21@gmail.com

DOI:10.70034/ijmedph.2025.1.125

Source of Support: Nil,  
Conflict of Interest: None declared

Int J Med Pub Health  
2025; 15 (1); 667-670

### ABSTRACT

**Background:** Arteriovenous malformations (AVMs) in the mandibular region are exceedingly rare and represent a direct shunting between arteries and veins without intervening capillaries. These lesions are significant due to their potential for severe bleeding and functional impact on the jaw and facial structures. The case involves a young adult who presented with spontaneous bleeding from the right lower molar, highlighting the clinical challenge of diagnosing and managing AVMs in atypical locations.

**Case Report:** A 20-year-old male patient came to the department of otolaryngology with complaints of persistent bleeding from the right lower molar. Diagnostic imaging, including Contrast-Enhanced Computed Tomography (CECT) and Digital Subtraction Angiography (DSA), revealed a high-flow arteriovenous malformation centered in the right parotid region extending into the mandibular ramus. The lesion received predominant arterial feed from branches of the right external carotid artery. Management included embolization followed by surgical ligation of the right external carotid artery branch, which achieved hemostasis and resolution of symptoms.

**Conclusion:** The successful management of this high-flow mandibular AVM required a multidisciplinary approach involving embolization and surgical intervention to control bleeding and prevent further complications. This case underscores the importance of vigilant follow-up and the potential for innovative surgical techniques in the management of complex vascular anomalies in sensitive anatomical regions. Further research and documentation of similar cases will aid in refining treatment strategies and improving patient outcomes.

**Keywords:** Arteriovenous Malformation (AVM), Mandibular Region, High-Flow Vascular Anomaly.

## INTRODUCTION

Arteriovenous malformations (AVMs) are complex vascular anomalies characterized by an abnormal connection between arteries and veins, bypassing the capillary system. These malformations can occur anywhere in the body but are most commonly found in the central nervous system and skin. However, AVMs in the mandibular region are exceedingly rare and pose significant clinical challenges due to their potential for severe bleeding and impact on facial structure and function.<sup>[1]</sup>

AVMs are congenital lesions that result from errors during vascular morphogenesis in the embryo. The etiology involves the dysregulated growth of

endothelial cells leading to the formation of arteriovenous shunts. Over time, these shunts can enlarge and proliferate, which may result in significant hemodynamic changes and lead to the clinical manifestations of AVMs, including pain, swelling, and life-threatening hemorrhages.<sup>[2,3]</sup>

The classification of AVMs is typically based on their hemodynamic characteristics, with high-flow AVMs involving direct arterial to venous connections without intervening capillaries, and low-flow AVMs involving venous malformations or capillary involvement. High-flow AVMs, like the one presented in this study, are particularly aggressive and more prone to complications such as bleeding and ulceration.<sup>[4,5]</sup>

Diagnosis of AVMs in the mandibular region typically involves a combination of clinical examination and imaging studies. Contrast-enhanced computed tomography (CECT), magnetic resonance imaging (MRI), and digital subtraction angiography (DSA) are crucial for delineating the extent of the AVM and planning treatment. These imaging modalities help in identifying the feeding arteries and draining veins, which is essential for any interventional treatment strategy.<sup>[6]</sup>

Treatment of mandibular AVMs can be challenging and often requires a multidisciplinary approach. The mainstay of treatment includes endovascular embolization, which aims to reduce the blood flow within the AVM by blocking the feeding arteries. This can be followed by surgical resection in cases where embolization alone is insufficient. The goal of treatment is to alleviate symptoms, prevent complications, and, ideally, completely eradicate the AVM.<sup>[7]</sup>

## CASE PRESENTATION

In this report, we describe a rare case of a high-flow arteriovenous malformation (AVM) located in the right mandibular region of a 20-year-old male patient. The patient has come to our department of otolaryngology with a chief complaint of spontaneous bleeding from the right lower molar, which he had been experiencing for approximately 15 days prior to his first consultation. This unusual presentation prompted an immediate and thorough clinical evaluation to determine the underlying cause of his symptoms and to develop an appropriate management plan.

Upon initial examination, the patient appeared to be in moderate distress with active bleeding evident from the gingival sulcus of the right lower molar. He reported intermittent episodes of swelling and a sensation of pulsation in the right mandibular area, which had progressively worsened over the last two weeks. His medical history was unremarkable, with no previous incidences of trauma or surgery to the facial region, and no significant familial history of vascular or hematologic disorders.

Given the severity and localization of the symptoms, a contrast-enhanced computed tomography (CECT) of the neck was promptly performed, which revealed a partially defined hyperdense lesion adjacent to the right ramus of the mandible, suggestive of a vascular malformation. Further imaging with cerebral digital subtraction angiography (DSA) confirmed the presence of a high-flow arteriovenous malformation primarily involving the right parotid region. The DSA images showed abnormal arterial feeders predominantly from branches of the right external carotid artery with significant venous drainage, and a minor contribution from the left external carotid artery involving facial and mandibular artery branches.

Given the complexity and high-flow characteristics of the AVM, a multidisciplinary team including otolaryngology, maxillofacial surgery, and interventional radiology was convened to plan the treatment strategy. The decision was made to proceed with pre-surgical embolization to reduce the risk of intraoperative and postoperative bleeding. The embolization procedure was meticulously carried out, focusing on occluding the primary feeders from the external carotid artery while preserving essential arterial branches to minimize the risk of ischemic complications.

The embolization was technically successful, and the patient showed an initial reduction in the size and pulsatility of the mass. However, within a week post-procedure, the patient presented again with bleeding from the lower third right molar, prompting further intervention. Surgical exploration revealed residual AVM branches that were not completely occluded during the embolization. A decision was made to perform surgical ligation of the right external carotid artery branches involved in the AVM, which was accomplished without complication.

Postoperative recovery was uneventful, and the bleeding resolved completely. The patient was discharged with close follow-up appointments. Serial imaging studies over the next six months showed a significant reduction in the size of the AVM and no evidence of recurrence. The patient reported substantial improvement in quality of life and complete cessation of the symptoms that initially brought him to medical attention.

This case highlights several important aspects of managing high-flow AVMs in the mandibular region. First, the clinical presentation of mandibular AVMs can be misleading, and a high index of suspicion is necessary when encountering unexplained oral bleeding. Second, imaging plays a crucial role in the diagnosis and management planning of AVMs, with CECT and DSA being indispensable tools for detailed vascular mapping. Third, a staged approach to treatment, involving pre-surgical embolization followed by surgical intervention, can be effective in managing the risks associated with high-flow AVMs. Lastly, the importance of a multidisciplinary team cannot be overstated, as it brings together diverse expertise necessary to address the complexities of AVM management safely and effectively.

The successful outcome of this case serves as a valuable addition to the limited literature on high-flow arteriovenous malformations in the mandibular region and underscores the potential for full recovery with appropriate and timely intervention. Continued vigilance and long-term follow-up remain essential to monitor for any signs of recurrence and to manage late-onset complications. This case also provides a framework for the development of guidelines aimed at standardizing the approach to similar vascular anomalies, potentially improving patient outcomes through

more systematic and informed therapeutic interventions.

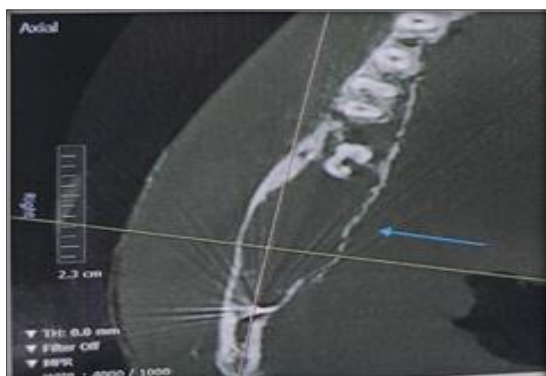


Figure 1: CBCT Coronal View

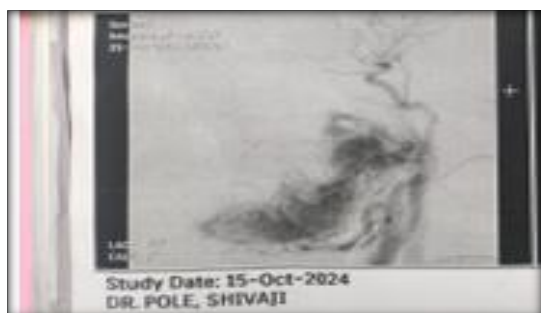

Figure 2: DSA Scan

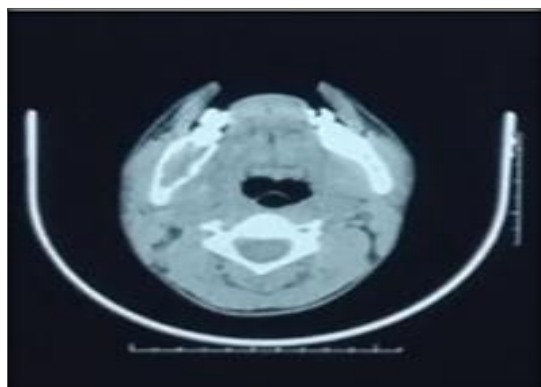


Figure 3: CT Scan Axial View

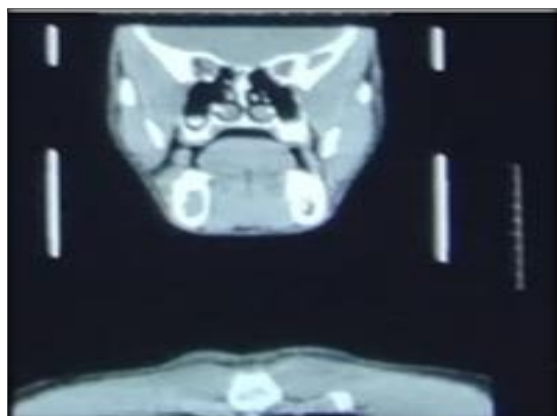


Figure 4: CT Scan Coronal View

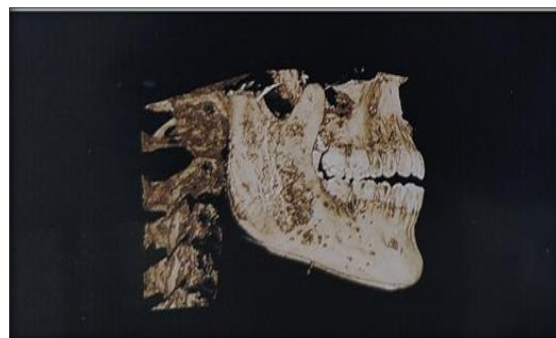

Figure 5: CBCT Scan 3D View

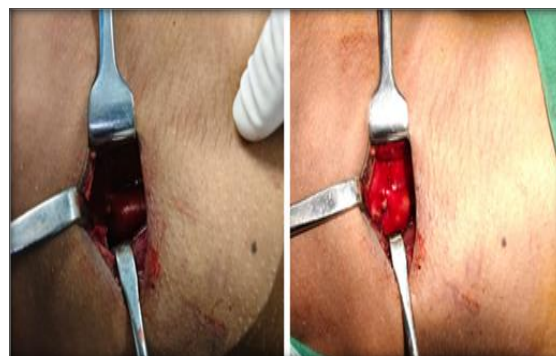

Figure 6: Intra OP

## DISCUSSION

Arteriovenous malformations (AVMs) in the mandibular region are a rare clinical entity, characterized by complex, abnormal connections between arteries and veins that bypass the capillary system. These lesions are associated with significant morbidity due to their propensity for massive hemorrhage and potential to cause deformative changes in critical anatomical structures. In discussing the current case of high-flow AVM in the right mandibular region, it is essential to contextualize the findings and treatment approaches with other studies that have explored similar manifestations.

**Epidemiology and Incidence:** AVMs in the mandibular region are noted to be extremely rare. According to Li *Xet al.* (2020),<sup>[8]</sup> craniofacial AVMs constitute less than 2% of all vascular anomalies, with mandibular AVMs being a smaller subset. The rarity increases the complexity of diagnosis and requires a high degree of clinical suspicion Kaderbhai J *et al.* (2017).<sup>[9]</sup>

**Diagnostic Techniques:** As demonstrated in our case, the use of CECT and DSA is critical for the accurate mapping of the lesion's extent and its feeding vessels. This diagnostic approach aligns with findings from Manjunath S *Met al.* (2014),<sup>[10]</sup> who emphasized the role of DSA as the gold standard for diagnosing and planning the treatment of AVMs due to its ability to detail the architecture of vascular lesions Kriwalsky M *Set al.* (2014).<sup>[11]</sup>

**Treatment Modalities:** The management strategy in our case involved pre-surgical embolization followed by surgical resection, which is consistent

with the treatment guidelines suggested by Tanoue *Set al.* (2023).<sup>[12]</sup> They reported high success rates with embolization as a prelude to surgery, reducing operative blood loss and facilitating lesion removal Nabeel AK *et al.* (2018).<sup>[13]</sup>

Furthermore, literature reviews by Karim AB *et al.* (2016),<sup>[14]</sup> suggest that for high-flow mandibular AVMs, a multi-disciplinary approach often results in a better prognosis and fewer complications. Their retrospective analysis showed that combining interventional radiology techniques with traditional surgery can minimize recurrence rates Chandra RV *et al.* (2014).<sup>[15]</sup>

**Outcomes and Follow-up:** Long-term follow-up is crucial, as indicated by Bhuyan SK *et al.* (2016),<sup>[16]</sup> who found a recurrence rate of approximately 10% within five years post-treatment in high-flow AVMs, necessitating ongoing surveillance and possible additional interventions Durán-Romero AJ *et al.* (2022).<sup>[17]</sup> The current case emphasizes the necessity for vigilant post-treatment monitoring to detect early signs of recurrence, aligning with best practices outlined in the broader literature.

**Innovative Treatments:** Recent studies, such as those by Mahady *et al.* (2015),<sup>[18]</sup> explore the use of newer embolic agents and advanced minimally invasive techniques that promise reduced recovery times and better cosmetic outcomes, suggesting potential areas for future treatment enhancement in mandibular AVM cases.

## CONCLUSION

The management of high-flow AVMs in the mandibular region poses significant challenges due to their aggressive nature and potential for life-threatening complications. The current case underlines the effectiveness of established diagnostic and treatment protocols while pointing to the need for innovative approaches to improve patient outcomes. The case also highlights the importance of a multidisciplinary approach in managing complex vascular anomalies.

## REFERENCES

- Ferrés-Amat E, Prats-Armengol J, Maura-Solivellas I, Ferrés-Amat E, Mareque-Bueno J, Ferrés-Padró E. Gingival bleeding of a high-flow mandibular arteriovenous malformation in a child with 8-year follow-up. *Case Reports in Pediatrics*. 2015;2015(1):745718.
- Kansy K, Bodem J, Engel M, Freudlsperger C, Möhlenbruch MA, Herweh C, Bendszus M, Hoffmann J, Kargus S. Interdisciplinary treatment algorithm for facial high-flow arteriovenous malformations, and review of the literature. *Journal of Cranio-Maxillofacial Surgery*. 2018 May 1;46(5):765-72.
- Ramakrishnan K, Palanivel I, Narayanan V, Chandran S, Gurram P. Management of vascular malformations in the oral and maxillofacial region: a systematic review. *Journal of Stomatology, Oral and Maxillofacial Surgery*. 2021 Dec 1;122(6):588-99.
- Dwivedi AN, Pandey A, Kumar I, Agarwal A. Mandibular arteriovenous malformation: A rare life-threatening condition depicted on multidetector CT angiography. *Journal of Oral and Maxillofacial Pathology*. 2014 Jan 1;18(1):111-3.
- Lakkasetty YT, Malik S, Shetty A, Nakhaei K. Multiple vascular malformations in head and neck-Rare case report. *Journal of Oral and Maxillofacial Pathology*. 2014 Jan 1;18(1):137-42.
- Kumar A, Mittal M, Srivastava D, Jaetli V, Chaudhary S. Arteriovenous malformation of face. *Contemporary clinical dentistry*. 2017 Jul 1;8(3):482-4.
- Petel R, Ashkenazi M. Pediatric intraoral high-flow arteriovenous malformation: a diagnostic challenge. *Pediatric Dentistry*. 2014 Oct 15;36(5):425-8.
- Li X, Su L, Wang D, Gui Z, Jiang M, Yang X, Han Y, Zhang L, Zheng L, Fan X. Clinical and imaging features of intraosseous arteriovenous malformations in jaws: a 15-year experience of single centre. *Scientific Reports*. 2020 Jul 21;10(1):12046.
- Kaderbhai J, Breik O, Heggie AA, Penington AJ. High-flow paediatric mandibular arteriovenous malformations: case reports and a review of current management. *International Journal of Oral and Maxillofacial Surgery*. 2017 Dec 1;46(12):1650-5.
- Manjunath SM, Shetty S, Moon NJ, Sharma B, Metta KK, Gupta N, Goyal S, Singh S. Arteriovenous malformation of the oral cavity. *Case reports in dentistry*. 2014;2014(1):353580.
- Kriwalsky MS, Papadimas D, Maurer P, Brinkmann M, Jackowski J, Kunkel M. Life-threatening bleeding after tooth extraction due to vascular malformation: a case report and literature review. *Oral and maxillofacial surgery*. 2014 Sep; 18:279-82.
- Tanoue S, Tanaka N, Koganemaru M, Kuhara A, Kugiyama T, Sawano M, Abe T. Head and neck arteriovenous malformations: clinical manifestations and endovascular treatments. *Interventional Radiology*. 2023 Jul 1;8(2):23-35.
- Nabeel AK, Jacob JE, Bose T, Sangeetha KP, Sandhya KN, Balan A. Great radiologic imitators: Arteriovenous malformation of mandible—A case series. *Contemporary Clinical Dentistry*. 2018 Jul 1;9(3):502-8.
- Karim AB, Lindsey S, Bovino B, Berenstein A. Oral surgical procedures performed safely in patients with head and neck arteriovenous malformations: a retrospective case series of 12 patients. *Journal of Oral and Maxillofacial Surgery*. 2016 Feb 1;74(2):255-e1.
- Chandra RV, Leslie-Mazwi TM, Orbach DB, Kaban LB, Rabinov JD. Transarterial embolization of mandibular arteriovenous malformations using ONYX. *Journal of Oral and Maxillofacial Surgery*. 2014 Aug 1;72(8):1504-10.
- Bhuyan SK, Birmiwala KG, Kar IB, Bhuyan R, Debta P. High flow AV malformation (AV shunt) of mandible: A rare life threatening entity. *Journal of Clinical and Diagnostic Research: JCDR*. 2016 Nov;10(11):ZD16.
- Durán-Romero AJ, Hernández-Rodríguez JC, Ortiz-Álvarez J, Domínguez-Cruz JJ, Monserrat-García MT, Conejo-Mir Sánchez J, Bernabeu-Wittel J. Efficacy and safety of oral sirolimus for high-flow vascular malformations in real clinical practice. *Clinical and Experimental Dermatology*. 2022 Jan 1;47(1):57-62.
- Mahady K, Thust S, Berkeley R, Stuart S, Barnacle A, Robertson F, Mankad K. Vascular anomalies of the head and neck in children. *Quantitative imaging in medicine and surgery*. 2015 Dec;5(6):886.