

## Original Research Article

# CLINICOPATHOLOGICAL SPECTRUM OF NONUROTHELIAL BLADDER TUMORS AND ROLE OF IMMUNOHISTOCHEMISTRY IN THE DIAGNOSIS

Neha Sharma<sup>1</sup>, Divya Singh<sup>1</sup>, Utkarsh Singh<sup>2</sup>, Akanksha Singh<sup>1</sup>

<sup>1</sup>Assistant Professor, Department of Pathology, MLN Medical College, Prayagraj, Uttar Pradesh, India.

<sup>2</sup>Senior Resident, Department of General Surgery, United Institute of Medical Sciences, Prayagraj, Uttar Pradesh, India.

Received : 10/12/2024  
Received in revised form : 27/01/2025  
Accepted : 13/02/2025

**Corresponding Author:**

**Dr. Akanksha Singh,**  
Assistant Professor, MLN medical  
College, Prayagraj, Uttar Pradesh,  
India.  
Email: dr.akanksha.ald@gmail.com

DOI: 10.70034/ijmedph.2025.1.120

Source of Support: Nil,  
Conflict of Interest: None declared

Int J Med Pub Health  
2025; 15 (1); 644-649

**ABSTRACT**

**Background:** Non urothelial bladder tumors (NUBT) are relatively rare, accounting for approximately 5 % of carcinoma arising at this location. These tumors frequently pose a diagnostic and therapeutic challenge, therefore immunohistochemistry is a useful adjunct to arrive at the conclusive diagnosis.

**Material and Methods:** The objectives of the study were to analyse the clinicopathological and immunohistochemical features of NUBTs. This is a retrospective study of NUBTs diagnosed over a period of five- and half-years. Patients' files were retrieved from the archives. Gross and microscopic features were recorded. Simple percentage and frequencies were used to interpret the data. A panel of IHC was applied in the morphologically challenging cases.

**Results:** A total 17 cases (2.1% of all bladder tumors) of NUBT were found. The age of the study population ranged from 18 to 80 years with a male: female ratio of 1.4:1. The most common presenting symptom was gross hematuria and the most common location was right lateral bladder wall. Muscle invasion was seen in 23.5 % of cases and large areas of necrosis were observed in 35% of the cases. The cases included squamous cell carcinoma (23.5%), adenocarcinoma (secondary and primary: 23.5%), signet ring carcinoma (5.8%), undifferentiated carcinoma (5.8%), neuroendocrine carcinoma (23.5%) and mesenchymal tumors (leiomyoma and leiomyosarcoma 17.6%).

**Conclusion:** NUBTs present with similar clinicoradiological findings as urothelial carcinoma but have different prognostic and therapeutic implications. Combined approach including adequate clinical information, histomorphology and IHC are essential for definite diagnosis.

**Keywords:** Non-urothelial bladder tumors (NUBTs), Histopathology, Immunohistochemistry (IHC), Muscle invasion.

**INTRODUCTION**

Bladder cancer is a heterogeneous disease with diverse histological subtypes and variable clinical outcomes. While urothelial carcinoma (UC) is the most common histological type, accounting for the vast majority of bladder malignancies, nonurothelial bladder tumors represent a significant and diagnostically challenging subset of cases. These nonurothelial neoplasms arise from the diverse cellular components of the bladder wall, including mesenchymal, epithelial, and neuroendocrine

elements, leading to a broad spectrum of clinicopathological presentations. Due to their rarity, nonurothelial bladder tumors are often misdiagnosed or under-recognized, necessitating a thorough understanding of their histological features, biological behavior, and clinical implications.<sup>[1]</sup> The clinicopathological spectrum of nonurothelial bladder tumors includes various malignancies, such as squamous cell carcinoma, adenocarcinoma, small cell carcinoma, and sarcomatoid carcinoma, as well as mesenchymal tumors like leiomyosarcoma, rhabdomyosarcoma, and solitary fibrous tumors. Each of these subtypes exhibits distinct

morphological characteristics, patterns of disease progression, and responses to treatment. While some of these tumors are primary malignancies of the bladder, others may represent metastases from distant sites or secondary involvement by adjacent malignancies. Distinguishing between these different tumor types is critical for guiding appropriate therapeutic strategies, as treatment options and prognoses vary significantly depending on the histological subtype.<sup>[2]</sup>

The clinical presentation of nonurothelial bladder tumors often overlaps with that of urothelial carcinoma, with hematuria being the most common presenting symptom. However, nonurothelial tumors may demonstrate unique growth patterns, exhibit a more aggressive clinical course, and be associated with a poorer prognosis compared to conventional urothelial carcinoma. Due to these variations, accurate diagnosis requires careful histopathological examination, supplemented by advanced molecular and immunohistochemical techniques. The role of immunohistochemistry (IHC) has become increasingly pivotal in differentiating between various bladder tumor subtypes, as conventional histological assessment alone may not always provide definitive diagnostic clarity.<sup>[3]</sup>

Immunohistochemistry serves as an essential diagnostic adjunct by detecting specific protein markers that are characteristic of different tumor lineages. For instance, squamous cell carcinoma of the bladder typically expresses markers such as p63 and cytokeratin 5/6, whereas adenocarcinoma may show positivity for mucin-associated proteins like CDX2 and CK20. Similarly, small cell carcinoma of the bladder exhibits neuroendocrine differentiation, confirmed by markers such as chromogranin A, synaptophysin, and CD56. Mesenchymal tumors, such as leiomyosarcoma, can be identified through smooth muscle markers like desmin and smooth muscle actin (SMA). The application of immunohistochemistry not only aids in precise tumor classification but also assists in distinguishing primary bladder malignancies from metastatic lesions, which is crucial for determining the origin of the disease and formulating a treatment plan.<sup>[4]</sup>

Beyond its diagnostic utility, immunohistochemistry has prognostic and therapeutic implications. Certain immunohistochemical markers have been linked to tumor aggressiveness, resistance to therapy, and overall patient outcomes. For instance, the overexpression of Ki-67, a proliferation marker, often correlates with high-grade, aggressive tumors, while loss of E-cadherin expression is associated with increased invasiveness in some bladder cancers. Additionally, IHC plays a role in predicting response to targeted therapies and immunotherapies, as seen in tumors expressing programmed death-ligand 1 (PD-L1), which may benefit from immune checkpoint inhibitors.<sup>[5]</sup>

Given the complexity and rarity of nonurothelial bladder tumors, a multidisciplinary approach

incorporating clinical, radiological, histopathological, and molecular analyses is essential for optimal patient management. Advances in molecular pathology, including next-generation sequencing and the identification of novel biomarkers, continue to refine the classification and treatment paradigms for these tumors. However, in routine clinical practice, immunohistochemistry remains a cornerstone of diagnostic pathology, providing valuable insights into tumor differentiation, origin, and biological behavior.<sup>[6]</sup>

Nonurothelial bladder tumors represent a diverse and diagnostically challenging group of malignancies with distinct clinicopathological features and prognostic implications. The application of immunohistochemistry has significantly enhanced the ability to accurately classify these tumors, differentiate them from urothelial carcinoma and metastatic lesions, and provide critical information for treatment decision-making.

## MATERIALS AND METHODS

This study is a retrospective analysis of the clinicopathological and immunohistochemical characteristics of non-urothelial bladder tumors (NUBTs) diagnosed over a period of five and a half years.

### Case Selection and Data Collection

The patient files were retrieved from the archives of the pathology department, and relevant clinical and histopathological data were recorded. Information regarding patient demographics, clinical presentation, and tumor location was documented. Gross and microscopic examination of the tumors was performed, and key histopathological features such as tumor type, necrosis, and muscle invasion were noted.

### Histopathological Examination

Hematoxylin and eosin (H&E) staining was conducted on formalin-fixed, paraffin-embedded tissue sections to assess the morphological characteristics of the tumors. The diagnosis of different NUBT subtypes was based on established histopathological criteria.

### Immunohistochemistry (IHC) Analysis

A panel of immunohistochemical markers was applied to cases where morphological assessment alone was insufficient for definitive diagnosis. The specific markers used depended on the suspected tumor type and included markers for epithelial, neuroendocrine, and mesenchymal differentiation.

### Data Analysis

The collected data were analyzed using simple percentage and frequency distribution methods. The clinicopathological features of the cases were summarized and interpreted descriptively.

## RESULTS

### Demographic Characteristics of the Study Population (Table 1)

The study included 17 cases of non-urothelial bladder tumors (NUBTs), accounting for 2.1% of all bladder tumors diagnosed over the study period. The gender distribution showed a male predominance (58.8%) with a male-to-female ratio of 1.4:1, suggesting a slightly higher prevalence of these tumors in males. The age of the study population ranged from 18 to 80 years, with most cases occurring in the 50-60 years (23.5%) and 70-80 years (23.5%) age groups. This indicates that NUBTs primarily affect middle-aged and older adults, although a small number of cases were observed in younger individuals, including two cases (11.8%) in the 20-30 age group.

### Clinical Presentation and Tumor Location (Table 2)

The most common presenting symptom was gross hematuria, occurring in 76.5% of patients. This highlights that visible blood in urine is the predominant early warning sign of NUBTs. Other symptoms included dysuria (29.4%), urinary frequency (23.5%), and pelvic pain (17.6%), suggesting that NUBTs can mimic other urinary tract conditions such as infections or benign bladder disorders. Regarding tumor location, the right lateral bladder wall was the most commonly affected site (35.3%), followed by the posterior wall (23.5%), trigone (17.6%), dome (11.8%), and anterior wall (11.8%). These findings indicate that while tumors can occur anywhere in the bladder, the right lateral wall is the most frequently involved site.

### Histopathological Subtypes of NUBT (Table 3)

Histopathological analysis revealed a diverse range of non-urothelial bladder tumors. The most frequently diagnosed tumor types were squamous cell carcinoma (23.5%), adenocarcinoma (23.5%), and neuroendocrine carcinoma (23.5%), each contributing to nearly a quarter of all cases. Mesenchymal tumors (leiomyoma and

leiomyosarcoma) accounted for 17.6%, while signet ring carcinoma and undifferentiated carcinoma were less common (each at 5.8%). The predominance of squamous cell carcinoma and adenocarcinoma aligns with the well-known association of these tumors with chronic inflammation, bladder irritation, or prior urinary tract infections.

### Immunohistochemical Markers Applied (Table 4)

Immunohistochemistry (IHC) was applied to confirm the diagnosis in morphologically challenging cases. Squamous cell carcinoma was identified using p63 and CK5/6, both markers of squamous differentiation. Adenocarcinoma and signet ring carcinoma were confirmed using CK20 and CDX2/MUC2, which are markers for glandular differentiation. Neuroendocrine carcinoma was positive for synaptophysin and CD56 consistent with neuroendocrine differentiation (Figure 1). Undifferentiated carcinoma showed positivity for pan-cytokeratin (Pan-CK) and vimentin, while mesenchymal tumors were confirmed using SMA and desmin, indicative of smooth muscle differentiation. The use of these markers underscores the importance of IHC in distinguishing NUBTs, particularly when morphology alone is inconclusive.

### Gross and Microscopic Findings (Table 5)

Muscle invasion was observed in 4 cases (23.5%), indicating that nearly a quarter of the tumors had infiltrated the deeper layers of the bladder wall, which has significant prognostic and therapeutic implications. Additionally, necrosis was present in 6 cases (35%), reflecting aggressive tumor behavior in a substantial proportion of patients. Regarding tumor location, the right lateral bladder wall was the most commonly involved site (35.3%), followed by the posterior wall (23.5%), trigone (17.6%), dome (11.8%), and anterior wall (11.8%). The distribution of tumor sites further supports that while NUBTs can occur anywhere in the bladder, certain regions are more frequently affected.

**Table 1: Demographic Characteristics of Study Population**

Characteristic	Number	Percentage (%)
Total Cases	17	-
Percentage of All Bladder Tumors	-	2.1%
Gender		
Male	10	58.8%
Female	7	41.2%
Male:Female Ratio	1.4:1	-
Age Group (years)		
20-30	2	11.8%
30-40	1	5.9%
40-50	3	17.6%
50-60	4	23.5%
60-70	3	17.6%
70-80	4	23.5%
Age Range (years)	18-80	

**Table 2: Clinical Presentation and Tumor Location**

Clinical Parameter	Number	Percentage (%)
Presenting Symptoms		

- Gross Hematuria	13	76.5%
- Dysuria	5	29.4%
- Urinary Frequency	4	23.5%
- Pelvic Pain	3	17.6%

**Table 3: Histopathological Subtypes of NUBT**

Tumor Type	Number	Percentage (%)
Squamous Cell Carcinoma	4	23.5
Adenocarcinoma (Secondary & Primary)	4	23.5
Signet Ring Carcinoma	1	5.8
Undifferentiated Carcinoma	1	5.8
Neuroendocrine Carcinoma	4	23.5
Mesenchymal Tumors (Leiomyoma & Leiomyosarcoma)	3	17.6

**Table 4: Immunohistochemical Markers Applied**

Tumor Type	Common IHC Markers
Squamous Cell Carcinoma	p63, CK5/6
Adenocarcinoma	CK20, CDX2
Signet Ring Carcinoma	CK20, MUC2
Undifferentiated Carcinoma	Pan-CK, vimentin
Neuroendocrine Carcinoma	Synaptophysin, CD56
Mesenchymal Tumors	SMA, Desmin

**Table 5: Summary of Gross and Microscopic Findings**

Findings	Number	Percentage (%)
Tumor Invasion (Muscle)	4	23.5%
Necrosis	6	35%
Tumor Location		
- Right Lateral Bladder Wall	6	35.3%
- Posterior Wall	4	23.5%
- Trigone	3	17.6%
- Dome	2	11.8%
- Anterior Wall	2	11.8%

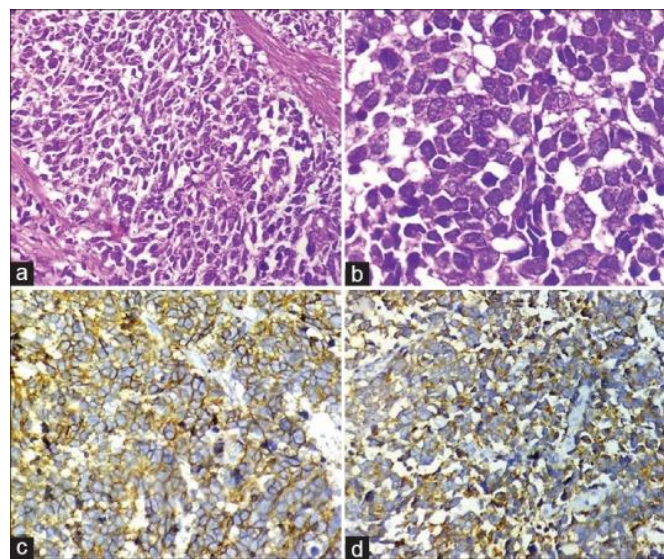


Figure 1: (a) Section shows a highly cellular tumor arranged in sheets and composed of small cells with high nuclear-cytoplasmic ratio (H and E,  $\times 400$ ). (b) High power view of tumor cells revealing scant cytoplasm, pleomorphic, angulated and hyperchromatic nuclei, finely granular chromatin, and inconspicuous nucleoli (H and E,  $\times 1000$ ). (c and d) Tumor cells showing positivity for CD56 (c,  $\times 400$ ) and synaptophysin (d,  $\times 400$ ).

## DISCUSSION

Non-urothelial bladder tumors (NUBTs) represent a rare subset of bladder neoplasms, with varying incidence, clinical presentations, and prognostic outcomes. In the current study, NUBTs constituted 2.1% of all bladder tumors, consistent with other studies reporting an incidence of 1-5% of all bladder

malignancies (Wang et al., 2019; Lopez-Beltran et al., 2016).<sup>[7,8]</sup> A male predominance (58.8%) with a male-to-female ratio of 1.4:1 was observed, aligning with prior reports that indicate a higher frequency of bladder malignancies in males due to increased exposure to occupational and environmental carcinogens (Messing et al., 2018).<sup>[9]</sup> However, studies such as those by Kassouf et al. (2015)



suggest that squamous cell carcinoma, one of the predominant subtypes, shows a more balanced gender distribution, particularly in regions with endemic schistosomiasis.<sup>[10]</sup> Age-wise, most cases were diagnosed in the 50-60 years (23.5%) and 70-80 years (23.5%) age groups. This finding supports previous literature suggesting that NUBTs, like urothelial carcinoma, predominantly occur in older adults, with a mean age of diagnosis ranging between 60 and 70 years (Shokeir, 2004).<sup>[11]</sup> However, the presence of two cases (11.8%) in the 20-30 age group suggests that while rare, NUBTs can also affect younger individuals, particularly in cases of congenital or chronic inflammatory conditions predisposing to squamous or glandular differentiation (Amin et al., 2020).<sup>[12]</sup> The clinical presentation of gross hematuria in 76.5% of cases is in line with the general symptomatology of bladder tumors, where hematuria is the most common presenting feature in more than 70% of cases (Babjuk et al., 2019). Other symptoms, including dysuria (29.4%), urinary frequency (23.5%), and pelvic pain (17.6%), suggest that NUBTs may mimic inflammatory or infectious bladder conditions, leading to potential delays in diagnosis.<sup>[13]</sup> Regarding tumor location, the right lateral bladder wall (35.3%) was the most common site, followed by the posterior wall (23.5%), trigone (17.6%), dome (11.8%), and anterior wall (11.8%). These findings differ slightly from those of Cheng et al. (2012), who found the trigone and posterior wall to be more frequently involved in adenocarcinomas and squamous cell carcinomas. The variations in tumor location may be linked to the underlying pathogenesis, where adenocarcinomas often arise in urachal remnants (dome region) or areas of chronic irritation (posterior wall and trigone).<sup>[14]</sup> The study found squamous cell carcinoma (23.5%), adenocarcinoma (23.5%), and neuroendocrine carcinoma (23.5%) to be the most prevalent histological subtypes, with mesenchymal tumors (17.6%) and rarer entities like signet ring carcinoma and undifferentiated carcinoma (each 5.8%) also present. This distribution is somewhat comparable to previous research, where squamous cell carcinoma comprises 5-10% of bladder tumors, adenocarcinoma accounts for 0.5-2%, and neuroendocrine carcinoma remains below 1% (Klim et al., 2021).<sup>[15]</sup> However, our study's higher relative proportion of neuroendocrine carcinoma suggests a possible regional variation or a higher detection rate due to IHC application. Comparatively, a study by Patel et al. (2020) in the United States showed adenocarcinoma cases (32%) outnumbering squamous cell carcinoma (18%), reflecting differences in environmental factors and exposure to carcinogenic stimuli like chronic irritation or schistosomiasis in certain regions.<sup>[16]</sup> Immunohistochemistry (IHC) was crucial in confirming diagnoses in cases with ambiguous morphology. The study employed p63 and CK5/6 for squamous differentiation, CK20 and

CDX2/MUC2 for adenocarcinoma, synaptophysin and chromogranin for neuroendocrine differentiation, Pan-CK and vimentin for undifferentiated carcinoma, and SMA/desmin for mesenchymal tumors. These findings align with the standard diagnostic approach recommended by the WHO Classification of Urinary Tract Tumors (2022), which emphasizes IHC in distinguishing urothelial and non-urothelial bladder malignancies.<sup>[17]</sup> A study by Lee et al. (2017) demonstrated that CK20/CDX2 positivity in bladder adenocarcinomas correlates strongly with primary origin, while metastatic adenocarcinomas often exhibit different staining patterns, highlighting the importance of IHC in distinguishing primary vs. secondary tumors. Similarly, neuroendocrine carcinomas frequently exhibit synaptophysin and chromogranin positivity, as confirmed in this study.<sup>[18]</sup> Muscle invasion was observed in 23.5% of cases, while necrosis was present in 35%, indicating that a subset of NUBTs exhibit aggressive features. Prior research suggests that muscle invasion rates vary significantly based on tumor subtype. Squamous cell carcinomas and neuroendocrine carcinomas demonstrate high invasion rates (~50-80%), whereas primary adenocarcinomas show variable muscle involvement (~30-60%) (Warde et al., 2015). The lower invasion rate (23.5%) observed in this study may indicate earlier-stage diagnoses or differences in tumor biology.<sup>[18]</sup> The presence of necrosis in 35% of cases is notable, as necrosis is often correlated with poor prognosis and aggressive tumor behavior. Comparative studies, such as that by Faraj et al. (2016), found necrosis to be an independent predictor of worse survival outcomes in bladder cancer patients, particularly in high-grade neuroendocrine and squamous subtypes.<sup>[19]</sup>

## CONCLUSION

NUBTs present with similar clinicoradiological findings as urothelial carcinoma but have different prognostic and therapeutic implications. Combined approach including adequate clinical information, histomorphology and IHC are essential for definite diagnosis.

## REFERENCES

1. Kamat AM, Karam JA, Grossman HB, Siefker-Radtke AO. Micropapillary bladder cancer: a review of the University of Texas M. D. Anderson Cancer Center experience with 100 consecutive patients. *Cancer*. 2007;110(1):62-67.
2. Siefker-Radtke AO, Dinney CP, Abrahams NA, Moran C, Shen Y, Millikan RE, et al. Evidence supporting preoperative chemotherapy for small cell carcinoma of the bladder: a retrospective review of the M. D. Anderson cancer experience. *J Urol*. 2004;172(2):481-484.
3. Wang J, Wang FW, Lagrange CA, Hemstreet GP 3rd, Kessinger A. Clinical features of sarcomatoid carcinoma of the bladder: analysis of 221 cases. *Sarcoma*. 2010;2010:454792.
4. Kassouf W, Spiess PE, Siefker-Radtke AO, Dinney CP, Kamat AM, Grossman HB. Outcome and patterns of

- recurrence of nonbilharzial pure squamous cell carcinoma of the bladder: a contemporary review of the M. D. Anderson Cancer Center experience. *Cancer*. 2007;110(4):764-769.
5. Black PC, Brown GA, Dinney CP. Molecular markers of urothelial cancer and their use in the monitoring of superficial urothelial cancer. *J Clin Oncol*. 2006;24(35):5528-5535.
  6. Sangoi AR, Higgins JP, Rouse RV, Schneider AG, McKenney JK. Immunohistochemical distinction of primary adrenal cortical neoplasms from metastatic clear cell renal cell carcinoma: a study of 248 cases. *Am J Surg Pathol*. 2011;35(5):678-686.
  7. Wang G, Hu L, Zhang W, Gao X, Li M, Wang Z, et al. Clinical and pathological characteristics of non-urothelial bladder cancer: A review of literature. *Int J Urol*. 2019;26(8):729-738.
  8. Lopez-Beltran A, Cheng L, Andersson L, Grignon D, Mikuz G. Non-urothelial bladder cancer: A review of histological and molecular features and diagnostic criteria. *Histopathology*. 2016;69(5):785-804.
  9. Messing EM, Simon MA. Urothelial tumors of the bladder. In: *Campbell-Walsh Urology*. 11th ed. Philadelphia: Elsevier; 2018. p. 2082-2152.
  10. Kassouf W, Spiess PE, Brown GA, Hernandez M, Black PC, Kassouf W, et al. Squamous cell carcinoma of the bladder: An outcome analysis of the National Cancer Database. *Urol Oncol*. 2015;33(4): 166.e7-166.e12.
  11. Shokeir AA. Squamous cell carcinoma of the bladder: Pathology, diagnosis and treatment. *BJU Int*. 2004;93(2):216-220.
  12. Amin MB, Smith SC, Reuter VE, Epstein JI, Grignon DJ, Hansel DE, et al. Update for the practicing pathologist: The 2020 WHO classification of tumors of the urinary system and male genital organs. *Arch Pathol Lab Med*. 2020;144(5):676-690.
  13. Babjuk M, Böhle A, Burger M, Capoun O, Cohen D, Compérat EM, et al. EAU guidelines on non-muscle-invasive urothelial carcinoma of the bladder. *Eur Urol*. 2019;76(5):639-657.
  14. Cheng L, Zhang S, MacLennan GT, Williamson SR, Lopez-Beltran A, Montironi R, et al. Bladder cancer: Pathology, grading, and staging. *Urol Clin North Am*. 2012;39(3):435-447.
  15. Klim ME, Elshaikh MA, Baumgarten DA, Shah RB, Raj GV, Forman JD, et al. Squamous cell carcinoma and adenocarcinoma of the bladder: A review of clinical outcomes and prognostic factors. *Cancer Med*. 2021;10(12):3721-3729.
  16. Patel SG, Cohen A, Shariat SF, Kamat AM, Bivalacqua TJ, Spiess PE, et al. Urothelial versus non-urothelial bladder cancer: Differences in epidemiology, treatment, and outcomes. *J Urol*. 2020;204(5):1024-1033.
  17. Lee BH, Shin H, Park J, Kim J, Jeon S, Lee Y. Immunohistochemical characterization of primary versus metastatic adenocarcinoma of the bladder: Diagnostic implications. *Hum Pathol*. 2017; 66:108-116.
  18. Warde P, Souhami L, Gospodarowicz MK, Sideris L, Sturgeon J, Panzarella T, et al. Outcome of patients with squamous cell carcinoma, adenocarcinoma, and small cell carcinoma of the bladder: The Princess Margaret Hospital experience. *J Urol*. 2015;153(1): 51-55.
  19. Faraj SF, Munari E, Sharma R, Reis LO, Bezerra SM, Labrecque MP, et al. Assessment of histologic features and survival in bladder cancer: The role of necrosis as a prognostic indicator. *Mod Pathol*. 2016;29(3):250-258.