



Case Report

A RARE CASE OF RETROPERITONEAL LIPOSARCOMA COMPLICATED WITH GIANT COLONIC DIVERTICULUM: CASE REPORT

Amitabh Goel¹, Vandana Bansal², Laalji Patel³, Sonal Nivsarkar⁴, Dolly Mehta⁵, Sana Afrin⁶, Saranshi Shrivastava⁷, Rahul Patidar⁸

¹Senior consultant and Director of Laparoscopic Surgery and Head of Department of General Surgery (MS, FAIS, FICS, FIAGES, FALS, FAMS), Vishesh Jupiter Hospital, Indore, Madhya Pradesh, India.

²Senior consultant, Department of Surgery, Vishesh Jupiter Hospital, Indore, Madhya Pradesh, India.

³Senior consultant, Department of Gastroenterology, Vishesh Jupiter Hospital, Indore, Madhya Pradesh, India.

⁴Senior consultant, Department of Anaesthesia, Vishesh Jupiter Hospital, Indore, Madhya Pradesh, India.

⁵Assistant Professor, Department of Community Medicine, Sri Aurobindo Medical College & Post Graduate Institute, Indore, Madhya Pradesh, India.

⁶Assistant Professor, Department of Community Medicine, Sri Aurobindo Medical College & Post Graduate Institute, Indore Madhya Pradesh, India.

⁷Senior Resident, Department of Surgery, M.G.M. Medical College & M.Y. Hospital, Indore, Madhya Pradesh, India.

⁸Physician Assistant, Department of Surgery, Vishesh Jupiter Hospital, Indore, Madhya Pradesh, India.

Received : 07/01/2024

Received in revised form : 18/03/2024

Accepted : 04/04/2024

Corresponding Author:

Dr. Amitabh Goel

Senior Consultant and Director of Laparoscopic Surgery and Head of Department of General Surgery (MS,FAIS,FICS,FIAGES,FALS,FAMS), Vishesh Jupiter Hospital, Indore, Madhya Pradesh, India.

Email: goelamitabh@hotmail.com

DOI: 10.5530/ijmedph.2024.2.13

Source of Support: Nil

Conflict of Interest: None declared

Int J Med Pub Health

2024; 14 (2); 64-69

ABSTRACT

The co-occurrence of retroperitoneal liposarcoma and a giant colonic diverticulum poses diagnostic challenges due to their uncommon nature and overlapping clinical presentations. Here, we present a unique case report of a 76-year-old female with hypertension and myasthenia gravis who presented to Vishesh Jupiter Hospital, Indore and diagnosed with retroperitoneal liposarcoma complicated by a giant colonic diverticulum detailing its presentation, diagnostic journey and management strategies.

Keywords: Retroperitoneal liposarcoma, Giant Colonic Diverticulum.

INTRODUCTION

Retroperitoneal liposarcoma is a rare malignant tumor originating from adipose tissue within the retroperitoneum, characterized by its aggressive nature and potential for substantial morbidity and mortality.^[1] Retroperitoneal liposarcoma accounts for 10-15% of all soft tissue tumours and affects less than 1 in every 100,000 people each year.^[2] The World Health Organization (WHO) recognizes four histological forms of liposarcomas: well-differentiated, dedifferentiated, pleomorphic, and myxoid. Patients typically present with advanced disease and often have poor prognosis due to the expansive nature of the retroperitoneal space, leading to asymptomatic growth until the tumor reaches a size that impacts surrounding structures or vital

organs. Managing these malignant tumors poses therapeutic challenges due to their rarity and anatomical location, and diagnosis can also be challenging.^[3]

Giant colonic diverticulum is an uncommon complication of colonic diverticulosis characterized by the enlargement of a single diverticulum to over 4 cm in diameter. Since its initial description in 1946, fewer than 200 cases have been reported worldwide. The clinical presentation of GCD can vary widely, ranging from asymptomatic incidental findings to severe complications such as abdominal distension and pain, perforation, abscess, adhesions formation, obstruction and volvulus.^[4,5]

The simultaneous presence of retroperitoneal liposarcoma and a giant colonic diverticulum presents diagnostic complexities due to their rarity

and similar clinical manifestations. Here, we describe a distinctive case of a 76-year-old female with hypertension and myasthenia gravis, who sought medical attention at Vishesh Jupiter Hospital in Indore. She was diagnosed with retroperitoneal liposarcoma complicated by a giant colonic diverticulum. This case report outlines the patient's presentation, diagnostic challenges encountered during her medical journey, and the strategies employed for management.


CASE REPORT

A 76-year-old female presented to the department of general surgery of Vishesh Jupiter Hospital Indore, in March, 2024 with complaints of abdominal pain and constipation persisting for 3-4 days and 8 days, respectively, unrelieved by laxatives. She had a known history of hypertension and myasthenia gravis. On physical examination vitals were stable. A palpable abdominal mass with tenderness over the left flank was observed on systemic examination. Bowel sounds were hypoactive on auscultation.

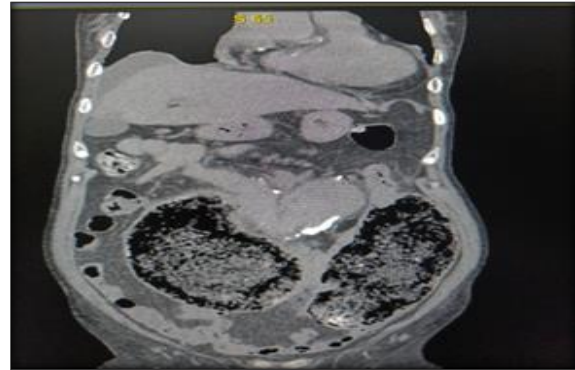
Blood investigations were carried out which showed mild anemia (Haemoglobin: 9.2 g/dL) and electrolyte disturbances (Sodium: 136.1 mmol/L, Potassium: 3.16 mmol/L). Rest parameters were within normal limits (White Blood Cell Count: $4.07 \times 10^9/L$, Platelet Count: $310 \times 10^9/L$, Blood Urea Nitrogen: 7 mg/dL, Serum Creatinine: 0.66 mg/dL, Serum Glutamate Pyruvate Transaminase: 13 U/L) and patient was non-reactive for viral markers.

Echocardiography revealed normal left ventricular function with mild tricuspid regurgitation, mild pulmonary arterial hypertension, left ventricular hypertrophy, and grade-1 diastolic dysfunction.

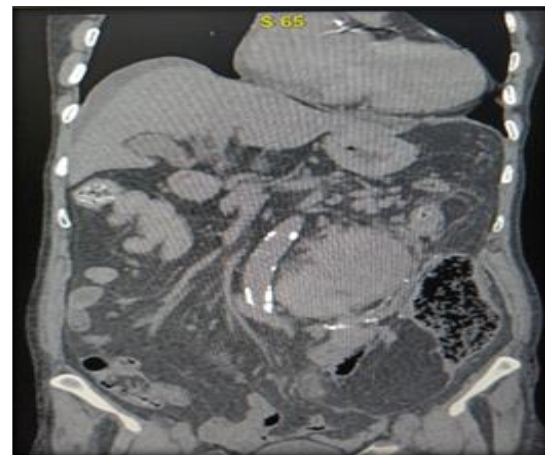
Contrast Enhanced Computed Tomography (CECT) of the abdomen revealed a large left retroperitoneal mass measuring 18.0x7.5x8.0 cm closely adherent to the sigmoid colon, causing closed-loop obstruction volvulus of distal descending colon / proximal sigmoid and resultant massively distended faeces filled segment of colon measuring approximately 22.0x11.0x18.5 cm occupying the mid lower abdomen on both sides. Close approximation of duodeno-jejunal flexure with mass was also noted. The mass encased adjacent structures, including the superior rectal vein and proximal mid-third of the left ureter resulting in proximal moderate hydronephrosis. Posteromedially the mass infiltrated the psoas muscle for approximately 6.5-7.0 cm in its upper third. Additionally, a small amount of ascites and diffuse hazy omentomesentery were noted as shown in Figure (a), (b), (c) and (d).



(a)



(b)



(c)

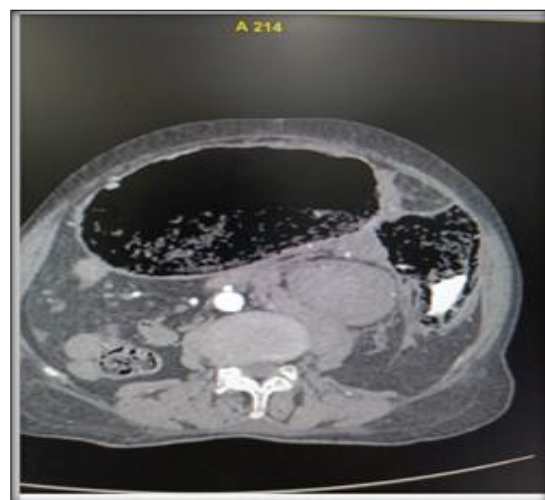


Figure (a), (b), (c) and (d): CECT Images showing left sided retroperitoneal liposarcoma with multiple colonic diverticula.

For further assessment, the patient underwent CT-guided biopsy; the histopathological examination (HPE) of which was suggestive of spindle cell tumour of atleast intermediate grade.

The patient was initially managed conservatively with intravenous (IV) fluids, antibiotics, analgesics, and antacids. Following confirmation of the diagnosis, surgical intervention was planned.

Under general anaesthesia, the patient underwent a midline abdominal incision. Exploration revealed a very large diverticulum of colon along with multiple other diverticula [Figure: (e), (f), (g)] which were excised. The posterior wall was badly adherent to the mass which was suspected to be a sarcoma [Figure: (h)]. Cauterization was performed on posteromedial wall. End colostomy was done followed by lavage and distal end was ligated. Cystoscopy was conducted followed by placement of a left double-J (DJ) stent.

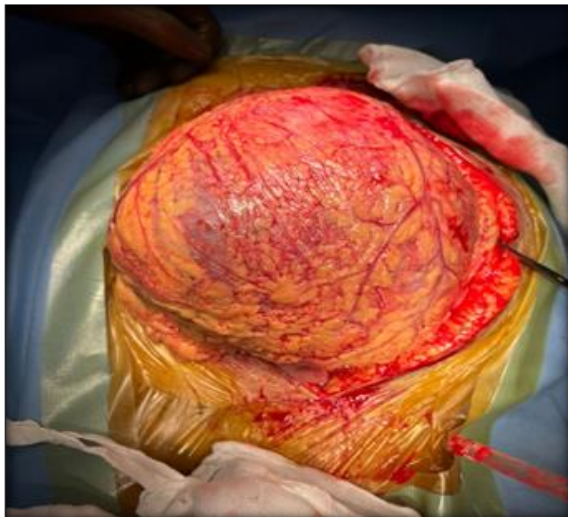

Figure (e): Large diverticulum with overlying omentum

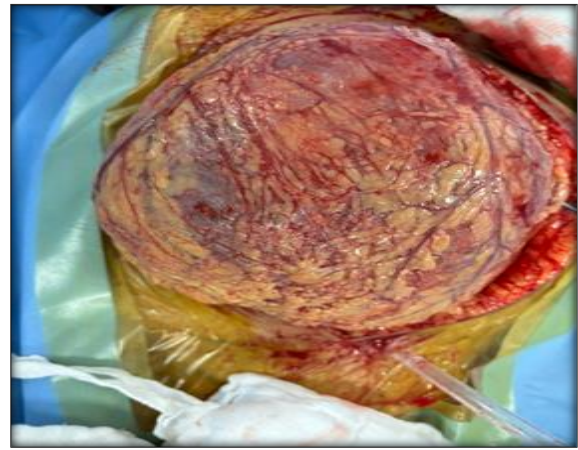
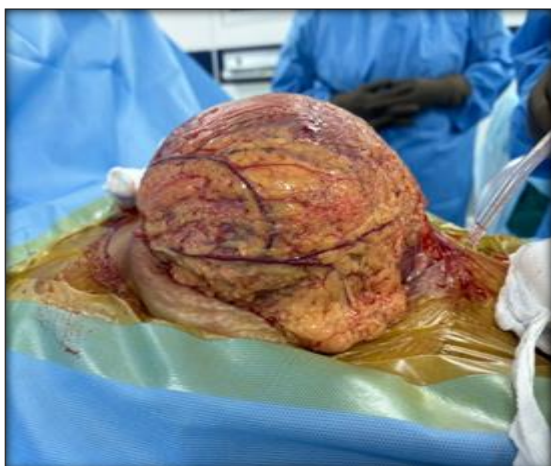


Figure (f): Large diverticulum with papery thin wall and overlying omentum

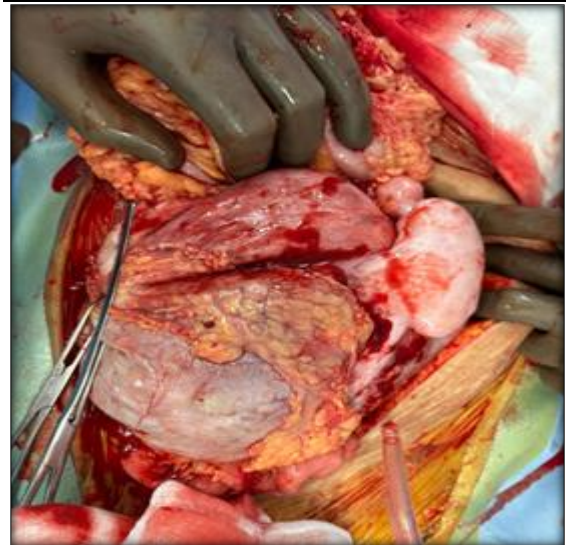


Figure (g): Multiple diverticula with diverticulitis

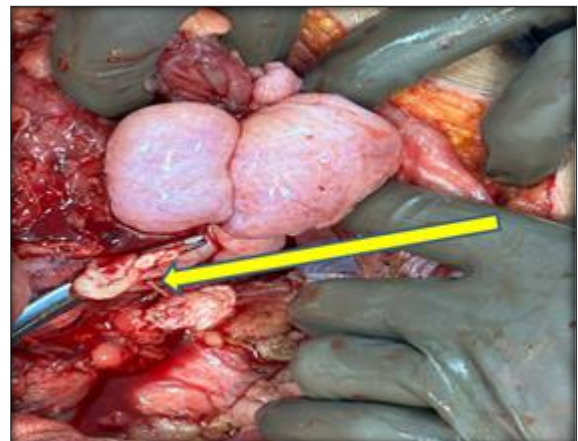


Figure (h): Arrow showing left sided retroperitoneal liposarcoma along with multiple diverticula and diverticulitis.

The resected dilated colonic segment (11.0X 11.0X 5.0 cm) was further sent for histopathological examination (HPE), which was suggestive of features consistent with dedifferentiated Liposarcoma of the soft tissue mass infiltrating the colonic segment.

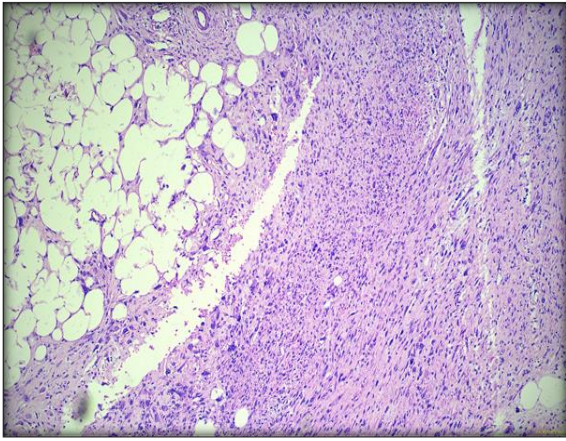


Figure (i): Dedifferentiated Liposarcoma of the soft tissue mass infiltrating the colonic segment

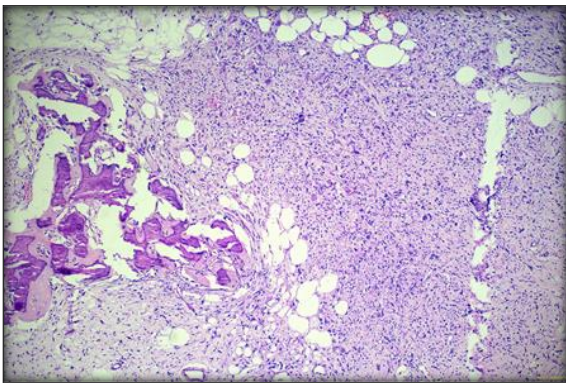


Figure (j): Liposarcoma of the soft tissue mass infiltrating the colonic segment

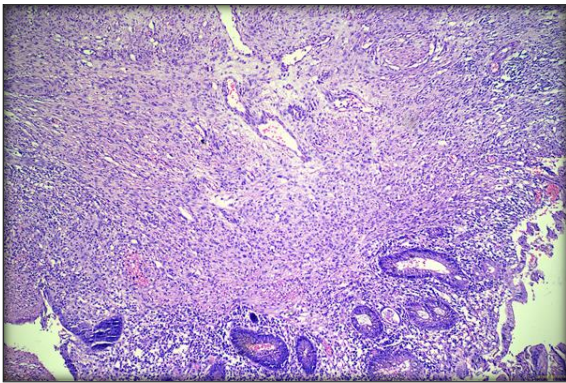


Figure (k): Liposarcoma with ulcerated mucosa infiltrating the colonic segment

The patient recovered well post-operatively and was discharged home after seven days with instructions for follow-up. Patient was also referred to medical and radiation oncology department for further work up. Regular surveillance and imaging studies were planned to monitor for recurrence.

DISCUSSION

Retroperitoneal liposarcoma is a rare malignant tumor arising from adipose tissue in the retroperitoneum, while giant colonic diverticulum is an uncommon complication of colonic

diverticulosis. This discussion focuses on the unique presentation of retroperitoneal liposarcoma complicated with a giant colonic diverticulum, discussing the diagnostic challenges, management strategies, and implications for clinical practice.

Here, we present a case of 76-year-old female with hypertension and myasthenia gravis who was diagnosed with left retroperitoneal liposarcoma complicated with giant colonic diverticulum, which to the best of our knowledge is a unique case report. Syllaios A et al, 2018,^[5] stated that the age of diagnosis of a giant colonic diverticulum (GCD) ranges from 32-90 years with most common age of presentation being above sixty years. Locatelli A et al, 2018,^[6] discussed that majority patients present in the age group of 60-79 years. Frenken MR et al, 2022,^[7] reported the mean age to be 60 and 79 years. These findings were similar to our case report. However the overall prevalence of retroperitoneal liposarcoma is seen at 50-60 years of age as per Xiao J et al, 2021,^[8]; and at 40-60 years as per Sharma R et al 2019,^[9] which was contrary to our case who was 76 years old. While Chaudhari et al, 2022,^[10] reported that the peak incidence of retroperitoneal liposarcoma occurs during the 5th decade of life, they documented a case involving a young 32-year-old male.

Both retroperitoneal liposarcoma and GCD show no sex predilection, with equal representation in both sexes as per Sharma R et al, 2019,^[9] Verras GI et al, 2021,^[11] Xiao J et al, 2021,^[8] Nureta TH et al, 2023,^[3] and Locatelli A et al, 2018.^[6]

The coexistence of retroperitoneal liposarcoma and a giant colonic diverticulum can have nonspecific clinical manifestations, making accurate diagnosis challenging. In our case report patient presented with complaints of abdominal pain and constipation. Similarly in a study of 166 GCD cases conducted by Nigri G et al, 2015,^[12] abdominal pain and constipation were the most common symptoms. Similar symptoms were also reported by Carr JA, 2017,^[4] and Frenken MR et al, 2022,^[7] in cases of GCD. Xiao J et al, 2021,^[8] conducted a study in 57 cases of retroperitoneal liposarcoma and found abdominal discomfort, distension and abdominal pain as the most common symptoms in these patients. Nureta TH et al, 2023,^[3] and Chaudhari et al, 2022,^[1] also discussed that patient present with vague complaints such as abdominal pain and weight loss. Nureta et al, 2023,^[3] stated that patients remain asymptomatic until the mass becomes large enough to exert pressure on surrounding structures or infiltrate crucial organs. Similarly, Xiao J et al, 2021,^[8] discussed that the size of the tumor is directly related to the complaints of abdominal discomfort.

In our case during systemic examination, a palpable abdominal mass accompanied by tenderness over the left flank was noted. Additionally, bowel sounds were found to be hypoactive upon auscultation. Xiao J et al, 2021,^[8] and Chaudhari et al, 2022,^[10] also discussed that majority patients presented with

tangible mass on palpation in cases of retroperitoneal liposarcoma. Palpable abdominal mass either tender or non-tender in cases of GCD has also been reported by Nigri G et al, 2015,^[12] and Frenken MR et al, 2022.^[7]

Imaging modalities play a crucial role in diagnosing retroperitoneal liposarcoma and giant colonic diverticulum. Computed Tomography (CT) scans, Magnetic Resonance Imaging (MRI), and ultrasound may help delineate the extent of the retroperitoneal mass and assess its relationship with adjacent structures. Additionally, contrast studies or CT scans with oral contrast can reveal the presence of colonic diverticula and associated complications, such as perforation or abscess formation. In the present case report CECT and CT guided biopsy were performed for confirmation of diagnosis. Xiao J et al, 2021,^[8] opined that CT and MRI are the most appropriate modalities for diagnosis of retroperitoneal liposarcoma while Nureta et al, 2023,^[3] suggested that sensitivity of MRI was higher than CT with respect to microscopic and macroscopic fat, and hence it was better. Chaudhari et al, 2022,^[10] discussed in his case report that CT abdomen is the primary investigation to assess the location and potential spread of the lesion. He also carried out pre-operative CT guided biopsy of the mass in his case report which was suggestive of spindle cell neoplasm similar to our study. Nigri G et al, 201,^[12] Syllaios A et al, 2018,^[5] and Kam JC et al, 2013,^[13] stated that CT scan is the investigation of choice for diagnosis of GCD.

The management of retroperitoneal liposarcoma complicated with a giant colonic diverticulum depends on various factors, including tumor size, location, histological subtype, presence of metastasis, and patient comorbidities. In most cases, surgical resection remains the cornerstone of treatment for both retroperitoneal liposarcoma and colonic diverticular disease as per Xiao J et al, 2021,^[8] Nureta TH et al, 2023,^[3] Patel SH et al, 2023,^[14] Nigri G et al, 201,^[12] Carr JA 2017,^[4] Frenken MR et al, 2022.^[7] Kam JC et al, 2013,^[13] and Syllaios A et al, 2018.^[5]

In our case we also found sigmoid volvulus and additional diverticuli of the colon. Similarly Carr JA 2017,^[4] stated that sigmoid volvulus occurs due to GCD. Also additional diverticuli found along the same segment of colon in 71 to 85% of cases which was also reported in his case report.

In our case the resected specimen was sent for the histopathological examination which was suggestive of dedifferentiated retroperitoneal liposarcoma. Post-surgery pathological results serve as the gold standard for subtype differentiation, enabling the prediction of prognosis as per Xiao J et al, 2021,^[8] and Nureta TH et al, 2023.^[3]

Dedifferentiated liposarcoma is a distinct histopathological subtype characterized by the presence of a well-differentiated liposarcoma component juxtaposed with a non-lipogenic sarcoma component. This histological variant is associated

with aggressive behavior, increased risk of local recurrence, and distant metastasis compared to other subtypes of liposarcoma as per Sharma R et al 2019,^[9] Chaudhari et al, 2022,^[10] and Verras GI et al, 2021.^[11] Assessment of histological subtype, tumor size and tumor grade are important to evaluate the risk of future relapses because adverse outcomes due to recurrence account for 70% mortality in cases of retroperitoneal liposarcoma as per Verras GI et al, 2021.^[11]

Neoadjuvant and adjuvant therapies such as chemotherapy and radiation therapy may be considered in cases of dedifferentiated liposarcoma to target residual disease and reduce the risk of recurrence as per Sharma R et al 2019.^[9]

Interdisciplinary collaboration among surgical, radiological, and oncological specialties is crucial for developing individualized treatment plans tailored to the patient's specific needs and disease characteristics. Regular follow-up and surveillance are essential to monitor for disease recurrence, progression, or potential complications postoperatively.

CONCLUSION

This case highlights the importance of considering retroperitoneal sarcomas in the differential diagnosis of abdominal pain, especially in elderly patients with comorbidities. Retroperitoneal liposarcoma complicated with a giant colonic diverticulum underscores the importance of considering rare and unexpected complications in the differential diagnosis of abdominal masses and gastrointestinal symptoms. Clinicians should maintain a broad differential diagnosis and utilize appropriate imaging modalities to accurately diagnose and manage such complex cases.

Informed Consent: Written informed consent was obtained from patient who participated in this case.

Conflict Of Interest: No conflict of interest was declared by the authors

Financial Disclosure: The authors declared that this study has received no financial support.

REFERENCES

1. Vijay A, Ram L. Retroperitoneal liposarcoma: a comprehensive review. *American journal of clinical oncology*. 2015 Apr 1; 38(2):213-9.
2. Tripathi M, Pavithira GJ, Dubey S, Verma R, Garg V. Surgical excision of a giant retroperitoneal liposarcoma with renal cell carcinoma: a case report of the largest retroperitoneal sarcoma. *International Journal of Surgery Case Reports*. 2023 Aug 1; 109:108515.
3. Nureta TH, Shale WT, Belete TD. Giant retroperitoneal well differentiated liposarcoma: a case report and literature review. *International Journal of Surgery Case Reports*. 2023 Sep 1; 110:108679.
4. Carr JA. Case report of a giant colonic sigmoid diverticulum causing sigmoid volvulus. *International journal of surgery case reports*. 2017 Jan 1; 31:197-9.
5. Syllaios A, Daskalopoulou D, Bourganos N, Papakonstantinou A, Triantafyllou E, Koutras A, Georgiou C. Giant colonic diverticulum—a rare cause of acute

- abdomen. *Journal of Surgical Case Reports*. 2018 Feb; 2018(2):rjy009.
6. Locatelli A, Caputo P, Carzaniga P. Giant colonic diverticulum: review of the literature, personal experience and proposal of decision making. *Chirurgia*. 2019 Feb; 32(1):25-9.
 7. Frenken MR, Koenjer LM, Versteegen MG, Vogelaar JF. Giant Colonic Diverticulum of the Sigmoid with an Unusual Localization. *Case Reports in Acute Medicine*. 2022 May 2; 5(1):1-5.
 8. Xiao J, Liu J, Chen M, Liu W, He X. Diagnosis and prognosis of retroperitoneal liposarcoma: a single Asian center cohort of 57 cases. *Journal of oncology*. 2021 Apr 1; 2021.
 9. Sharma R, Sharma M, Bansal S, Singh K, Singh NR. A Huge Retroperitoneal Liposarcoma: A Case Report. *AMEI's Current Trends in Diagnosis & Treatment*. 2020 Sep 16; 3(2):90-2.
 10. Chaudhari S, Patel B, Patel J, Chaudhary S. A case report on large retroperitoneal liposarcoma. *International Surgery Journal*. 2022 Jul 26; 9(8):1483-5.
 11. Verras GI, Mulita F, Bouchagier K, Bousis D, Kehagias D, Liolis E, Perdikaris I, Filis D, Perdikaris P, Panagiotopoulos I, Maroulis I. Mid-term outcomes in the treatment of retroperitoneal sarcomas: a 12-year single-institution experience. *Medicinski Glasnik*. 2022 Aug 1; 19(2).
 12. Nigri G, Petrucciani N, Giannini G, Aurello P, Magistri P, Gasparrini M, Ramacciato G. Giant colonic diverticulum: clinical presentation, diagnosis and treatment: systematic review of 166 cases. *World Journal of Gastroenterology: WJG*. 2015 Jan 1; 21(1):360.
 13. Kam JC, Doraiswamy V, Spira RS. A rare case presentation of a perforated giant sigmoid diverticulum. *Case Reports in Medicine*. 2013 Jan 1; 2013.
 14. Patel SH, Patel AN, Malek TN, Kuswaha MR. A case presentation on rare case of retroperitoneal liposarcoma. *International Surgery Journal*. 2023 Sep 28; 10(10):1693-7.