

# Bilateral renal artery stenosis and pheochromocytoma an uncommon association: A case report

## Abstract

Pheochromocytoma and bilateral renal artery stenosis have a quite rare association. Although unilateral renal artery stenosis is reported in the literature with Pheochromocytoma but bilateral renal artery stenosis never reported before in Gulf region. A 56-years-old woman primarily referred to our facility for CABG for triple vessel disease but uncontrolled blood pressure and long standing history of hypertension rendered her for further investigations for secondary causes. The technical imaging techniques (USG, abdominal CT, magnetic resonance angiogram (MRA) revealed bilateral renal artery stenosis and left supra-adrenal mass. Further hormonal assays confirmed high catecholamine and raised rennin and aldosterone secondary to Pheochromocytoma and bilateral renal artery stenosis. Laparoscopic removal of Pheochromocytoma with minimum invasive reconstructive surgery for bilateral renal artery stenosis was planned prior to CABG for triple vessel disease but patient declined any surgery or interventional and opted for conservative management inspite of repeated counselling sessions with the patient. Although these conditions co-existed simultaneously but differ in management.

**Key words:** Hypertension, pheochromocytoma, renal artery stenosis

## INTRODUCTION

A pheochromocytoma is a rare, catecholamine-secreting tumor that may precipitate life-threatening hypertension. The tumor is malignant in 10% of cases but may be cured completely by surgical removal.<sup>[1]</sup> The diagnosis can be established by measuring catecholamines and metanephrines in plasma (blood) or through a 24-hour urine collection. Care should be taken to rule out other causes of adrenergic (adrenalin-like) excess like hypoglycemia, stress, exercise, and drugs affecting the catecholamines like stimulants, methyl dopa, dopamine agonists, or ganglion blocking antihypertensives. Various foodstuffs (e.g., coffee, tea, bananas, chocolate, cocoa, citrus fruits, and vanilla) can also affect the levels of urinary metanephrines and VMA (vanillylmandelic acid).<sup>[2]</sup> Imaging by computed tomography or a T2 weighted MRI of the head, neck, and chest, and abdomen can help localize the tumor. Tumors can also be located using an MIBG scan, which is scintigraphy using iodine-123-marked metaiodobenzylguanidine. Even finer localization can be obtained in certain PET scan centers using PET/CT with F-18-fluorodopamine (FDOPA).<sup>[3]</sup> Pheochromocytomas occur most often during young-adult to mid-adult life. These tumors can form a pattern with other endocrine gland cancers which is labeled multiple endocrine neoplasia (MEN). Pheochromocytoma may occur in patients with MEN 2 and MEN 3 (MEN 2B). Von Hippel Lindau patients may also develop these tumors.<sup>[4]</sup>

Renal artery stenosis (RAS) is the major cause of renovascular hypertension and that it may account for 1-10% of the 50 million people in the United States who have hypertension. Apart from its role in the pathogenesis of hypertension, renal artery stenosis is also being increasingly recognized as an important cause of chronic renal insufficiency and end-stage renal disease. In older individuals, atherosclerosis (ATH) is by far the most common etiology of renal artery stenosis.<sup>[5,6]</sup> The gold standard investigation to diagnose renal artery stenosis is digital subtraction angiography.<sup>[7]</sup> Van Way *et al.*, proposed that these two causes of surgically correctable hypertension may be associated through a common pathophysiological mechanism mediated by catecholamine secretion.<sup>[8]</sup> I have reviewed

## Muhammad Sohail Anjum

Department of Medicine and  
Endocrinology, King Abdullah  
Medical City, Makkah,  
Saudi Arabia

### Address for the Correspondence:

Dr. Muhammad Sohail Anjum,  
Department of Medicine and  
Endocrinology, King Abdullah  
Medical City, P.O. Box 57657,  
Makkah - 21955, Saudi Arabia  
E-mail: friendsohail712@gmail.com

### Access this article online

Website: [www.ijmedph.org](http://www.ijmedph.org)

DOI: 10.4103/2230-8598.144136

Quick response code:



the literature to find a relationship between these two etiologies as a cause of hypertension. To the best of my knowledge, bilateral renal artery stenosis and pheochromocytoma with background history of bronchial asthma, hypothyroidism and triple vessel disease never reported before in Gulf region.

## CASE REPORT

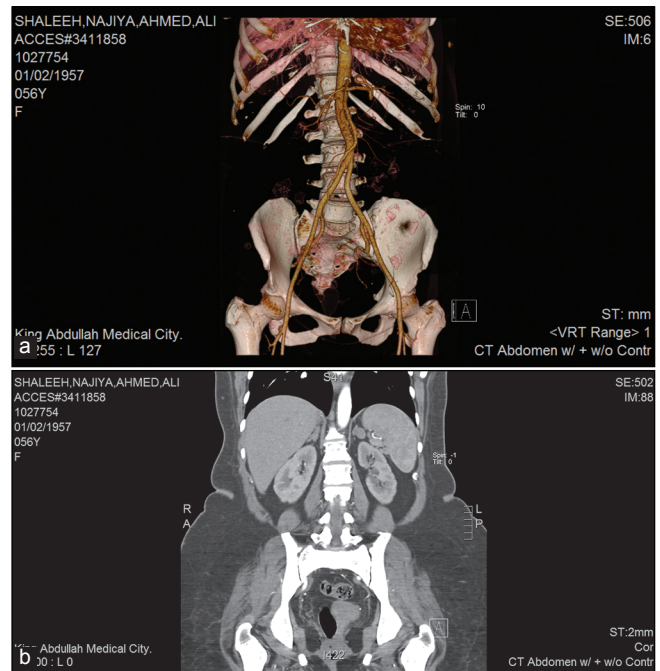
A 56-year-old Saudi female referred from Al-Noor hospital to our hospital (King Abdullah Medical City, Makkah, Saudi Arabia) for CABG for triple vessel disease. She gave a history of headache, sweating, anxiety, dizziness, nausea, palpitation and severe hypertension. She has a history of bronchial asthma, hypothyroidism, diabetes mellitus and labeled as resistant essential hypertension since 25 years. Her work up for secondary hypertension was planned inspite of four different antihypertensive groups, her blood pressure was uncontrolled and secondly, she has hypertension at quite young age. Doppler ultrasound of renal arteries suggested bilateral renal artery stenosis which confirmed by MRA of renal arteries. MRI abdomen revealed left supra-adrenal mass about 2 cm [Figure 1a and b]. Work up for Cushing, Conn's and Pheochromocytoma was done which revealed raised catecholamines in the serum, raised plasma renin and mild raised serum and urinary cortisol. Low dose dexamethasone test suppressed the serum cortisol making it pseudo-cushingoids due to obesity.

Bilateral renal reconstructing surgery with laparoscopic adrenalectomy planned prior to CABG but patient declined the idea for surgery or minimum invasive procedure due to pre-operative high risk assessment and adopted conservative management for her condition.

## DISCUSSION

Pheochromocytomas have been described to be associated with rare vascular abnormalities, most common of them being renal artery stenosis.<sup>[9]</sup> Surgical resection of the tumor is the treatment of choice and usually cures the hypertension. Careful preoperative treatment with alpha and beta blockers is required to control blood pressure and prevent intraoperative hypertensive crises.<sup>[10]</sup> However, even Pheochromocytoma without renal artery stenosis can be accompanied by elevated plasma renin activity that may be induced by direct stimulator effect of catecholamines on renin release and can lead to secondary hyperaldosteronism. Other factors contributing to hyperreninemia are decreased plasma volume, salt restriction and diuretic usage for control of hypertension.<sup>[11]</sup>

Surgical resection of the tumor is either by open laparotomy or else laparoscopy.<sup>[12]</sup> Given the complexity of perioperative management, and the potential for catastrophic intra and postoperative complications, such surgery should be performed only at centers experienced in the management of this disorder. In addition to the surgical expertise that such centers can provide, they will also have the necessary endocrine and anesthesia resources. It may also be



**Figures 1a and b:** CT angiography of the renal arteries revealed Short segment of narrowing is seen at the origin of both renal arteries more prominent on the left side. Diffuse atherosclerotic changes are seen involving the abdominal aorta. The remaining of the scanned vessels are patent. Small well-defined lesion is seen involving the left supra-renal gland. It measured about  $2 \times 1.5 \text{ cm}^2$

necessary to carry out adrenalectomy, a complete surgical removal of the affected adrenal gland(s). Either surgical option requires prior treatment with the non-specific and irreversible alpha adrenoceptor blocker Phenoxybenzamine or a short acting alpha antagonist (e.g., prazosin, terazosin, or doxazosin).<sup>[13]</sup>

High catecholamine level can cause direct myocardial damage with focal degeneration and contraction band necrosis of the myocytes, monocytic infiltration, medial thickening of small and medium size coronary arteries and interstitial fibrosis. The clinical picture of catecholamine myocarditis is common in autopsies studies of patients died from pheochromocytoma as well as those died from the stress of physical assault.<sup>[14-16]</sup> Minimally invasive techniques are being increasingly used for resection of adrenal tumors and to treat renal artery lesions. Laparoscopic adrenalectomy is performed by either the transperitoneal or retroperitoneal approach.<sup>[17]</sup> Similarly, percutaneous balloon angioplasty has come to be the first line of treatment for the majority of cases of renal artery stenosis.<sup>[18]</sup>

A high index of suspicion is necessary to enable both entities to be diagnosed preoperatively and allow proper planning for surgical therapy. Incomplete diagnosis and subsequent treatment may lead to persistent hypertension post-operatively. So, I recommend careful and thorough work up for secondary hypertension with keeping a possibility of dual etiology in mind before proceeding to any final decision for any intervention.

## LIMITATIONS OF STUDY

Study is limited by lack of surgical intervention as patient refused for any surgical intervention. It is not clear whether bilateral renal artery stenosis is main contributor of her hypertension or recent incidental Pheochromocytoma was a hidden cause for years contributing towards her hypertension.

Secondly, comparison of biochemical, angiographic parameters, control of blood pressure after surgical intervention was possible as patient denied surgical intervention.

The main controversy arises from the study whether renal artery stenosis leading to secondary hypertension or it is itself a complication of advanced atherosclerosis as evident by tripple vessel coronary disease. As when she was diagnosed hypertensive in her second decade of her life but no renal ultrasound or radiological investigation is available since then.

Further research is required to establish the link between bilateral renal artery stenosis and Pheochromocytoma, a genetic propensity or just incidental proclivity.

## REFERENCES

1. Blake MA, Sweeney AT, Griffing GT. Pheochromocytoma. eMedicine. Available from: <http://emedicine.medscape.com/article/124059-overview#showall>. [Last accessed on 2013 Oct 12].
2. Young WF. Adrenal medulla, catecholamines, and pheochromocytoma. In: Goldman L, Ausiello D, editors. Cecil Medicine. 23<sup>rd</sup> ed. Philadelphia, Pa: Saunders Elsevier; 2007. Chap. 246.
3. Pacak K, Eisenhofer G, Carrasquillo JA, Chen CC, Li ST, Goldstein DS. 6-[18F]Fluorodopamine Positron Emission Tomographic (PET) scanning for diagnostic localization of pheochromocytoma. Hypertension 2001;38:6-8.
4. Modigliani E, Vasen HM, Raue K, Dralle H, Frilling A, Gheri RG, *et al*. Pheochromocytoma in multiple endocrine neoplasia type 2: European study. The Euromen Study Group. J Intern Med 1995;238:363-7.
5. Chrysochou C, Kalra PA. Current management of atherosclerotic renovascular disease — What have we learned from ASTRAL? Nephron Clin Pract 2010;115:c73-81.
6. Plouin PF, Bax L. Diagnosis and treatment of renal artery stenosis. Nat Rev Nephrol 2010;6:151-9.
7. Sarkodieh JE, Walden SH, Low D. Imaging and management of atherosclerotic renal artery stenosis. Clin Radiol 2013;68:627-35.
8. van Way CW 3rd, Michelakis AM, Alper BJ, Hutcheson JK, Rhamy RK, Scott HW Jr. Renal vein renin studies in a patient with renal hilar pheochromocytoma and renal artery stenosis. Ann Surg 1970;172:212-7.
9. Kota SK, Kota SK, Meher LK, Jammula S, Tripathy PR, Panda S, *et al*. Coexistence of pheochromocytoma with uncommon vascular lesions. Indian J Endocrinol Metab 2012;16:962-71.
10. Elenkova A, Matrozoza J, Zacharieva S, Kirilov G, Kalinov K. Adiponectin — A possible factor in the pathogenesis of carbohydrate metabolism disturbances in patients with pheochromocytoma. Cytokine 2010;50:306-10.
11. Vetter H, Vetter W, Warnholz C, Bayer JM, Kaser H, Vielhaber K, *et al*. Renin and aldosterone secretion in pheochromocytoma. Am J Med 1971;60:866-71.
12. Jaroszewski DE, Tessier DJ, Schlinkert RT, Grant CS, Thompson GB, Van Heerden JA, *et al*. Laparoscopic Adrenalectomy for Pheochromocytoma. Mayo Clin Proc 2003;78:1501-4.
13. Pacack K. Preoperative management of the pheochromocytoma patient. J Clin Endocrinol Metab 2007;92: 4069-79.
14. Sardesai SH, Mourant AJ, Sivathandon Y, Farrow R, Gibbons DO. Phaeochromocytoma and catecholamine induced cardiomyopathy presenting as heart failure. Br Heart J 1990;63:234-7.
15. Cebelin MS, Hirsch CS. Human stress cardiomyopathy: Myocardial lesions in victims of homicidal assaults without internal injuries. Hum Pathol 1980;11:123-32.
16. Lyon AL, Rees PS, Prasad S, Poole-Wilson PA, Harding SE. Stress (Takotsubo) cardiomyopathy — A novel pathophysiological hypothesis to explain catecholamine-induced acute myocardial stunning. Nat Clin Pract Cardiovasc Med 2008;5:22-9.
17. del Pizzo JJ, Schiff JD, Vaughan ED. Laparoscopic adrenalectomy for pheochromocytoma. Curr Urol Rep 2005;6:78-85.
18. Paulsen D, Klow NE, Rogstad B, Leivestad T, Lien B, Vatne K, *et al*. Preservation of renal function by percutaneous transluminal angioplasty in ischemic renal disease. Nephrol Dial Transplant 1999;14:1454-61.

**How to cite this article:** Anjum MS. Bilateral renal artery stenosis and pheochromocytoma an uncommon association: A case report. Int J Med Public Health 2014;4:517-9.

**Source of Support:** Nil, **Conflict of Interest:** None declared.